



Gregor-Georg Zafiropoulos<sup>1\*</sup>, Evangelos Sotiropoulos<sup>2</sup>, Tae Ho Yoon<sup>3</sup> and Moosa Abuzayda<sup>3</sup>

<sup>1</sup>Private practice limited in Periodontology, Duesseldorf, Germany

<sup>2</sup>Senior Dental Technician, Dental Laboratory, College of Dental Medicine, MBRU, Dubai

<sup>3</sup>Associate Professor, Dept. of Prosthodontics, College of Dental Medicine, MBRU, Dubai

**Dates: Received:** 09 June, 2017; **Accepted:** 11 July, 2017; **Published:** 12 July, 2017

**\*Corresponding author:** Gregor-Georg Zafiropoulos, Luegallee 70, 40545 Duesseldorf, Germany, E-mail: ggzafi@gmx.de

**Keywords:** Dental implants; Dentures; Mounting guide; Implant prosthodontic

<https://www.peertechz.com>

Case Report

The use of a customized mounting guide for Implant-Prosthetic Restoration of the Fully Edentulous Arch

Abstract

Reconstruction of fully edentulous arches with implant-retained dentures requires thorough planning and precise registration of the interocclusal relationship, to achieve a successful treatment outcome. This technical report describes three representative approaches from a cohort of 89 fully edentulous arches in 69 patients who were treated with the described mounting guide technique. A technique of using a duplicated denture as a guide is described, which allows for the accurate transfer of the occlusal relationship and vertical dimensions, while facilitating the full-arch restoration process with implant-retained fixed or removable dentures and reducing the number of required in-office sessions.

Introduction

The reconstruction of the fully edentulous arch with implant-retained dentures requires thorough planning that it should provide the correct vertical height and the maxilla-mandibular relationship (MMR), while being esthetically acceptable [1,2]. This process of restoration would represent a major challenge for the clinicians [3].

The aim of this report was to describe an uncomplicated as well as accurate technique to obtain MMR transfer, occlusal relationship, and maintain (or keeping) initial esthetics. By this way, it enables the production of a full denture initially that can serve as a template for reconstruction of the final fixed or removable implant-retained full-arch restoration.

Cases

Between January 2001 and December 2014, a total of 89 fully edentulous arches (54 maxillae and 35 mandibles) of 69 patients (37 females and 32 males; mean age: 56.6 ± 9.2 years, age range: 38–75 years) were treated in the private office by one of the authors with the technique described herein (Figure 1). All patients who had been referred for multiple tooth extractions due to advanced periodontal disease and implant treatment were nonsmokers and in good general health. Three representative cases were selected for detailed presentation here. The surgical procedures are not described in the present report.

Diagnostic impressions for the fabrication of an interim

denture were taken with an alginate material (Alginat-rosa; Omnident, Rodgau, Germany). Interim dentures were fabricated, and were inserted on the day of extraction to

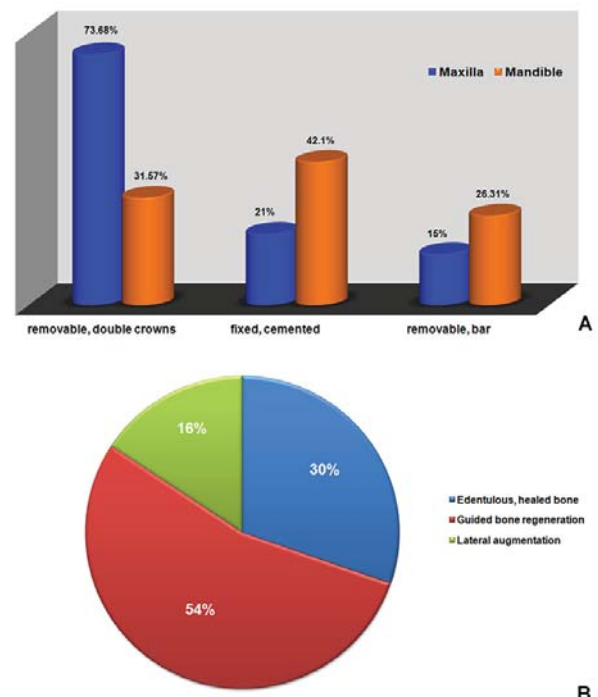


Figure 1: Characteristics (% distribution) of the 89 rehabilitated arches in 69 patients. 1A: %-Distribution of the prosthetic rehabilitation arts; 1B: %- Distribution of the used surgical procedures.

restore the esthetics and function. Implants were placed eleven (11) months after teeth extractions and bone regeneration or lateral augmentation in accordance with a two-stage protocol. Implants were uncovered and loaded four months later [4,5]. All definitive impressions for definitive casts fabrication were made using a polyether material (Impregum Penta Soft; 3M ESPE, Neuss, Germany) with an open-tray technique. Surgical techniques are not described in this report.

### Case 1 (Fixed case)

For the reconstruction and rehabilitation of the maxilla, six screw-cylinder and two provisional implants (for provisional denture stabilization) were placed (Figure 2). During the healing period, the patient's denture was adjusted to manage complications, and the function and esthetics of the denture was optimized by relining it as is needed (Figure 3A). After then, the adjusted denture was duplicated (DentDu) using clear resin (Paladur, Heraeus, Hanau, Germany) and fitted after implants' uncovering (Figure 3B).

System specific ball attachments (BATT) with their retention elements were mounted on selected three implants. Access windows were created on the buccal side of the DentDu in the areas of the BATT and the retention elements fixed to the DentDu using modeling resin (Pattern Resin; GC, Alsip, IL, USA). Occlusal records were taken in centric occlusion (Figure 3C). Definitive impression is taken and BATT were positioned on the implant analogs of the master cast. Subsequently, the DentDu was retained on the master cast and articulated under the guidance of the DentDu and occlusal records (Figure 3D). The framework of the final restoration (fixed denture, FD) was fabricated by milling CrCo alloy type 3 (ZENOTEC NP, Wieland). Additionally, a provisional FD (t-FD) from colored poly-methyl methacrylate (PMMA; Zenotec; Wieland, Pforzheim, Germany) was milled.

One week later, two temporary implants were removed and the abutments were mounted on the implants, torqued to 35 Ncm and were not removed thereafter to avoid introducing any inaccuracies. The framework was tried-in and another definitive impression was taken with the metal framework in place to fabrication of a new master cast. Meanwhile the t-FD was fixed on the abutments with temporary cement (TempBond; Kerr, CA, USA; Figure 4A). The metal framework was veneered with metal bond porcelain (Vintage MP; Shofu, San Marcos, CA, USA) and replaced t-FD that it was fixed on the abutments with provisional cement (ImpProv; Alvelogro Inc., Snoqualmie, WA, USA; Figure 4B).

### Case 2 (Double crowns, removable)

A removable denture using double crowns (telescopic crowns) was planned to restore the forms and esthetics in case of severe resorptions in the maxilla (horizontal atrophy = 1.4 cm; distance from the incisal edge of the mandibular anterior teeth to the edge of the maxillary alveolar ridge = 1.6 cm; Figure 5A). All clinical records and laboratory steps were performed as described for case 1. Additionally to the customized abutments, electroformed gold copings (AGCs; 0.25-mm-

thick, AGC Galvanogold; Wieland) [2,6-8], as well as a metal framework and a t-FD (as above described) were fabricated as above described. The customized abutments served as primary telescopes, and the AGCs as secondary telescopes (Figure 5 B-D).

The abutments were transferred, positioned on the implants, torqued to 35 Ncm using a resin transfer key (Pattern Resin, GC, Alsip, IL, USA), and were not removed this point forward, to avoid any possible inaccuracies. The AGCs were placed on the implant abutments and the framework was placed over the AGCs (Figure 6). A definitive impression with a polyether impression material was taken (Impregum Penta Soft; 3M ESPE, Neuss, Germany) with AGCs and framework in place and used for the fabrication of a new master cast. After the impression, the t-FD was fixed on the abutments using

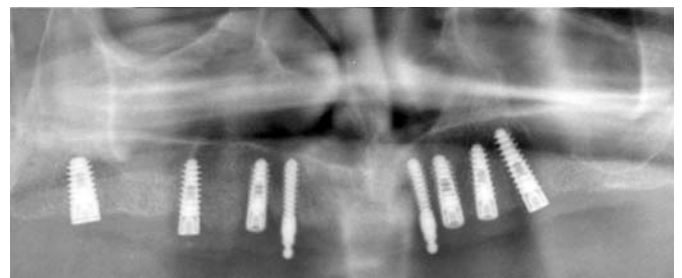

Figure 2: Case 1. Orthopantomograph after implant placement.

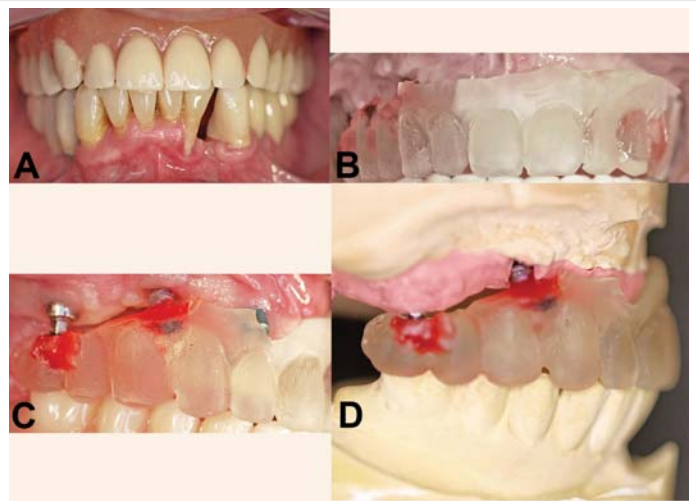


Figure 3: Case 1. A: interim denture in situ, B: fitting of the DentDu, C: DentDu retained on ball attachments in occlusion, D: Articulated master cast using the ball attachments and the DentDu.

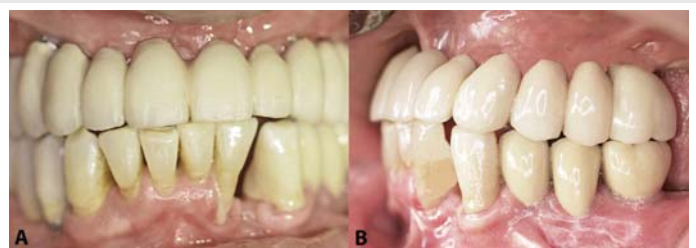

Figure 4: Case 1. A: Implant retained temporary restoration, B: Final restoration in situ - left view.

temporary cement (TempBond, Kerr, Orange, CA), and it was left in place until the delivery of the final restoration (Figure 7).

The new master cast was articulated with the help of the AGCs and of the framework. The veneering of the framework was made using a light-cured indirect ceramic polymer (Ceramage, Shofu, Menlo Park, CA). The AGCs were fixed in the framework using a self-curing compomer cement (AGC Cem, Wieland, Pforzheim, Germany) (Figure 8).

### Case 3 (Bar, retained removable)

The presented mandible had been treated with by a removable denture using two implants (#22 and 27) six years before and showed an advanced peri-implantitis. A bar-retained removable denture was planned, and it was mounted on four implants after surgery. All clinical and laboratory steps were performed as described above, except that gold copings were not used (Figure 9A). The bar was milled of CrCo alloy type 3 (ZENOTEC NP; Wieland) and a metal base housing was constructed (Figure 9B). Elastic plastic clips were used to retaining the base over the bar (Preci Matrice, CEKA, Waregem, Belgium; Figure 9C). During the next clinical session, the bar was definitively mounted on the implants and was not removed after anymore. The metal housing with wax rim was fitted in for occlusal record and esthetic try in later on. Subsequently, the denture was finished with an auto-polymerizing acrylic resin base (PalaXpress Ultra; Heraeus Kulzer, Hanau, Germany) and delivered to the patient same day (Figure 9D).

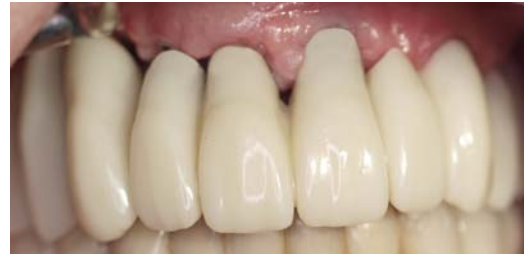

Figure 7: Case 2. Temporary restoration in situ.

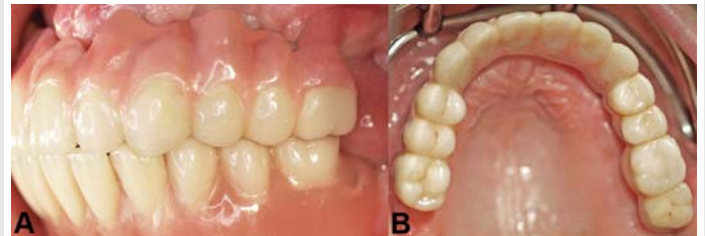

Figure 8: Case 2. A: Final restoration in situ. Right view, B: palatal view.

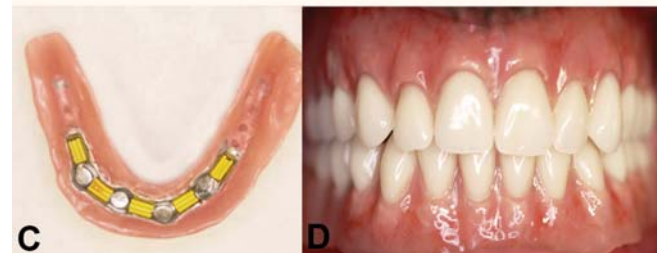
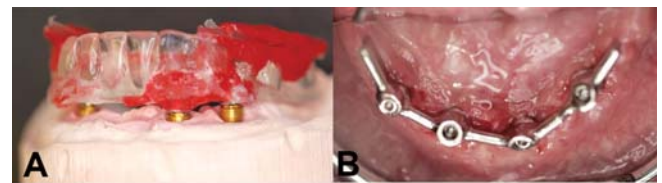


Figure 9: Case 3. A: articulation of the DentDu using ball attachments, B: bar in situ, C: denture in site: use of clips for retention on the bar, D: final restorations in situ.

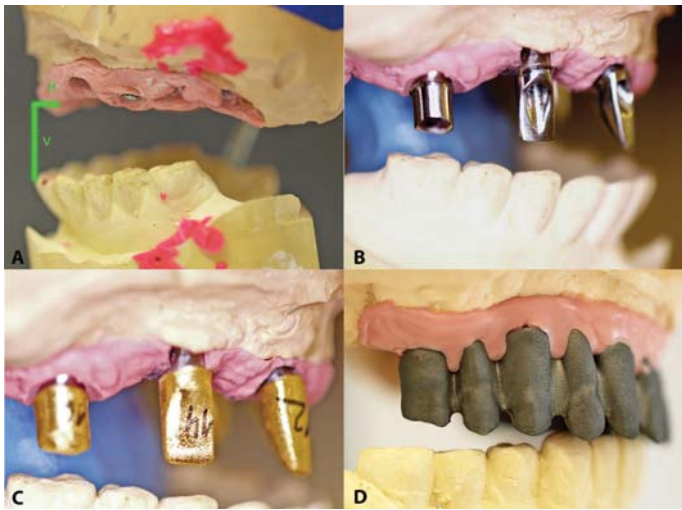


Figure 5: Case 2. A: Articulated master cast, B: customized abutments, C: AGCs, D: framework.

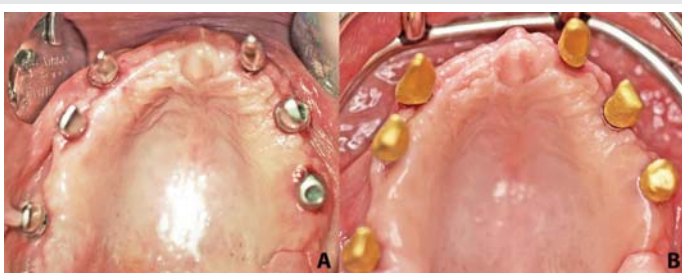

Figure 6: Case 2. A: mounted abutments, B: positioned AGCs.

## Discussion

The purpose of the present report was to describe a new and easy technique with reproducible results and not to compare different techniques. Three cases were presented to treat with different types of restorations. This method can be used for rehabilitation of one arch or both arches simultaneously.

The DentDu is an effective method to be used to obtain the occlusal records, to guide the mounting process, and to record and transfer the MMR. This technique allows faster process by reducing (or eliminating) certain clinical steps. It is recommended that the DentDu be produced at the end of the healing period after all denture adjustments and its improvements have been made.

Three to four BATT are necessary to attain optimal stabilization of the DentDu without any wobble. Placing open windows on the buccal side of the DentDu not only provides good access, but also allows visual checking during treatment.

Abutments were mounted on the implants only once, thereby avoiding possible position changes [9].

For case 1 and 2, t-FDs were fabricated after implant uncovering. The temporary fixed restorations (t-FDs) are used in order to: 1) load implants progressively in order to achieve a better bone remodeling [10,11], 2) check and evaluate the form and function of the final FDs before the veneering of the framework, and 3) replace the interim removable dentures. Mounted abutments were maintained in position so that the removable interim denture could not be relined. A further advantage of this CAD/CAM made t-FD is the possible long term use in case the final restoration has to be postponed.

In cases 2 and 3, the patients declined to have augmentative surgery. For this reason, the arches were restored with removable dentures [2]. The technique produced acceptable esthetic outcomes, without the conventional need to repeat clinical recordings at the time of final restoration fabrication. Disadvantages of this technique include the need for well-developed dental laboratory skills and the performance of a two-stage surgical protocol.

## References

1. Ghazal M, Albashaireh ZS, Kern M (2008) The ability of different materials to reproduce accurate records of interocclusal relationships in the vertical dimension. *J Oral Rehabil* 35: 816-820. [Link: https://goo.gl/2p1mT3](https://goo.gl/2p1mT3)
2. Zafiroopoulos GG, Hoffmann O (2011) Implant-retained dentures for full-arch rehabilitation. A case report comparing fixed and removable restorations. *Gen Dent* e137-e143. [Link: https://goo.gl/UaVbWa](https://goo.gl/UaVbWa)
3. Krennmair G, Krainhofner M, Waldenberger O, Piehslinger E (2007) Dental implants as strategic supplementary abutments for implant-tooth-supported telescopic crown-retained maxillary dentures: A retrospective follow-up study for up to 9 years. *Int J Prosthodont* 20: 617-622. [Link: https://goo.gl/TBxH5w](https://goo.gl/TBxH5w)
4. Hoffmann O, Bartee BK, Beaumont Chr, Kasaj A, Deli G, et al. (2008) Alveolar bone preservation in extraction sockets using non-resorbable high-density polytetrafluoroethylene (dPTFE) membranes. A retrospective non-randomized study. *J Periodontol* 79: 1355-1369. [Link: https://goo.gl/PUH1Dx](https://goo.gl/PUH1Dx)
5. Bartee BK (2001) Extraction site grafting for alveolar ridge preservation. Part 2: membrane-assisted surgical technique. *J Oral Implantol* 27: 194-197. [Link: https://goo.gl/bZ68ij](https://goo.gl/bZ68ij)
6. Behrend F (1997) Gold electroforming system: GES restorations. *J Dent Technol* 14: 31-37. [Link: https://goo.gl/dkGJuN](https://goo.gl/dkGJuN)
7. Biewer ZP (1999) Development of the G.E.S. electroforming technique: biocompatible, corrosion-free production of telescopic crowns. *J Dent Technol* 16: 24-29. [Link: https://goo.gl/wjzd91](https://goo.gl/wjzd91)
8. Grossmann AC, Hassel AJ, Schilling O, Lehmann F, Koob A, et al. (2007) Treatment with double crown-retained removable partial dentures and oral health-related quality of life in middle- and high-aged patients. *Int J Prosthodont* 20: 576-578. [Link: https://goo.gl/Ymu5Jv](https://goo.gl/Ymu5Jv)
9. Semper-Hogg W, Kraft S, Stiller S, Mehrhof J, Nelson K (2013) Analytical and experimental position stability of the abutment in different dental implant systems with a conical implant-abutment connection. *Clin Oral Invest* 17: 1017-1023. [Link: https://goo.gl/944N1f](https://goo.gl/944N1f)
10. Zafiroopoulos GG, Deli G, Bartee BK, Hoffmann O (2010) Single-tooth implant placement and loading in fresh and regenerated extraction sockets. Five-year results: a case series using two different implant designs. *J Periodontol* 81: 604-615. [Link: https://goo.gl/U7GeSp](https://goo.gl/U7GeSp)
11. Turner PS, Nentwig GH (2014) Evaluation of the value of bone training (progressive bone loading) by using the Periotest: A clinical study. *Contemp Clin Dent* 5: 461-465. [Link: https://goo.gl/Drm1a4](https://goo.gl/Drm1a4)