

## Vishwanath Hesarur\*

Assistant Professor, Department of Cardiology, KLE University's Jawaharlal Nehru Medical College, KLES Dr Prabhakar Kore Hospital and Medical Research Centre, Belagavi, Karnataka, India

**Dates:** Received: 20 October, 2017; Accepted: 31 October, 2017; Published: 01 November, 2017

**\*Corresponding author:** Vishwanath Hesarur, Assistant Professor, Department of Cardiology, KLE University's Jawaharlal Nehru Medical College, KLES Dr Prabhakar Kore Hospital and Medical Research Centre, Belagavi, Karnataka, India, Tel. No: +919480008361; Email: drvishwanathesarur@yahoo.com

**Keywords:** Budd-chiari syndrome (BCS); Percutaneous transluminal balloon angioplasty (PTBA); Inferior vena cava (IVC); Balloon dilatation; Jaundice; Portal Hypertension

<https://www.peertechz.com>

## Case Report

# Successful treatment of Budd-Chiari Syndrome with Percutaneous transluminal Balloon Angioplasty

## Abstract

**Introduction:** Budd-Chiari syndrome (BCS) is a relatively rare disease in which an obstruction of hepatic venous outflow causes intrahepatic venous congestion and portal hypertension. Surgical treatment is associated with high morbidity and mortality. Recently, percutaneous transluminal angioplasty (PTA) has been applied to patients with BCS and it has shown a favorable outcome.

**Case Report:** Here we report a case of 50 year old male patient presented with history of insidious onset of abdominal distension and swelling of lower limbs since last six months and yellowish discoloration of eyes since two weeks. He was diagnosed as a case of BCS.

**Treatment:** Patient underwent successful percutaneous transluminal balloon angioplasty (PTBA). His symptoms significantly improved with patency of IVC at 6 months of follow-up.

**Conclusion:** PTA is an effective treatment for BCS caused by short-length obstruction of the hepatic portion of the IVC or hepatic veins. However, considering the occurrence of restenosis, regular clinical and ultrasound assessments are necessary after angioplasty.

## Introduction

Budd-Chiari syndrome (BCS) is a relatively rare disease in which an obstruction of hepatic venous outflow causes intrahepatic venous congestion and portal hypertension. This obstruction of hepatic venous flow can occur at any level, from the small hepatic veins to the junction of the right atrium and inferior vena cava (IVC). Surgical treatment is associated with high morbidity and mortality. Recently, percutaneous transluminal angioplasty (PTA) has been applied to patients with BCS and it has shown a favorable outcome [1-8]. Here we report a case of 50 year old male patient with BCS whom we successfully treated with percutaneous transluminal balloon angioplasty (PTBA).

## Case Report

A 50 year old male patient presented with history of insidious onset of abdominal distension, and swelling of lower limbs since last six months and yellowish discoloration of eyes since two weeks. There was no previous history of jaundice, fever, drug ingestion or abdominal trauma.

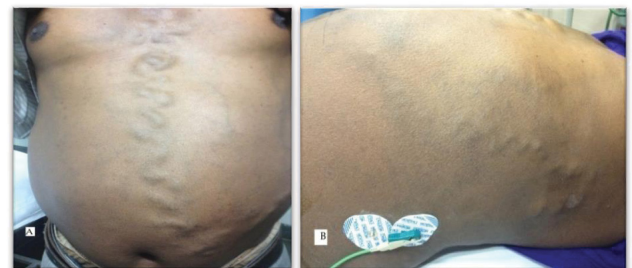## On Examination

BP 110/70 mmHg. No signs of anemia and jaundice. Abdomen

was distended with dilated subcutaneous veins (Figure 1) on the abdominal wall and bilateral pitting pedal edema. Per-abdominal examination revealed non tender hepatomegaly, splenomegaly and ascites.

## Investigations

His hematological parameters, renal, liver and thyroid function tests were within normal limits. Viral markers (hepatitis A, B, C & E) were negative. Ultrasound abdomen showed complete obstruction of inferior vena cava (IVC). Upper GI endoscopy revealed esophageal varices. Contrast enhanced



**Figure 1:** Photograph showing distended abdomen with prominent abdominal veins.

computed tomography (CT) revealed complete obstruction of hepatic portion of IVC (Figure 2).

An IVC venogram from both the distal and proximal sides of the obstruction showed a short, complete obstruction of hepatic portion of IVC (Figure 3). Length of obstruction was approximately 18 to 20 mm.

### Procedure

The procedure was performed under local anaesthesia. The right femoral vein and right internal jugular vein were accessed percutaneously with 8 F and 7 F introducer sheaths, respectively. Intravenous heparin 100 IU/kg and antibiotic were given. An IVC venogram was performed both distal and proximal to obstruction.

An 8 F mullins introducer set was advanced over a 0.032 × 145 cm j tip guide wire in to IVC up to the level of obstruction (Figure 4A). The guide wire was exchanged for straight tipped brokenbrough needle (Figure 4B). The needle was pushed slowly and carefully until the tip penetrated the obstruction part and was advanced to above the caval entrance in to the right atrium (Figure 4C). Now the mullins introducer set was advanced over the needle in to the right atrium and the needle was exchanged with amplatz superstiff 0.035 × 260 cm j tip guide wire which was positioned in superior vena cava (SVC) (Figure 4D). Then mullins introducer set removed and the obstruction was dilated using TYSHAK II balloon 12 × 40 mm and TYSHAK II balloon 16 × 60 mm (Figure 4E). An IVC venogram immediately after balloon dilatation angioplasty showed restoration of IVC patency (Figure 4D). The patient was discharged on oral anticoagulation and Aspirin 75mg OD.

### Follow-up

Patient was followed up at 6 months and one year. His symptoms dramatically reduced. Prominent abdominal veins disappeared (Figure 5), Ultrasound abdomen showed marked reduction in liver and spleen size and ascites. Upper GI endoscopy revealed disappearance of esophageal varices. An

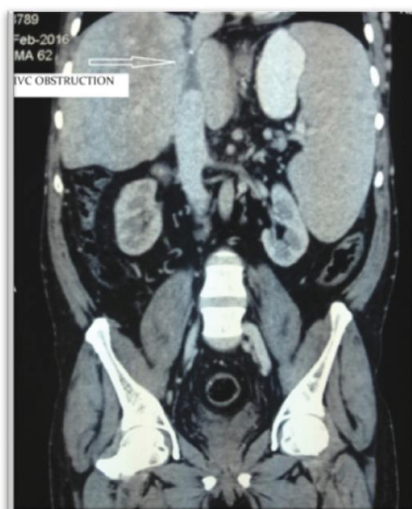

Figure 2: Contrast enhanced CT showing complete obstruction of hepatic portion of IVC.

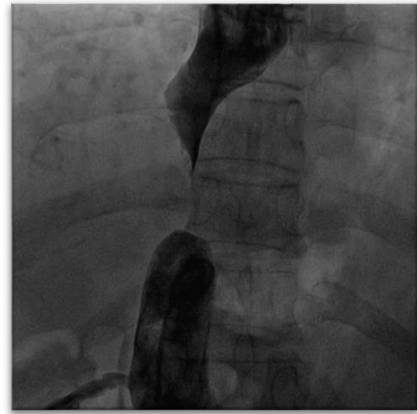

Figure 3: IVC Venogram showing complete obstruction of hepatic portion of IVC.

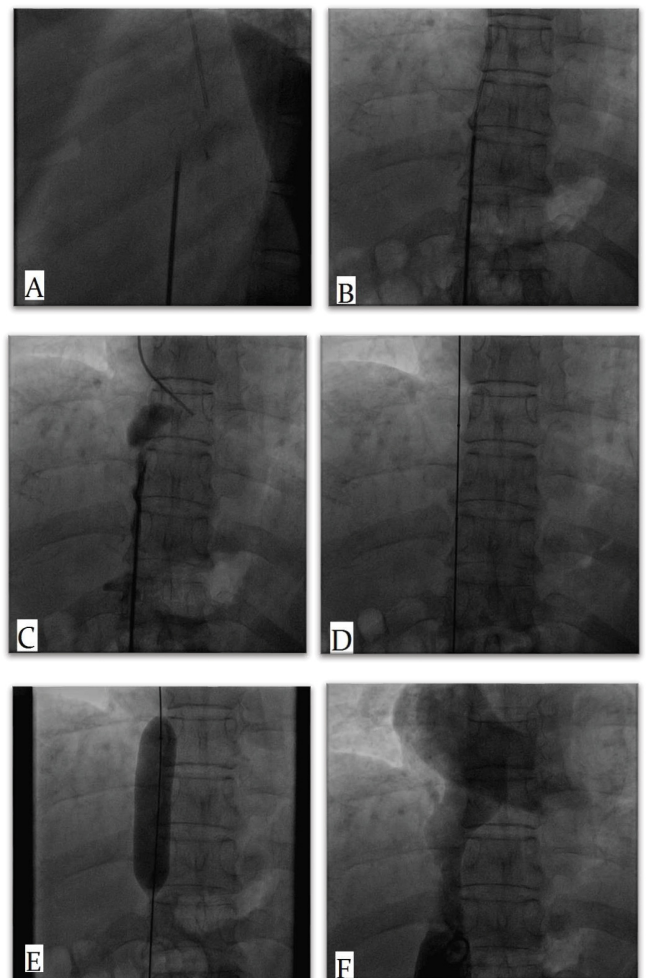
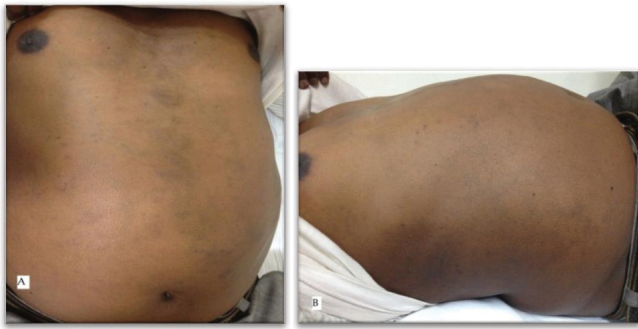


Figure 4: (A) Mullins introducer set, (B) Straight tipped brokenbrough needle, (C) Tip penetrated the obstruction, (D) Needle was exchanged with amplatz superstiff wire, (E) Balloon dilatation and (F) Restoration of IVC patency.

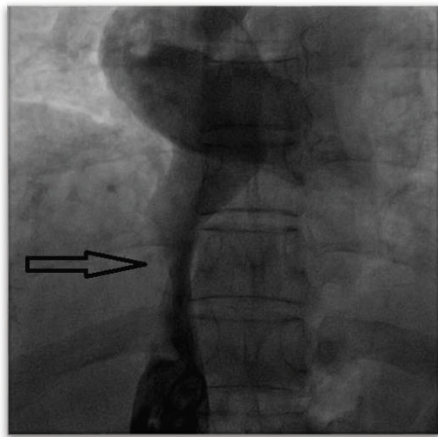
IVC venogram done at 6 months showed patency of the IVC (Figure 6).

### Discussion

Budd-Chiari syndrome (BCS) is a relatively rare disease in which an obstruction of hepatic venous outflow causes intrahepatic venous congestion and portal hypertension. It can



**Figure 5:** Photograph showing disappearance of dilated subcutaneous abdominal veins following PTBA.



**Figure 6:** IVC Venogram showing IVC patency at 6 months.

be primary or secondary depending on its pathologic features. The primary type is due to congenital obstruction of the hepatic veins or the hepatic portion of the IVC. The secondary type is due to obstruction of the same anatomic structures by a tumor or, more commonly, thrombus or thrombi in patients with some systemic diseases, usually myeloproliferative disorders [9].

The main goals of treatment of BCS are relief of symptoms of portal hypertension and intrahepatic venous congestion. Treatment options are either Interventional therapy or surgery. These include transjugular intrahepatic portosystemic shunts (TIPS), balloon dilatation angioplasty, and liver transplantation [10–12]. Selection of the treatment option depends on the aetiology of BCS, the location and length of the obstruction and the physical status of the patient [11].

In our patient, a short segmental obstruction was located within the IVC. Because of this finding, we decided to do balloon dilatation angioplasty. Generally, if the obstruction is short and located in the major trunk of the hepatic vein or IVC, balloon dilatation angioplasty should be considered as the first choice of treatment because it is a minimally invasive procedure [13]. A surgical shunt procedure or TIPS should be considered when balloon dilatation angioplasty is unsuccessful or clearly fails to resolve symptoms. Liver transplantation is reserved for those presenting with fulminant liver failure or end-stage chronic liver disease.

Although the risk of PTBA is low and there is a high incidence of restenosis after successful treatment [12]. It has been reported that an absence of anticoagulants after successful PTBA may cause restenosis [14]. Therefore, the use of anticoagulant drugs and periodical surveillance of blood flow in the IVC and hepatic vein by Doppler ultrasound, are mandatory for the management of patients after successful PTBA [12]. If restenosis occurs in spite of anticoagulant therapy, placement of a stent after a second balloon dilatation is recommended [13]. Other indications for stent placement are long segment obstruction of IVC and hepatocellular carcinoma or abdominal tumor that may compress on the IVC.

## Conclusion

PTA is an effective treatment for BCS caused by short-length hepatic vein obstruction. However, considering the occurrence of restenosis, regular clinical and ultrasound assessments are necessary after angioplasty.

## References

1. Fisher NC, McCafferty I, Dolapci M, Wali M, Buckels JA, et al. (1999) Managing Budd-chiari syndrome: a retrospective review of percutaneous hepatic vein angioplasty and surgical shunting. *Gut* 44: 568–574. [Link: https://goo.gl/GWa8gu](https://goo.gl/GWa8gu)
2. Murphy FB, Steinberg HV, Shires GTIII, Martin LG, Bernardino ME (1986) The Budd-Chiari syndrome: a review. *Am J Roentgenol* 147: 9–15. [Link: https://goo.gl/ySTMFx](https://goo.gl/ySTMFx)
3. Sparano J, Chang J, Trasi S, Bonanno C (1987) Treatment of the Budd-Chiari syndrome with percutaneous transluminal angioplasty. Case report and review of the literature. *Am J Med* 82: 821–828. [Link: https://goo.gl/NHmDst](https://goo.gl/NHmDst)
4. Martin LG, Henderson JM, Millikan WJ Jr, Casarella WJ, Kaufman SL (1990) Angioplasty for long-term treatment of patients with Budd-Chiari syndrome. *AJR Am J Roentgenol* 154: 1007–1010. [Link: https://goo.gl/XNm5wH](https://goo.gl/XNm5wH)
5. Griffith JF, Mahmoud AEA, Cooper S, Elias E, West RJ, et al. (1996) Radiological intervention in Budd-Chiari syndrome: techniques and outcome in 18 patients. *Clin Radiol* 51: 775–784. [Link: https://goo.gl/qDZbu7](https://goo.gl/qDZbu7)
6. Cooper S, Olliff SP, Elias E (1996) Recanalisation of hepatic veins by a combined transhepatic and transjugular approach in 3 cases of Budd-Chiari syndrome. *J Intervent Radiol* 11: 9–13.
7. Mahmoud AEA, Mendoza A, Meshikhes AN, Olliff S, West R, et al. (1996) Clinical spectrum, investigations and treatment of Budd-Chiari Syndrome. *QJM* 89: 37–43. [Link: https://goo.gl/d8e5AQ](https://goo.gl/d8e5AQ)
8. Xu K, He FX, Zhang HG, Zhang XT, Wang CR, et al. (1996) Budd-Chiari syndrome caused by obstruction of the hepatic inferior vena cava: immediate and 2-year treatment results of transluminal angioplasty and metallic stent placement. *Cardiovasc Intervent Radiol* 19: 32–36. [Link: https://goo.gl/atjiiHj](https://goo.gl/atjiiHj)
9. Mahmoud AEA, Wilde JT, Elias E (1995) Budd-Chiari syndrome and factor V Leiden mutation [letter]. *Lancet* 345: 526.
10. Panagiotou I, Kelekis DA, Karatza C, Nikolaou V, Mouyia V, et al. (2007) Treatment of Budd-Chiari syndrome by transjugular intrahepatic portosystemic shunt. *Hepatogastroenterology* 54: 1813-1816. [Link: https://goo.gl/qysFqf](https://goo.gl/qysFqf)
11. Poddar P, Gurizala S, Rao S (2014) Endovascular stenting of IVC using Brockenborough's needle in Budd-Chiari syndrome-a case report. *Indian Heart J* 66: 363-365. [Link: https://goo.gl/KcRDMV](https://goo.gl/KcRDMV)



12. Suzuoki M, Kondo S, Ambo Y, Hirano S, Omi M, et al. (2002) Treatment of Budd-Chiari syndrome with percutaneous transluminal angioplasty: report of a case. *Surg Today* 32: 559-562. [Link: https://goo.gl/pxqzNK](https://goo.gl/pxqzNK)
13. Gu YM, Yang RJ (2005) Application of percutaneous transluminal angioplasty and stent placement at the third hepatic porta in treatment of Budd- Chiari

- syndrome. *Zhonghua Yi Xue Za Zhi* 85: 240-243. [Link: https://goo.gl/DpG7tb](https://goo.gl/DpG7tb)
14. Sun J, Zhang Q, Xu H, Huang Q, Shen B, et al. (2014) Clinical outcomes of warfarin anticoagulation after balloon dilation alone for the treatment of Budd-Chiari syndrome complicated by old inferior vena cava thrombosis. *Ann Vasc Surg* 28: 1862-1868. [Link: https://goo.gl/xyGp5o](https://goo.gl/xyGp5o)

**Copyright:** © 2017 Vishwanath H. This is an open-access article distributed under the terms of the Creative Commons Attribution License, which permits unrestricted use, distribution, and reproduction in any medium, provided the original author and source are credited.