



Sachin Metkari^{1*} and Manisha Metkari²

¹Assistant professor, Dept. of conservative dentistry & Endodontics, Nair Hospital Dental College, Mumbai, India

²Dental Surgeon and private practitioner, Mumbai, India

Dates: Received: 01 April, 2017; **Accepted:** 19 June, 2017; **Published:** 20 June, 2017

***Corresponding author:** Sachin Metkari, Assistant professor, Department of conservative dentistry & Endodontics, Nair Hospital Dental College, Mumbai, India, E-mail: drssmetkari@yahoo.co.in

Keywords: Richmond crown; Post and core; Over jet; Overbite

<https://www.peertechz.com>

Case Report

Successful Rehabilitation of Anterior Crowns with Richmond Crown: Case Series

Abstract

Restoration of severely fractured/ decayed teeth requires crown restoration after endodontic therapy which is often major requisite in conservative dentistry. If there is steep incisal guidance and very less overjet then restoration of such crown is not possible with routine post and core followed by crown restoration because of very less incisal clearance. Richmond crown is advisable in such cases as it is single-unit post retained crown with porcelain facing design. Two cases have been discussed here with Richmond crown treatment modality over 2-3 years successful follow-up.

Introduction

Restoration of endodontically treated teeth has always been challenge in dentistry. Grossly carious crowns, severe fracture of teeth involving more than two-third of crown structure requires additional retention from root canal for crown restoration especially after root canal therapy. In such cases post and core treatment modality has been advised. If such cases became complicated with deep bite and minimum overjet then it will be very difficult to place a prosthetic crown. Richmond crown can be placed in such situation as it does not require cemental interface between post- core and crown. This can also be advised in deep-bite cases involving minimum overjet with severely destructed tooth structure.

Richmond crown is a single-piece, post-retained crown with a porcelain facing designed to function as bridge retainer. Richmond crown is not a post and core system but it is customized castable post and crown system as both are single unit and casted together. It is easy to make cast metal restoration with aid of posts for long term retention [1].

Here, we have discussed two case reports one with fractured upper left central incisor involving Elli's type III fracture complicating severe deep bite and very minimum overjet. Other case was having repeatedly dislodged crown in relation to upper left lateral incisor with minimum amount of tooth structure remaining. In both the cases crown was restored with Richmond crown treatment modality. We perceived successful follow-up for 2 years and 3 years respectively.

Case Report 1

25 years old male healthy patient reported with the chief complaint of fracture of upper left central incisor (Figure 1). Patient was conscious, cooperative and well-oriented with time, space and environment. He met with an accident and fell down on floor with the face downward. He noticed that his upper anterior tooth was fractured and blood oozing from the tooth. He tried to stop bleeding with handkerchief and immediately rushed to local physician. Physician put gauze in between teeth to stop bleeding and administered painkiller injection followed he asked patient to visit dentist.

Intraoral examination and removal of fracture fragment

Clinical examination showed that he got fractured upper

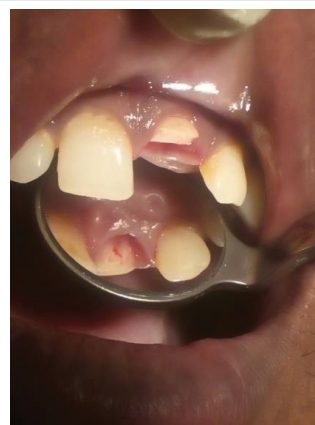

Figure 1: Fracture of upper left central incisor with open pulpal chamber.

left central incisor (21) [Elli's class III fracture]. Palatal part of crown portion of upper left central incisor was mobile and fracture line was below gingival margin on palatal side. There was severe overbite and very less overjet in anterior segment of occlusion. Patient was not able to close his teeth in occlusion as fractured tooth was very tender. Prognosis for the reattachment of fractured fragment was very poor as tooth fracture line was below gingival margin. So it was decided that the fractured fragment of tooth should be removed, root canal therapy should be done and Richmond crown should be placed. Patient's written consent was obtained after explaining all advantage and drawback of treatment. Local anaesthesia (lignocaine with adrenaline, 1:100000, Makcur Laboratories, limited, Gandhinagar, India) was administered and fractured fragment was removed.

Endodontic therapy

After removal of fracture tooth fragment, bleeding was stopped and endodontic therapy was carried out. Cleaning and shaping was completed with X-smart protaper rotary endodontic system (Dentsply Maillefer, Japan) followed by no. 30 single cone obturation was done. Patient was recalled after two days. He was asymptomatic but he was very much concerned about esthetic of teeth hence he had difficulty in socializing. So he demanded to restore his fractured tooth as early as possible.

Crown structure preparation

Seven days after successful root canal therapy of left maxillary lateral incisor remaining crown structure was prepared circumferentially for Richmond crown. Shoulder finish margin was prepared on buccal surface and chamfer on palatal surface with creating adequate ferrule.

Post and core preparation

Then after, post space was prepared with peeso reamer no.1 and no.2 (Nordin, stainless steel, Switzerland). Retraction cord (Ultradent product INC Rx South Jordan, Utah, 84095, USA) was used for isolation and retraction of marginal gingiva around the lateral incisor and indirect impression was made for customized post and core in relation with fractured lateral incisor. Impression of post space was done with light body addition silicone impression material (Take1 Advanced Kerr Corporation, 28200, wick road, Romulus, MI 48174, USA). 21 guage orthodontic wire (Pigeon Dental stainless steel, India) was adjusted in post space area and length was confirmed on radiograph. Outer end of wire was made J-shaped. Light body was flooded in post space and immediately j-shaped adjusted orthodontic wire was inserted in post space. Full arch impression was made with j-shaped wire in position using light body and putty of addition silicone impression material (Care was taken not to disturb apical seal).

Fabrication of porcelain facing metal crown

Wax pattern (Inlay wax medium-green, GC, IWM. GRN, GC Japan) for Post and core was prepared on die with proper ferrule in core. Casting of post and core was made and fabrication was completed in base metal alloy. Placing the post and core in

position impression was made for preparing porcelain facing metal crown (Figures 2,3).

Placement of crown

Final crown is placed in position and occlusion correction was made. High points were recorded and corrected. Final cementation was done with Type I glass ionomer cement (GC, Japan) (Figures 4,5).

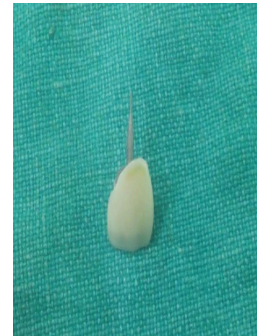

Figure 2: Facial surface of Richmond crown.

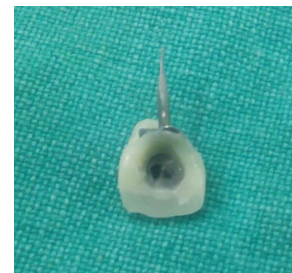

Figure 3: Palatal surface of Richmond crown.

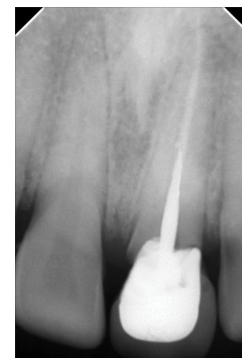


Figure 4: Intraoral periapical radiograph after placement of crown with upper left central incisor.

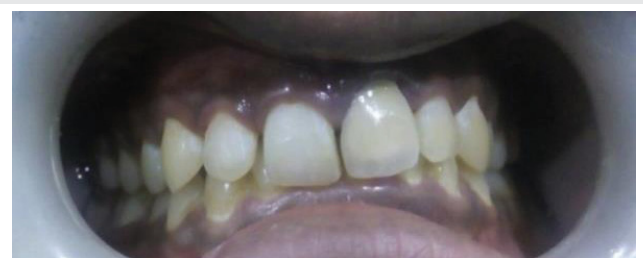

Figure 5: Placement of crown with upper left central incisor.

Case Report 2

48 yrs old female healthy patient complaint of repeated dislodgement of crown in relation to upper left lateral incisor. Tooth was root canal treated and crown restored 10 year back. But six months back it was fractured after accidental blow on face. Private dentist again restored crown two times in last six month interval. But repeatedly it got dislodged. She came with fractured upper left lateral incisor and dislodged crown. Patient was unsatisfied and wanted to get rid of it. She had been explained about extraction and implant placement in relation to fractured upper lateral incisor. She was not convinced for extraction so Richmond crown technique was explained as alternative treatment. Patient's written consent was obtained after explaining all pros and cons of technique.

Similar procedure was followed as earlier case for restoration of Richmond crown in relation to upper left lateral incisor (Figures 6-8).

Discussion

Restoration of endodontically treated teeth involved major aspect in restorative dentistry. Loss of too much tooth structure due to caries/fracture/developmental disorders always had challenge in restorative procedure. Remaining tooth structure is not enough to retain large prosthetic crown in such cases [2].

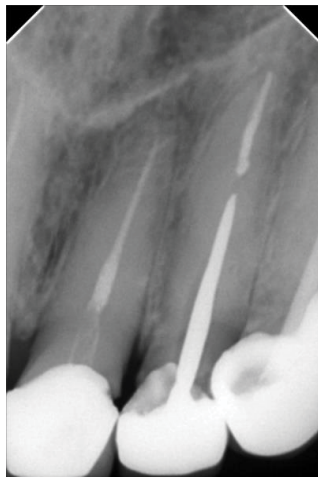


Figure 6: IOPA of upper left lateral incisor with Richmond Crown placement.

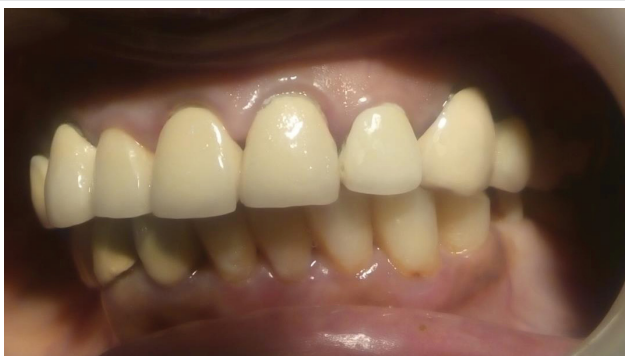

Figure 7: Side view after restoration of upper left lateral incisor with Richmond crown.

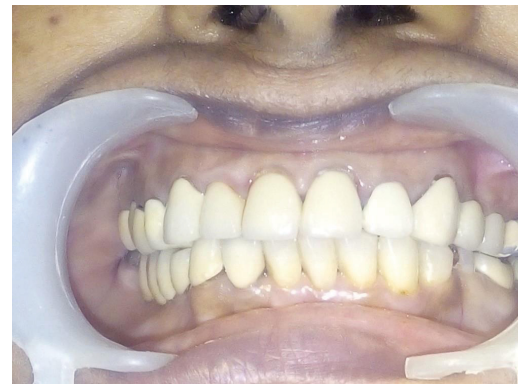

Figure 8: Front view of Richmond crown in relation to upper left lateral incisor.

Post and core treatment has been successfully practiced since ages [3]. Alternative procedure needed to obtain remaining crown structure so as to manage arc of rotation under oblique forces (function) such as crown lengthening procedure or forceful orthodontic extrusion. Many causes of failure of post and core retained restorations have been identified, including: recurrent caries, endodontic failure, periodontal disease, post dislodgement, cement failure, post-core separation, crown-core separation, loss of post retention, core fracture, loss of crown retention, post distortion, post fracture, tooth fracture, and root fracture. Also, corrosion of metallic posts also has been proposed as causes of fracture [4-6].

To overcome these problems Richmond crown can be advised in cases where there is deep bite, very less overjet and less occlusal clearance like in first case.

The Richmond crown was introduced in 1878 and was incorporated as single piece post-retained crown with porcelain facing. Initially it was having a threaded tube in the canal with a screw retained crown, which was later modified to eliminate the threaded tube and was redesigned as a 1-piece cast dowel and crown. Design include casting of post and crown coping as single unit over which ceramic is fired and cemented inside canal and over prepared crown structure having same path of insertion. Ferrule collar is incorporated to increase mechanical resistance, retention apart from providing antirotational effect. Major technical drawback of this design is excessive cutting in making two different axis parallel which results in weakening of tooth and also this design increases stresses at post apex causing root fracture. Few indications for Richmond crown are grossly decayed or badly broken single tooth where remaining crown height is very less and in cases with steep incisal guidance [7] (deep bite and very less overjet).

As in first case there was hardly any tooth structure remaining for preparation and there was deep overbite and very less overjet so it was ideal case for Richmond crown. Also less cervical tooth structure subjected to flexion forces under function and this design provides more cervical stiffening than other post system and is needed to protect the crown margins and to resist leakage. As there was deep bite and very less overjet so there would be very inadequate clearance for post and core as also crown placement. Considering all the factors Richmond crown was advised for restoration of crown.

Second case was repeated failure of conventional crown. There was less amount of remaining tooth structure and was very deep bite. Such tooth if given with post and core first over which crown is cemented, needs adequate thickness which is a limitation here. To compensate this inadequacy if core is made thin then it is weak and also presents sharp margins and edges acting as stress points for overlying crown. Richmond crown is best possibility in both these conditions as less crown cutting is required to make two axis parallel in grossly decayed tooth and also it require less thickness for best esthetic results. The advantages of this design are custom fitting to the root configuration, little or no stress at cervical margin, high strength, availability of considerable space for ceramic firing and incisal clearance, eliminate cement layer between core and crown so reduces chances of cement failure [8].

The operator should consider all pros and cons of all types of post and core systems as well as Richmond crown treatment modality and select a procedure that fulfills the needs of the case while maximizing retention and minimizing stress. Drawback of Richmond crown technique needs single path of insertion and withdrawal so more of tooth preparation is required. But in cases of loss of maximum tooth structure Richmond crown was definitely advised as there is no need for further tooth preparation. Although any number of post designs may be used in a clinical situation, success is dictated by the remaining tooth structure available after endodontic therapy. Conservation of the tooth should be always first preference than extraction followed by crown and bridge/implant treatment modality. As

later treatment need more invasive procedure with lot of time required. Still some traditional techniques are useful in some cases according to conditions as per need.

References

1. Bhushan K, Shaiba S, Prabhdeep KS, Sunny B, Sachin M (2014) Current status on Richmond crown: an overview on this forgotten treatment. IJRID 4: 1-7. [Link: https://goo.gl/rB1YTV](https://goo.gl/rB1YTV)
2. Hudis SI, Goldstein GR (1986) Restoration of endodontically treated teeth: a review of the literature. J Prosthet Dent 55: 33-38. [Link: https://goo.gl/JLURhC](https://goo.gl/JLURhC)
3. Fernandes AS, Dessai GS (2001) Factors affecting the fracture resistance of post-core reconstructed teeth: a review. Int J Prosthodont 14: 355-363. [Link: https://goo.gl/Mxkycj](https://goo.gl/Mxkycj)
4. Assif D, Bitenski A, Pilo R, Oren E (1993) Effect of post design on resistance to fracture of endodontically treated teeth with complete crowns J Prosthet Dent 69: 36-40. [Link: https://goo.gl/kkwQ8T](https://goo.gl/kkwQ8T)
5. Roberts DH (1970) The failure of retainers in bridge prostheses. An analysis of 2,000 retainers. Br Dent J 128: 117-124 [Link: https://goo.gl/16osGJ](https://goo.gl/16osGJ)
6. Zuckerman GR (1996) Practical considerations and technical procedures for post-retained restorations. J Prosthet Dent 75: 135-139. [Link: https://goo.gl/eSWfhk](https://goo.gl/eSWfhk)
7. Dod A (2016) Managing fractured central incisor with Richmond crown –A Case report. Journal of Applied Dental and Medical Sciences 2: 57-62. [Link: https://goo.gl/HF6h6f](https://goo.gl/HF6h6f)
8. Dausage P, Mallikarjuna K, Shilpi Gupta, Jayant Marya (2015) Richmond crown esthetics importance for lost tooth structure. University J Dent Scie 3: 60-63. [Link: https://goo.gl/DhWwFQ](https://goo.gl/DhWwFQ)