

Georgina Fuertes Ferre*, Galache Osuna JG, Diarte de Miguel JA and Sánchez Rubio J

Interventional Cardiology Unit, Miguel Servet University Hospital, Zaragoza, Spain

Dates: Received: 25 April, 2017; Accepted: 19 May, 2017; Published: 22 May, 2017

*Corresponding author: Georgina Fuertes Ferre, Interventional Cardiology Unit, Miguel Servet University Hospital, Paseo Isabel la Católica 1-2, 50001, Zaragoza, Spain, Tel: +34/976 76 55 00; Fax: +34/976 56 25 65; E-mail: georginaff@hotmail.com

Keywords: Coronary artery aneurysm; Covered stent; Optical coherence tomography

<https://www.peertechz.com>

Letter to Editor

Large Thrombotic Coronary Artery Aneurysm Treated With a Covered Stent Using OCT for Procedural Guidance

Covered stents have been classically used to seal coronary perforations and vein grafts [3]. It was proposed that the CS technology could be useful to seal the vessel lumen of coronary aneurysms. In this case of a large CAA complicated with an acute myocardial infarction the Papyrus CS demonstrated to be feasible and safe. The optimal imaging of OCT could provide a more accurate measurement of the CAA and vessel margins helping us to choose the appropriate stent. Despite initial excellent result a close follow up is needed because of the increased risk of restenosis and thrombosis described in these types of stents [4].

Letter to Editor

Coronary artery aneurysm (CAA) is an uncommon finding in patients undergoing a coronary angiography, with an incidence of less than 5% [1]. CAA is defined as coronary dilation of more than 1,5 times the adjacent vessel diameter. The majority of CAA in adults are of an atherosclerotic origin [2].

Treatment of CAA remains challenging. In the past years surgery was the only successful approach of symptomatic CAA associated with coronary artery stenosis. Lately a less aggressive strategy has emerged with the inclusion of covered stents (CS). However the number of reported cases of CS in the treatment of CAA is low.

We present a case of a 79 years old man admitted to our hospital for a non ST-segment elevation acute myocardial infarction. The coronary angiogram revealed a large CAA at the proximal portion of the ramus intermedius followed by a severe stenosis. There was a large amount of intraluminal thrombus within the aneurysm (Figure 1A). In order to treat the coronary stenosis and exclude the large thrombotic CAA it was decided to use a CS. Optical coherence tomography (OCT) was performed before percutaneous coronary intervention (PCI) which was useful to choose stent dimension (Figure 1B). A 3x26mm polyurethane Papyrus stent (Biotronik, Berlin, Germany) was positioned in the proximal intermedius vessel after balloon predilation (Figure 1C). No distal embolization occurred. The final angiogram and OCT demonstrated the complete exclusion of the CAA as well as stenosis elimination (Figure 1D). The patient was discharged with the association of Acetylsalicylic acid and Ticagrelor, no anticoagulation was prescribed.

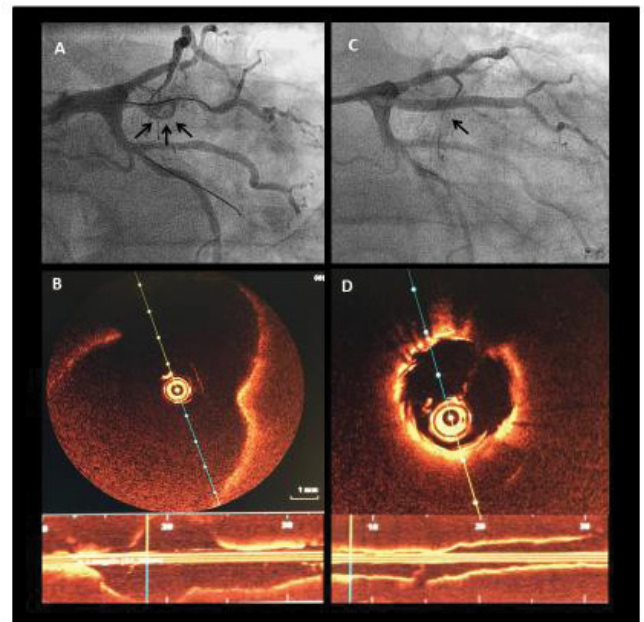


Figure 1: Baseline and interventional findings. A, anterior-posterior caudal angiographic view showing the large thrombotic coronary aneurysm (CAA) at the proximal portion of the ramus intermedius. B, Optical coherence tomography (OCT) longitudinal and cross-sectional views at the site of the CAA (16x9, 5mm). C, Intermediate ramus after PTFE stent implantation with complete CAA exclusion. D, OCT after stent implantation.

References

1. Swaye PS, Fisher LD, Litwin P, Vignola PA, Judkins MP, et al. (1983) Aneurysmal coronary artery disease. *Circulation* 67: 134-138. [Link: https://goo.gl/rpdoKA](https://goo.gl/rpdoKA)
2. Syed M, Lesch M (1997) Coronary artery aneurysm: a review. *Prog Cardiovasc Dis* 40: 77-84. [Link: https://goo.gl/COKmyd](https://goo.gl/COKmyd)
3. Elsner M, Auch-Schwelk W, Britten M, Walter DH, Schächinger V, et al. (1999) Coronary stent grafts covered by a polytetrafluoroethylene membrane. *Am J Cardiol* 84: 335-338. [Link: https://goo.gl/e6rO6R](https://goo.gl/e6rO6R)
4. Briguori C, Sarais C, Sivieri G, Takagi T, Di Mario C, et al. (2002) Polytetrafluoroethylene-covered stent and coronary artery aneurysm. *Catheter Cardiovasc Interv* 55: 326-330. [Link: https://goo.gl/irvmEY](https://goo.gl/irvmEY)

Copyright: © 2017 Ferre GF, et al. This is an open-access article distributed under the terms of the Creative Commons Attribution License, which permits unrestricted use, distribution, and reproduction in any medium, provided the original author and source are credited.