

Ashok Dongol^{1*}, Pradeep Acharya²,
Ram Prasad Yadav³, Arun Kumar
Mahat⁴, Anjani Kumar Yadav⁵, Ashish
Shrestha⁶ and Mehul Rajesh Jaisani⁷

¹MDS, Oral and maxillofacial surgery, Ghopa camp, BP Koirala Institute of Health Sciences, Dharan, Nepal

²Assistant Professor, Oral and maxillofacial surgery, BP Koirala Institute of Health Sciences, Nepal

³Former resident, Oral and maxillofacial surgery, BP Koirala Institute of Health Sciences, Nepal

⁴Assistant Professor, Oral and maxillofacial surgery, Nepalgunj medical college, Nepal

⁵Assistant Professor, Oral and maxillofacial surgery, BP Koirala Institute of Health Sciences, Nepal

⁶Associate Professor, Oral pathology, BP Koirala Institute of Health Sciences, Nepal

⁷Associate Professor, Oral and maxillofacial surgery, BP Koirala Institute of Health Sciences, Nepal

Dates: Received: 09 May, 2017; Accepted: 26 June, 2017; Published: 28 June, 2017

***Corresponding author:** Ashok Dongol, Assistant Professor, MDS, Oral and maxillofacial surgery, Ghopa camp, BP Koirala Institute of Health Sciences, Dharan, Nepal, Tel: +9779841393082; E-mail: ashokdongol@hotmail.com

Keywords: Transmigration; Canine; Kissing; Dentigerous cyst

<https://www.peertechz.com>

Case Report

Kissing canines associated with dentigerous cyst, a case report of transmigrated bilateral impacted mandibular canines

Abstract

Transmigration, a phenomenon most often involving mandibular canine, refers to the migration of an unerupted tooth from its normal position to the contralateral side. Bilateral mandibular canine impaction with transmigration is a rare occurrence. These canines may exhibit kissing phenomenon in the radiograph. Very few cases of bilaterally impacted canines associated with dentigerous cyst have been reported. The case reported here deals with the management of kissing canines associated with dentigerous cyst.

transmigrated to meet each other across the midline. However the reports of kissing canines are scanty in the literature [4,6,7].

Case Report

A 32-year-old male patient presented to the department of oral and maxillofacial surgery with chief complaint of swelling in the front region of lower jaw for six months. The swelling gradually increased in size without any pain, discharge or altered sensation. There was no significant medical history as such. No history of any trauma to the site. This was the patient's first dental visit.

On examination there was a soft, non-tender swelling of size around 3X2 cm² in the anterior mandible with expansion of labial cortex. Retained deciduous teeth with respect to 73 and 83 were present. 41, 42, 31, 32 were grade I mobile. Vitality with electric pulp test revealed vital mandibular anterior teeth while 34 responded at 8.

Orthopantomograph revealed impacted 43 and 33 lying horizontally, both crossing the midline, with 33 lying above the inferior border of the mandible while 43 lying just above 33 and subapical to anterior mandibular incisors. The two transmigrated canines demonstrated kissing phenomenon. There was a unilocular radiolucency of approximately 3X2 cm² around the crown as well as the lateral root aspect of the impacted teeth with well-defined sclerotic borders suggestive of cystic changes. The lesion appeared to be attached to the

Introduction

Dental transmigration is an infrequent phenomenon in which an unerupted tooth migrates from its normal position to the contralateral side, crossing the midline [1]. Such a migrated tooth remains impacted most of the times. Transmigration occurs almost exclusively with mandibular canines involving a single side as a unilateral phenomenon. Bilateral mandibular canine impaction with transmigration is a rare occurrence.

Like all impacted teeth, a transmigrated impacted canine may develop a cystic lesion. Dentigerous cyst is the most common odontogenic cyst associated with impacted teeth [2]. Very few cases of dentigerous cyst associated with bilaterally impacted canine have been reported [3,4]. The term 'kissing' in dentistry was first described by Van Hoof when he reported a case of impacted permanent molars that had occlusal surfaces contacting each other within a single follicular space with roots of each pointing in opposite directions [5]. Similar occurrence of kissing phenomenon can be associated with canines when both the canines from the same jaw are impacted as well as

cemento–enamel junctions of both teeth. Apical root resorption with respect to 34 was also observed [Figure 1]. Aspiration yielded chocolate brown colored fluid.

Differential diagnosis considered were dentigerous cyst, adenomatoid odontogenic tumor, unicystic ameloblastoma, radicular cyst.

Enucleation of the cyst along with extraction of the impacted canines was done under general anesthesia. Splitting of 33 was required for removal whereas 43 was removed in total along with the cystic lining [Figures 2,3]. 34 was planned for endodontic therapy. Extraction of 73 and 83 was done. The patient was further planned for prosthetic rehabilitation. Postoperative recovery was good with satisfactory wound healing. Biopsy report revealed features suggestive of dentigerous cyst with presence of thin non-keratinised, stratified squamous epithelium with odontogenic islands in the connective tissue [Figure 4].

Discussion

Canine transmigration requires significant consideration in dentistry regarding interceptive, esthetic, orthodontic and surgical concerns. Transmigration usually involves a single mandibular canine with only 37 cases of bilateral transmigration of mandibular canines reported so far [8]. Bilateral mandibular canines when transmigrated can exhibit kissing phenomenon in the radiograph [4,6]. The case reported here is similar to the kissing phenomenon described by Van Hoof, as the crowns of canines are contacting each other within a single follicular space with the roots pointing in the opposite directions [5]. Very few cases of kissing canines have been reported [4,6]. The etiology of transmigration is unknown. Different hypotheses for transmigration suggested in the literature are abnormal displacement of the tooth bud or deviation during development, abnormal strong eruption force or a change which affects the crypt of the tooth germ, premature loss of deciduous teeth, osteodental discrepancy, endocrinopathy, hereditary factors, and trauma [8].

Usually transmigrated mandibular canines are asymptomatic. These can be suspected in absence of permanent canines from the arch or the presence of over-retained primary canines and thus can be confirmed by intraoral and panoramic radiographs. Sometimes they can be associated with swelling in the vestibule due to cystic changes as was present in our case. Dentigerous cyst is the most commonly associated cyst

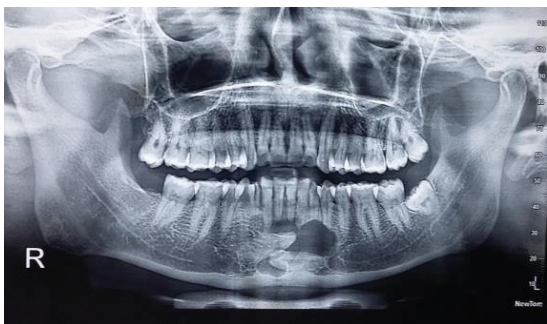

Figure 1: Orthopantomograph showing transmigrated kissing canines 43 and 33 with unilocular radiolucency suggestive of cystic changes.

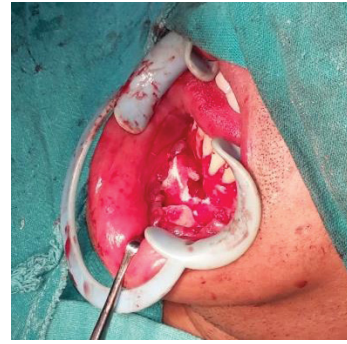

Figure 2: Exposure of the surgical site.

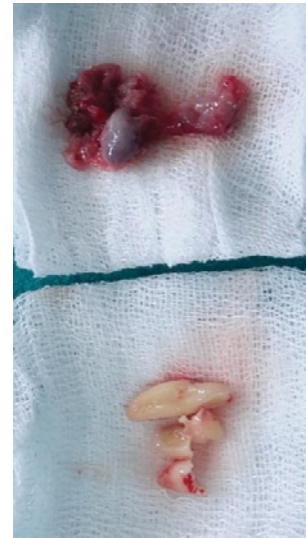


Figure 3: Enucleated cystic lining along with extracted impacted canines.

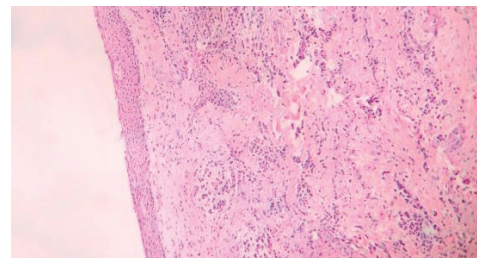


Figure 4: Cystic lumen lined by non-keratinised, stratified squamous epithelium suggestive of Dentigerous cyst (H&E stains; 10 X).

with the impacted teeth [2]. It arises by the accumulation of fluid between reduced enamel epithelium and the impacted tooth crown. Dentigerous cyst appeared to be associated with both the impacted canines in the present case as the cystic lining was around the crown as well as the lateral root aspect of both the impacted teeth. This could be due to coalescence between two adjacent dentigerous cyst linings. But the other possibility that one dentigerous cyst enlarged and enclosed the other impacted canine cannot be ruled out in the absence of previous radiographs. Similarly, whether the cyst influenced on the migration of the impacted teeth or the teeth migrated before the formation of the cyst is unclear owing to the fact that patient sought for dental treatment only after the swelling started.

Management of transmigrated mandibular canines includes periodic observation, exposure and orthodontic alignment, transplantation, extraction. Transmigrated canines if detected early can be observed periodically over time to monitor their development and movement, which may improve prognosis and treatment as sometimes they can be preserved with orthodontic treatment and transplantation. Surgical extraction is the treatment of choice in patients with transmigrated canines associated with pathology. So enucleation of the cyst along with extraction of the impacted teeth as well as primary canines was done in our case.

Conclusion

Bilateral mandibular canine transmigration can exhibit kissing phenomenon and can be associated with dentigerous cyst. Surgical management with extraction and removal of the pathology is preferred in cases involved with cystic changes.

References

1. Joshi MR (2001) Transmigrant mandibular canines: a record of 28 cases and a retrospective review of the literature. *Angle Orthod* 71: 12–22. [Link: https://goo.gl/YnH1TS](https://goo.gl/YnH1TS)
2. Daley TD, Wysocki GP, Pringle GA (1994) Relative incidence of odontogenic tumors and oral and jaw cysts in a Canadian population. *Oral Surgery, Oral Med Oral Pathol* 77: 276–280. [Link: https://goo.gl/bJSZnw](https://goo.gl/bJSZnw)
3. Gonzalez SM, Spalding PM, Payne JB, Giannini PJ (2011) A dentigerous cyst associated with bilaterally impacted mandibular canines in a girl: a case report. *J Med Case Rep* 5: 230. [Link: https://goo.gl/d4jFQ9](https://goo.gl/d4jFQ9)
4. Omami G, Mathew R (2015) Kissing Canines Associated with a Dentigerous Cyst: Case Report and Mini Review. *Int J Dent Oral Sci* 84–86. [Link: https://goo.gl/GMTAMS](https://goo.gl/GMTAMS)
5. Van Hoof RF (1973) Four kissing molars. *Oral Surg Oral Med Oral Pathol* 35: 284. [Link: https://goo.gl/bvniGC](https://goo.gl/bvniGC)
6. Sharma S, Raghavan V, Kumari S (2014) Kissing mandibular canines: Serendipity at its best. *J Indian Acad Oral Med Radiol* 26: 82–84. [Link: https://goo.gl/LS2LTk](https://goo.gl/LS2LTk)
7. Ahmad SA, Ahmad SS, Poddar RN, Masood R (2013) Bilateral Transmigration of Mandibular Canines-A Case Report and Review of Literature. *IOSR J Dent Med Sci* 3: 56–59. [Link: https://goo.gl/Qii2pS](https://goo.gl/Qii2pS)
8. Díaz-Sánchez R-M, Castillo-de-Oyagüe R, Serrera-Figallo M-Á, Hita-Iglesias P, Gutiérrez-Pérez J-L, Torres-Lagares D (2016) Transmigration of mandibular cuspids: review of published reports and description of nine new cases. *Br J Oral Maxillofac Surg* 54: 241–247. [Link: https://goo.gl/PdvRc2](https://goo.gl/PdvRc2)