



Saurabh Chaturvedi^{1*}, Mohammed A Alfarsi², Mudita Chaturvedi³, Kaushik Pandey⁴ and Sunil Kumar Vaddamanu⁵

¹Assistant Professor, Department of Prosthetic Dentistry, College of Dentistry, King Khalid University, Abha, Saudi Arabia

²Assistant Professor & Head of Department, Department of Prosthetic Dentistry, College of Dentistry, King Khalid University, Abha, Saudi Arabia

³Assistant Professor, Department of Oral Pathology, Career Post Graduate Institute of Dental Sciences, Lucknow, India

⁴Assistant Professor, Department of Prosthetic Dentistry, Career Post Graduate Institute of Dental Sciences, Lucknow, India

⁵Assistant Professor, Department of Dental Technology, King Khalid University, Abha, Saudi Arabia

Dates: Received: 27 May, 2017; Accepted: 15 June 2017; Published: 16 June, 2017

***Corresponding author:** Saurabh Chaturvedi, Assistant Professor, Department of Prosthetic Dentistry, College Of Dentistry, King Khalid University, Abha, Kingdom of Saudi Arabia, Tel: 0580697248; E-mail: smc1@live.in

Keywords: Immediate implant; Extraction; Ridge graft

<https://www.peertechz.com>

Case Report

Immediate Implant with simultaneous Ridge Augmentation

Abstract

The Ultimate goal of prosthetic replacement following teeth loss, is to provide a functional restoration that is harmonious with the remaining natural dentition. To achieve this goal hard and soft tissues should be properly healed with good quality and adequate volume.

In the anterior maxilla the degree of horizontal bone resorption in post extraction site is nearly twice as high as that of vertical bone resorption during first month. An increasingly common strategy is to preserve bone that includes the placement of dental implant into fresh extraction site. Immediate implant placement reduces the amount of time anticipated for loading and the number of surgical interventions which in turn yields higher patient's satisfaction.

Finally elimination of the wait period for primary healing of the soft tissues and regeneration of osseous structure significantly shortens the overall treatment time and transitional state without teeth. This short communication about immediate implant case reflects upon several steps followed for an immediate placement of dental implant in fresh extraction socket and outlines its advantages.

larger and tapered implant and/or bone graft material should be used to minimize the possibility of healing with soft tissue between the implant and bone. Schwartz-Arad and Chaushu [9] reported that bone chips collected adjacent to implant sites could be used to fill the defects without the use of membrane if the wounds could be closed by coronally repositioned flaps. An alternative technique known as Socket Shield Technique (SST) is an alternative approach to limiting remodeling and resorption by retaining the facial part of the root during tooth extraction. An immediately placed implant supports the facial root fragment, preventing the collapse of the buccal wall. The SST reduces the number of surgical and prosthetic interventions required to one each for pre-operative planning, surgical procedures, and prosthetic rehabilitation. The SST is a minimally invasive implantological approach offers patients and clinicians multiple benefits [10].

In this case report, immediate implant placement with simultaneous ridge augmentation in the anterior region is described. The final restoration was in complete harmony with the surrounding hard and soft tissue and yield high degree of satisfaction from the patients.

Case Presentation

A 24 year old male patient reported to the dental clinic with the complaint of un-esthetic look in relation to upper anterior

Introduction

Immediate implant placement refers the implant placed immediately into the socket after tooth extraction [1]. It is regarded as a sustainable technique; provided that proper patient selection and meticulous surgical procedures are implemented [2]. Clinical studies have demonstrated that the success rate of immediately placed implants is similar to that implants placed after healing of extraction sites [3-5]. A key factor in esthetic success is presence or absence of adequate alveolar bone (height, volume, and thickness of the cortical plate) at the implant site, since the gingival contour follows the underlying osseous crest [6-7].

In maxilla, atrophy is more severe during the first month of post-extraction and the loss of buccal alveolar plate following tooth extraction may lead to palatal positioning of the implants [8]. Following alveolar bone loss, an immediately placed implant should engage the bone apical to the socket for primary stability. In addition, if the angulations and location of the implant is different from the extraction socket, either a

region. Patient had no positive medical history. Clinical and radiographic examination showed missing crown portion and fractured root with approximately 6 mm below the gingival margins in relation to maxillary left central incisor (Figure 1).

Critical assessment of the site

Deep sub gingival fracture on palatal side in relation to maxillary left central incisor with unfavorable prognosis. Missing area had the space of 8 mm mesiodistally and 7 mm buccolingually (Figure 2a,b). Disharmony in gingival margin with no crowding was seen in the anterior maxillary region. There was no periapical or periodontal pathology in relation to maxillary left central incisor and had flattened gingival zenith and thick biotype (Figure 3).

Treatment plan

The patient was detailed about his present state, alternative treatment plans, and procedure were explained. Informed consent was obtained from the patient. Treatment with immediate placement of dental implant with simultaneous ridge augmentation was planned in relation to maxillary left central incisor. Implant size 4.2 x 11 mm was decided on the basis of clinical and radiographic findings.

Treatment procedure

Immediately before the procedure, patient was asked to rinse his mouth for 2 minutes with a 0.12% chlorhexidine digluconate solution. Following an injection of 2% lignocaine with 1:80,000 epinephrine local anesthetic (Lignospan Special, Septodont), atraumatic extraction of the remaining root portion was done with the help of periosteal elevator (Figure 4). The extraction socket was thoroughly debrided and degranulated. Implant desired position was located with surgical template and sequential drilling was performed, following this implant was placed with insertion torque of 40 Ncm (Figure 5a,b). After hand-tightening, marginal gap voids about 2-3 mm in width were noted between implant surface and the buccal cortex. The marginal voids were grafted with deproteinized bovine bone (Bio-Oss, Geistlich A G, Wolhusen, Switzerland), the flap was repositioned and the wound was closed by means of single sutures (Figure 6). Immediate temporization was done with acrylic tooth, which was splinted with the adjacent teeth with fiber-bond splint. The patient was placed on amoxicillin 500mg thrice daily for 5 days, mefenamic acid 500mg initially, then 250mg four times a day for 5 days and asked to do gargle

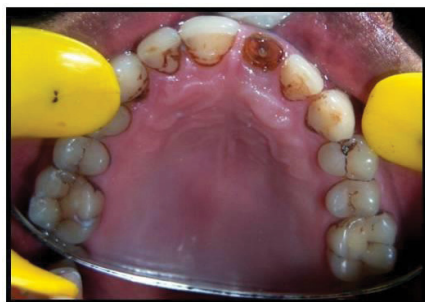

Figure 1: Fractured root stump in relation to left central incisor.

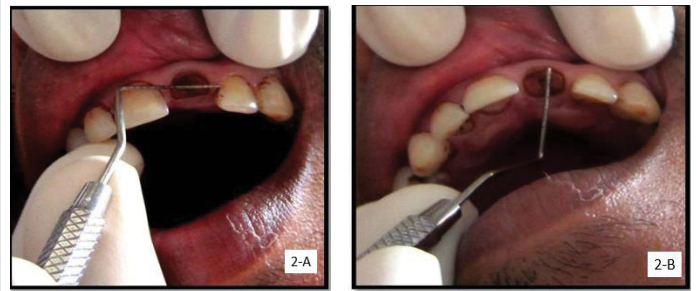


Figure 2a,b: Assessment of the mesio-distal and bucco-lingual width.

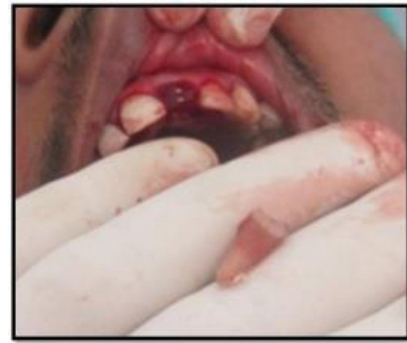

Figure 3: Diagnostic Radiograph #21.

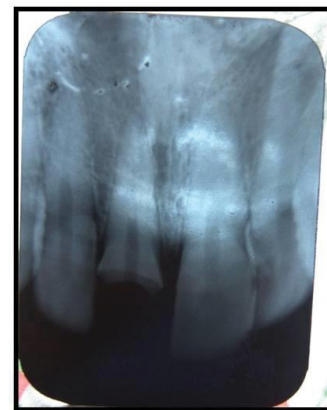

Figure 4: Atraumatic Extraction of root stump # 21.

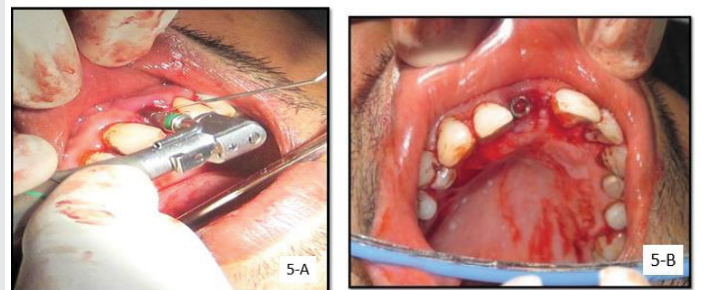


Figure 5a,b: Sequential drilling. Showing implant placed at osteotomy site.

with chlorhexidine digluconate .12% twice daily for two weeks. The patient reported with no specific symptoms and adverse clinical signs.

In second stage surgery after 3 month gingival former was

placed and left for 1 week for soft tissue recontouring (Figure 7). Closed tray transfer with indirect transfer coping was used to make impression with polyvinylsiloxane (Figure 8). Abutment was milled and verified in patient's mouth. Shade selection was done and final prosthesis was cemented with non-eugenol cement (Figure 9). Patient recalled regularly after one week, one month and six month interval to evaluate the situation and was found normal. The prosthesis was well in function up to the final evaluation. Follow up was continued till 2 years. The soft tissue health and width of the ridge was well maintained with good esthetic result.

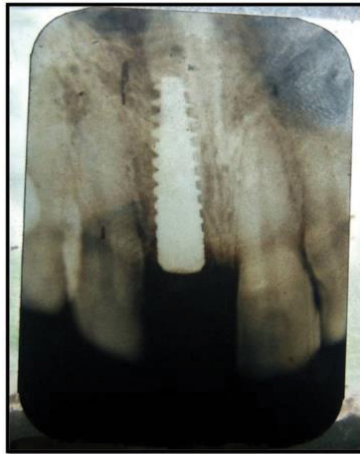

Figure 6: Post-operative Radiograph showing implant # 21.

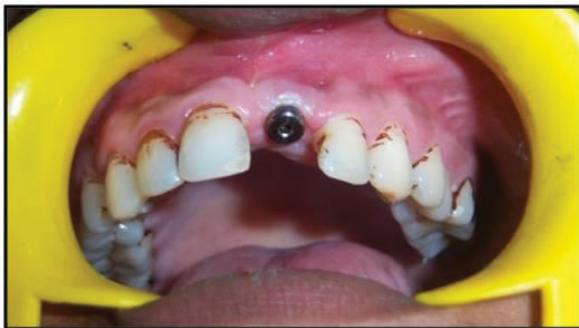

Figure 7: Gingival former placed in second stage surgery.

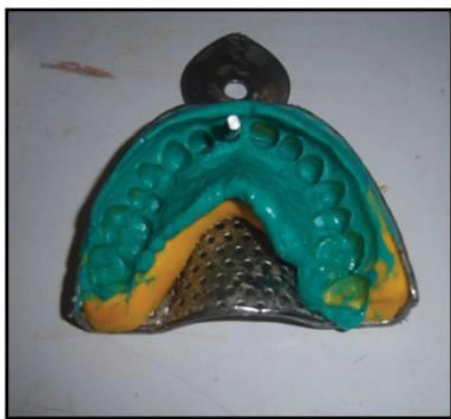

Figure 8: Closed tray impression with abutment and analogue.

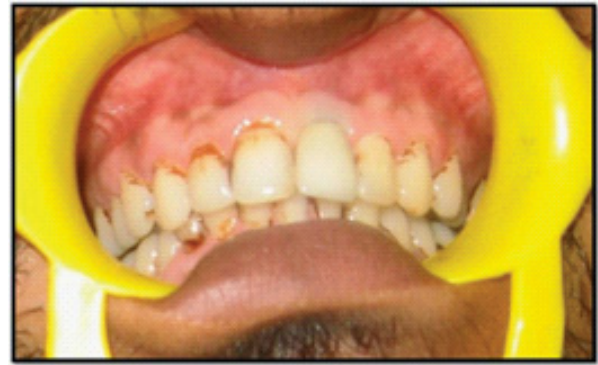

Figure 9: Final prosthesis delivered # 21.

Discussion

Ultimate result of tooth loss is reduction in bone volume, density, height and width. This results in a situation that corresponds to a condition where the sufferer will not only have compromised function but also esthetics and psychology. In this case report, the harmony of soft and hard tissue was achieved by immediate implant placement with ridge augmentation in maxillary anterior region [11]. Compared with the traditional protocol, no delay was necessary for bone healing, resolution of inflammation, and soft tissue recovery for immediate implant placement. Although immediate implant placement reduces the number of surgical procedures, it may increase the difficulty of achieving primary stability. This may be one of the procedural drawback which can be overcome by engaging the apical bone on palatal side. If an implant is to be placed in the position of the extraction socket because of pathological tooth migration and preexisting malalignment, a careful preoperative assessment of dimensions and topography of the surgical site is necessary. A surgical template should be properly constructed to assist in implant placement [12]. An implant not placed exactly in the extraction socket would invariably result in a gap between part of the implant and the socket wall, unless a larger implant and/or grafting materials are used. A horizontal or vertical bony defect around an implant may be a complication detected during stage II surgery at bone-implant interface. It may be due to - direct trauma to the bone or an abuse to the periosteum decreasing vascularity, decreased bone density, improperly inclined implant, excessive torque while implant insertion, untreated bony defect, thin alveolar crest, dehiscence during healing, perforation of the mucoperiosteum, postoperative infection, over loading by the temporary prosthesis, bad oral hygiene and habits. These bony defects are difficult to identify since the patients are asymptomatic. Hence the crestal bone-implant interface should always be examined radiographically. If a bone defect is suspected, it is recommended to incise and elevate a flap to directly evaluate the size of the defect after curetting any epithelial tissue present. Treatment will differ based on the type and extent of bone loss. A vertical defect of less than 2 mm can be managed by horizontal osteoplasty, without compromising the restorations or the cosmetic result, vertical defect of more than 2 mm involving less than half of the implant, autologous bone may be grafted. When the bone loss is greater than 25% of the circumference of the implant, grafting

with a membrane should be done. In small horizontal defect, apical repositioning of the soft tissues will be performed with cleaning of the exposed threads to avoid plaque buildup. Larger horizontal defect, a graft of autologous bone will be performed and a membrane positioned after accurate curettage of the area. Overall immediate implant is advantageous treatment option except few discussed complications and drawbacks along with cost and patient cooperation, but with proper surgical techniques and postoperative maintenance both by dentist and patient the long term success is guaranteed. [13]. To achieve predictable esthetic results with immediate implant placement, it is important to understand the relationship between the gingival margin, topography of crestal bone, and location of the implant. In the present situation, the implant was placed, with the implant body supporting the extraction socket, at a depth which allowed the preservation of crestal bone to support the buccal gingival tissue and interdental papillae [14]. By placement of immediate implant we had reduced the surgical intervention, boosted the patient's psychology as well as achieved all advantages. Although immediate implant placement offers many advantages, other options, such as extraction with residual ridge preservation and delayed implant placement, SST should be considered when the existing clinical condition does not allow an esthetic outcome to be achieved with this technique.

Conclusion

Clinicians can choose from a wide variety of treatment options, techniques, and materials. The choice of the treatment protocol depends primarily on 2 considerations: the experience, knowledge, and cooperation of the clinicians involved, and the expectations of the patient coupled with the understanding that excellent results require time. Immediate implant placement not only reduces total number of surgical interventions and total time of treatment but also yields higher patient satisfaction.

Acknowledgement

Dr. A. K. Verma, HOD, Department of Prosthodontics, CPGIDSH, Lucknow

References

1. Lazzara RJ (1989) Immediate implant placement into extraction sites:

surgical and restorative advantages. *Int J Periodontics Restorative Dent* 9: 332-343. [Link: https://goo.gl/mFr42W](https://goo.gl/mFr42W)

2. Palmer RM, Palmer PJ, Baker P (2006) Immediate and early replacement implants and restorations. *Dent Update* 33: 262-264. [Link: https://goo.gl/ooGMY5](https://goo.gl/ooGMY5)

3. Becker BE, Becker W, Ricci A, Geurs NA (1998) Prospective clinical trial of endosseous screw-shaped implants placed at the time of tooth extraction without augmentation. *J Periodontol* 69: 920-926. [Link: https://goo.gl/d9MMjC](https://goo.gl/d9MMjC)

4. Polizzi G, Grunder U, Goene R, Hatano N, Henry P, et al. (2000) Immediate and delayed implant placement into extraction sockets: a 5-year report. *Clin Implant Dent Relat Res* 2: 93-99. [Link: https://goo.gl/c4df50](https://goo.gl/c4df50)

5. Wagenberg B, Froum SJ (2006) A retrospective study of 1925 consecutively placed immediate implants from 1988 to 2004. *Int J Oral Maxillofac Implants* 21: 71-80. [Link: https://goo.gl/PXMxQC](https://goo.gl/PXMxQC)

6. Sclar AG (2004) Strategies for management of single-tooth extraction sites in aesthetic implant therapy. *J Oral Maxillofac Surg* 62: 90-105. [Link: https://goo.gl/P1aVbn](https://goo.gl/P1aVbn)

7. Belsler UC, Schmid B, Higginbottom F, Buser D (2004) Outcome analysis of implant restorations located in the anterior maxilla: a review of the recent literature. *Int J Oral Maxillofac Implants* 19: 30-42. [Link: https://goo.gl/6hsPj](https://goo.gl/6hsPj)

8. Quirynen M, Van Assche N, Botticelli D, Berglundh T (2007) How does the timing of implant placement to extraction affect outcome? *Int J Oral Maxillofac Implants* 22: 203-223. [Link: https://goo.gl/Qea00A](https://goo.gl/Qea00A)

9. Schwartz-Arad D, Chaushu G (1997) Placement of implants into fresh extraction sites: 4 to 7 years retrospective evaluation of 95 immediate implants. *J Periodontol* 68: 1110-1116. [Link: https://goo.gl/J1fnOe](https://goo.gl/J1fnOe)

10. Saeidi Pour R, Zuhr O, Hürzeler M, Prandtner O, Rafael CF, et al. (2017) Clinical Benefits of the Immediate Implant Socket Shield Technique. *J Esthet Restor Dent* 29: 93-101. [Link: https://goo.gl/Ka9BEn](https://goo.gl/Ka9BEn)

11. Jun-Beom Park (2010) Restoration of the maxillary anterior tooth using immediate implantation with simultaneous ridge augmentation. *Indian J Dent Res* 21: 454-456. [Link: https://goo.gl/fw0mbq](https://goo.gl/fw0mbq)

12. Fernandes A (2007) Implantology 101. *Dent Today* 26: 100-104. [Link: https://goo.gl/bnd5d1](https://goo.gl/bnd5d1)

13. Frederick Chu CS, Adam Siu SC, Deng FL, Chow TW (2007) The use of immediate implant placement for the replacement of a periodontally involved malaligned lateral incisor: A clinical report. *J Prosthet Dent* 98: 423-428. [Link: https://goo.gl/nlRorz](https://goo.gl/nlRorz)

14. Annibali S, Ripari M, La Monaca G, Tonoli F, Cristalli MP (2008) Local complications in dental implant surgery: prevention and treatment. *Oral Implantol (Rome)* 1: 21-33. [Link: https://goo.gl/ujLkIO](https://goo.gl/ujLkIO)