



Clinical Group

Global Journal of Medical and Clinical Case Reports

ISSN: 2455-5282

DOI

CC BY

L Ray Matthews^{1*}, Yusuf Ahmed², Omar Danner¹, Carolyn Moore¹, Carl Lokko¹, Jonathan Nguyen¹, Keren Bashan-Gilzenrat¹, Diane Dennis-Griggs¹, Nekelisha Prayor¹, Peter Rhee⁴, Ed Childs¹, Kenneth Wilson³

¹Morehouse School of Medicine, Atlanta, GA, USA

²Sidra Medical and Research Center, Doha, Saudi Arabia

³Michigan State University College of Human Medicine, East Lansing, MI, USA

⁴Grady Memorial Hospital, Atlanta, GA, USA

Dates: Received: 01 April, 2017; Accepted: 06 April, 2017; Published: 07 April, 2017

*Corresponding author: L Ray Matthews, Morehouse School of Medicine, Department of Surgery, 720 Westview Drive, Atlanta, USA, Tel: (404)616-1415; Fax: (404)616-1417; E-mail: lemattthews@msm.edu ; rmatt63@yahoo.com

<https://www.peertechz.com>

Case Report

High Dose Vitamin D, Digoxin, and BiDil Reverse Congestive Heart Failure in a Critically ILL Trauma Patient and a Severely Obese Male Patient

Abstract

Presently, the prevalence of congestive heart failure in the United States is 6.5 million people. We report two cases of severe congestive heart failure patients with a very poor prognosis, treated successfully with a combination of high dose vitamin D, digoxin, and BiDil (Matthews' Two Inotrope Protocol). Further studies are needed to fully appreciate the overall healthcare changes associated with this simple drug therapy.

Introduction

According to the Centers for Medicaid/Medicare, the prevalence of congestive heart failure (CHF) in the United States today is 6.5 million people, and is projected to be greater than 8 million people by 2030 [1]. Re-hospitalization for CHF within 30 days of discharge is 27% [2]. Total cost for treating congestive heart failure in the United States is \$115.4 billion annually [3].

Congestive heart failure is a complex, debilitating disease, that require at least two inotropes (vitamin D, digoxin) to treat the severe pump failure and a very powerful anti-inflammatory agent (vitamin D) to treat the chronic inflammation associated with CHF. Vitamin D is a steroid hormone that increases calcium absorption by the heart. Thus, this makes vitamin D a cheap, inexpensive inotrope, plus one of the strongest anti-inflammatory and anti-oxidant agents in the human body. Vitamin D and digoxin work synergistically on the human heart to increase calcium absorption (cardiac contractility) with the end result being an increased ejection fraction (EF). Positive clinical results are usually seen in 4-6 weeks (increased ejection fraction and increased exercise tolerance).

BiDil (isosorbide dinitrate 20 mg/hydralazine 37.5 mg) is a combination medication that has reduced the risk of death by 43% and the risk of re-hospitalization by 39% in African Americans [4].

Vitamin D, digoxin, and Lasix combination works equally as well in the Caucasian population as the vitamin D, digoxin, BiDil, Lasix combination in African Americans in treating CHF. The only difference in the two groups is the addition of BiDil in the African American population. We lowered our overall mortality rate at a Level I trauma center to 3% in 2015 and reduced our myocardial infarction/stroke rate by 50% using high dose vitamin D. Vitamin D levels less than 18 ng/ml increases all-cause mortality rate by 30% [5].

We report two cases of patient with CHF with different pathophysiology's who were successfully treated with vitamin D, digoxin, and BiDil with a 40-50% increase in ejection fraction (EF) and no re-hospitalizations for 2 years and 12 years, respectively.

Case 1

Patient is a 54-year-old African American male brought to the Emergency Room by ambulance after a ground level fall. His past medical history was significant for hypertension, alcohol abuse, and an unknown psychiatric disorder.

On physical exam, his vital signs were as follows: temperature 36.8; blood pressure 135/83; heart rate 93; respiratory rate 20; and oxygen saturation 100% on room air.

He had a 1-cm laceration with minimal blood over the occipital part of his scalp. His pupils were 3-4 mm and reactive to light. His Glasgow Coma Scale score (GCS) was 14. The FAST exam and the rest of his physical exam was unremarkable.

Labs were as follows: white blood cell count 3.6; hemoglobin 12.0; platelet count 114; vitamin D level on admission 33.3 ng/ml. His electrolytes were all normal. A CT scan of the head revealed a stable subdural hematoma and intra parenchymal hemorrhage. CT scan of the chest, abdomen, and pelvis were negative.

Patient was admitted to the surgical intensive care unit (SICU) for neurological monitoring. Patient went into DT's for the next 5 days which was treated chemically and resolved. On hospital day #6, he had a GCS of 15. Patient became lethargic on hospital day #8, a repeat CT scan of the head showed an enlarging/expanding hematoma (Figure 1). He was taken to the operating room by Neurosurgery for a craniectomy and evacuation of hematoma which he tolerated well.

On hospital day # 17, patient had a ST segment elevation myocardial infarction (Figure 2). EKG showed an anterior ST segment elevation, prolonged QT interval, and nonspecific T-wave abnormality in the inferior leads. Troponins were 0.27, 0.30, and 0.71, respectively (normal less than 0.04 ng/ml). C-reactive protein was elevated at 4.29 (0.00-0.50 ng/ml). An echocardiogram showed an EF of 25-30%, elevated right ventricle pressure at 50-60 mm Hg, and moderate tricuspid regurgitation. The rest of the patient's labs were unremarkable---except for an x-ray which showed bilateral pulmonary edema (Figure 3).

On hospital day #18, patient went into cardiac arrest requiring CPR for 20 minutes at 1:00 am, cardiac arrest again at 4:00 am requiring CPR for 15 minutes, and cardiac arrest a third time that night requiring advanced ACLS. He then went into ventricular tachycardia requiring amiodarone and defibrillation which he responded successfully.

On hospital day #26, patient had a repeat echocardiogram which showed continuing CHF and an EF of 25-30%. Patient was unable to be weaned off the ventilator and continued to show failure to thrive.

On hospital day #26, patient was re-dosed with high dose vitamin D (50,000 IU) down his nasogastric tube, loaded with IV digoxin, and started on BiDil down his nasogastric tube which he tolerated well. Patient had no adverse reactions to any of the three medications.

A repeat echocardiogram on hospital day #56 (30 days later) showed an improved EF of 45-50%, moderately dilated right ventricle, and mildly reduced left ventricle systolic function.

Patient's condition improved rapidly after the three-medication combination was started. He was transferred to the surgical floor for in-patient rehab which he tolerated well. His GSC was 15. He was discharged to a nursing home without any restrictions. He has not been re-admitted for CHF in 2 years since his discharge.

Case 2

Patient is a 45-year-old morbidly obese African American male (5'8", 370 pounds, BMI 56.3) who developed a 2

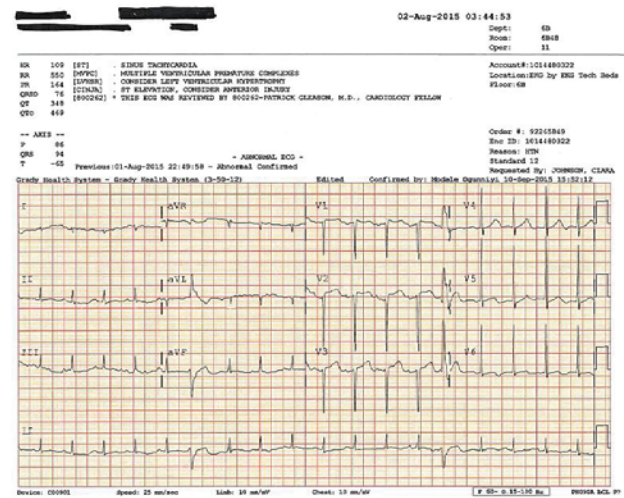


Figure 2: Patient's EKG after myocardial infarction and coding x 3 in one night requiring CPR and defibrillation.

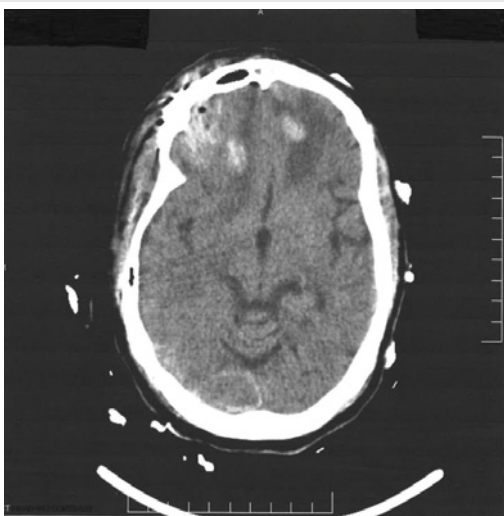


Figure 1: CT scan of the head shows an expanding right subdural hematoma and intraparenchymal hemorrhage.

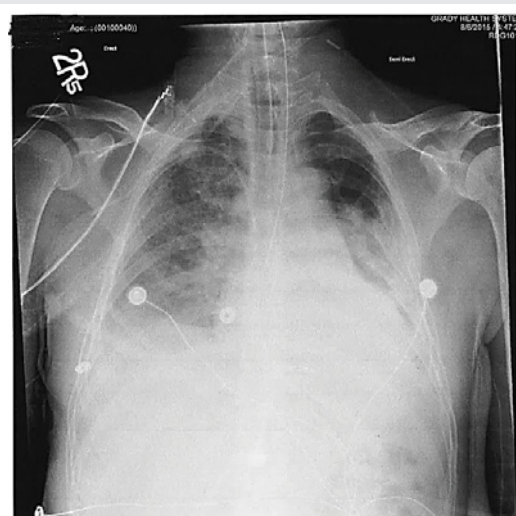


Figure 3: Patient's chest x-ray after myocardial infarction and 3 codes shows congestive heart failure and pulmonary edema.

month history of shortness of breath, dull chest discomfort, paroxysmal nocturnal dyspnea, and orthopnea (Figures 4, 5).

He was placed on disability at his job as an assembly line worker. Patient was unable to bend/lift, which his job required, without getting short of breath and feeling like he was about to pass out. He was initially diagnosed as having asthma/bronchial problems. His symptoms got progressively worse until he noticed bilateral ankle swelling and weight gain.

His past medical history was significant only for removal of a lipoma from his back. He denied a history of smoking or drug use. He did not have any allergies and was not taking any medications.

His family history was significant for severe cardiac disease. His father died at 38 years old from a massive myocardial infarction. A brother died at 47 also from a massive myocardial infarction. No male relative on his father's side of the family had lived to the age of 50 years old. His physical exam was unremarkable except for morbid obesity. His blood pressure was 110/70. His heart rate was 85.

EKG in August 2005 showed normal sinus rhythm, T wave abnormality and possible inferolateral ischemia. An echocardiogram revealed an EF of 30%. On August 19, 2005, patient had a cardiac catheterization which confirmed an EF of 30%, a dilated cardiomyopathy, elevated right ventricle pressure of 84/11 mm Hg, a pulmonary artery pressure of 50/18 mm Hg, and normal coronary arteries.

He was diagnosed with severe dilated cardiomyopathy, moderate pulmonary hypertension, and normal coronary arteries. The patient was referred to the Kirkland Clinic in Birmingham, Alabama for evaluation of cardiac transplantation. He was placed on the cardiac transplant list after his evaluation and continued on disability.



Figure 4: Patient is now a 57-year-old male, 12 years after being diagnosed with dilated cardiomyopathy, congestive heart failure (EF initially 30%, now 50%), and pulmonary hypertension. Using Matthews' Two Inotrope Protocol, he is the first male on his father's side of the family to live past 50 years old. Patient is an assistant Scout Master (produced 8 Eagle Scouts past 10 years), deacon in his church, works full time as a deputy sheriff jailer, married with a loving wife, and raised 3 children. He has no physical restrictions after being removed off the Kirkland Heart Transplant list 12 years ago.

After being placed on the transplant list, the patient was started on high dose vitamin D and BiDil (a new medication in 2005). Patient's symptoms began to improve over the next 2-6 weeks with less shortness of breath and improved exercise tolerance (walking distance). He was followed closely by his local cardiologist and the Kirkland Clinic. A repeat echocardiogram on February 13, 2008, showed an improved EF of 50-55%, trace mitral regurgitation, and a mildly dilated left ventricle.

The patient was removed off the cardiac transplant list and disability list. He returned to work full time without any physical restrictions. He presently works full time as a sheriff deputy jailer, a tax paying citizen, not requiring any government assistance. The patient is very active in his community where he is assistant Scout Master in Boy Scouts of America. His troop has produced 8 Eagle Scouts over the last 10 years. All have graduated or attending college at the present time. The patient is also a deacon at his church and has raised 3 children with his loving wife.

In 2017, he is now 57 years old and the first male on his father's side to live past the age of 50 years old. He has not had any hospitalizations for his pulmonary hypertension/congestive heart failure since 2005 (12 years ago). He continues to take high dose vitamin D and BiDil for his CHF. He sees his local cardiologist regularly, does not smoke; however, he still struggles with weight management.

Discussion

CMS has mandated that the 5,000 plus hospital in the United States reduce the 30-day hospital re-admissions rate for patients with congestive heart failure below 20%. Most chronic diseases of aging including cardiac diseases and congestive heart failure are associated with chronic inflammation and oxygen free radical formation. Half of patients with acute myocardial infarctions have normal cholesterols [6].

Vitamin D is a pleotropic, steroid hormone (not a true vitamin) which controls 3,000 out of 30,000 genes in the human body, including the immune response and the inflammatory response systems. This alone makes vitamin D one of the most powerful chemicals in the human body. It controls 10% of the human DNA.

Almost all patients with congestive heart failure are vitamin D deficient [7]. Severe vitamin D deficiency is associated with worsening prognosis in CHF patients. Vitamin D levels less than 18 ng/ml increases the all-cause mortality rate by 30%. One million new patients are diagnosed with congestive heart failure annually. This ever-growing problem can only be managed when vitamin D deficiency is fully understood in the pathogenesis of congestive heart failure:

1. Vitamin D-deficiency promotes activation of the renin-angiotensin –aldosterone system which contributes to salt and water retention that is seen in congestive heart failure which may make CHF patients more difficult to diuresis [8, 9].

2. Vitamin D-deficiency reduces calcium, phosphorus, magnesium, and iron absorption. Calcium is a cheap inotrope involved in increasing cardiac contractility. Phosphorus is used to make ATP which is the energy fuel for cardiac mitochondria. Magnesium is used to reduce arrhythmias and is involved in over 300 different reactions in the human body. Iron increases oxygen transport reducing myocardial oxygen demand on the heart.
3. Vitamin D-deficiency plays a role in cardiomyocyte stiffness or reduced relaxation.
4. Vitamin D-deficiency promotes cardiac hypertrophy
5. Vitamin D-deficiency results in a pro-inflammatory and pro-coagulant state in blood vessels and tissues.
6. Vitamin D-deficiency promotes endothelial dysfunction and decreased nitric oxide production which produces vasoconstriction of blood vessels.
7. Vitamin D-deficiency lowers exercise capacity and increases frailty in elderly patients.
8. Vitamin D-deficiency decreases Heat Shock Protein (HSP) which help cardiac proteins maintain their 3-D shape when under stress from ischemia, hyperthermia, hypothermia, hyperglycemia, hypoglycemia, or any other adverse condition. Cardiac proteins do not function/contract when they lose their 3-D shape.
9. Vitamin D-deficiency inhibits angiogenesis (new blood vessel formation) after cardiac injury/damage/death.
10. Vitamin D-deficiency inhibits apoptosis (programmed cell death).
11. Vitamin D-deficiency promotes free oxygen radical production which damages the cardiac cell membranes, cardiac DNA, and cardiac mitochondria which is the powerhouse of each cardiac cell.

Vitamin D and digoxin are both powerful inotropes that work synergistically in severe pump failure/CHF patients to increase cardiac contractility (i.e., EF). No adverse medication reactions were noted using vitamin D, digoxin, BiDil, and

Lasix combination. Readmission rate for our trauma patients with congestive heart failure remains low. Most report a better quality of life. Some have returned to physical activities abandoned years ago due to reduced exercise capacity. Others report less depression and more independence with renewed energy. The largest reward other than a better quality of life has been that many are able to return to some form of employment without government assistance.

Conclusion

We conclude that a combination of vitamin D, digoxin, BiDil, and Lasix improves congestive heart failure patient's quality of life, results in fewer hospital readmissions, and reduce overall hospital costs for the care of patients with CHF. Severe congestive heart failure (CHF) require at least two inotropes to reverse the downward spiral of CHF patients. Further studies are needed to fully appreciate the overall healthcare changes associated with this simple drug therapy.

References

1. Benjamin EJ (2017) *Circulation* 135.
2. Desai AS (2012) *Circulation*. 501-506.
3. Voigt J (2014) *Clinical Cardiology* 37: 312-321.
4. BiDil Clinical Trial Data. [Link: https://goo.gl/TdAEI0](https://goo.gl/TdAEI0)
5. Matthews LR, Ahmed Y, Wilson KL, Griggs DD, Danner OK (2012) Worsening Severity of Vitamin D Deficiency is Associated with Increased Length of Stay, Surgical Intensive Care Unit Cost, and Mortality Rate in Surgical Intensive Care Unit Patients. *The American Journal of Surgery*. 204: 37-43. [Link: https://goo.gl/VjmXit](https://goo.gl/VjmXit)
6. Matthews, LR (2015) Daily High Dose Vitamin D Supplementation Reduces the Incidence of Myocardial Infarctions in Surgical Intensive Care Unit Patients. *J Clin Exp Cardiol* 6:10. [Link: https://goo.gl/dmc40W](https://goo.gl/dmc40W)
7. Pourjabbar A1, Dwivedi G, Haddad H (2013) The Role of Vitamin D In Chronic Heart Failure. *Curr Opin Cardiol* 28: 216-222. [Link: https://goo.gl/lxZB3T](https://goo.gl/lxZB3T)
8. Agarwal M, Phan A, Willix R Jr, Barber M, Schwarz ER (2011) Is Vitamin D Deficiency Associated with Heart Failure? A Review of Current Evidence. *J Cardiovasc Pharmacol Ther* 16: 354-363. [Link: https://goo.gl/V15z2m](https://goo.gl/V15z2m)
9. Pilz S1, Tomaschitz A, Drechsler C, Dekker JM, März W (2010) Vitamin D Deficiency and Myocardial Diseases. *Mol Nutr Food Res* 54: 1103-1113. [Link: https://goo.gl/L4rdVg](https://goo.gl/L4rdVg)