



Joshua Gurberg^{1*}, John Paul Moxham², and Jeffrey P Ludemann³

¹The University of British Columbia, Division of Otolaryngology, Diamond Health Care Centre, 4th Floor, 2775 Laurel Street, Vancouver, British Columbia, Canada

²Children's Hospital, Vancouver, British Columbia, Canada

³Children's Hospital, Vancouver, British Columbia, Canada

Dates: Received: 10 April, 2017; Accepted: 04 May, 2017; Published: 06 May, 2017

***Corresponding author:** Joshua Gurberg, University of British Columbia, Division of Otolaryngology, Diamond Health Care Centre, 4th Floor, 2775 Laurel Street, Vancouver, British Columbia, Canada, E-mail: Joshua.gurberg@gmail.com

Keywords: Pediatric; Pediatrics; First branchial cleft; Congenital anomalies; Facial nerve; Tympanic membrane duplication, Tympanic membrane triplication

<https://www.peertechz.com>

Case Report

First Branchial Cleft Anomalies: Managing Various Cervico-Facial Anomalies and Otologic Malformations at a large Canadian Referral Centre

Abstract

Background: Branchial cleft anomalies account for approximately 17% of pediatric neck masses and 30% of all congenital neck lesions; of these, less than 1% involve the first branchial cleft. We report several novel otologic malformations encountered in children with first branchial cleft anomalies; as well as our surgical techniques and outcomes.

Methods: We conducted a retrospective chart review of all patients consecutively referred to the senior authors at a tertiary-care Pediatric Otolaryngology clinic for first branchial cleft anomalies over a 14-year period. Patients underwent computerized tomography scan with contrast, otoscopy plus tympanic microsurgery, when indicated (29%), methylene blue mapping of the cutaneous opening, when present (57%), intra-operative facial nerve monitoring, and anterograde or retrograde facial nerve dissection, when necessary (86%).

Results: Seven patients presented with first branchial cleft anomalies, at an average age of 3.9 years. Five of seven patients (71%) presented with cervico-facial infection. Four of the anomalies were sinuses, 2 were cysts and 1 was a fistula. Two patients had a classic myringal web. One patient had a large posterior intratympanic keratoma, partial myringal duplication, and wax-pocket; while another patient had external auditory canal triplication and a small intratympanic keratoma. In 6 cases (86%) there was distortion of anatomical landmarks and retrograde facial nerve dissection was therefore employed. In one patient, no branches of the facial nerve were identified during excision. In two patients, re-anastomosis of a small distal branch of the facial nerve was performed. Five patients (71%) experienced transient facial nerve weakness. However, with a mean length of follow-up of 7.5 years, no permanent facial nerve weakness, recurrence, or hearing loss has been identified.

Conclusions: We present several novel otologic first branchial cleft findings, as well as the experience of a two-surgeon team using methylene blue mapping plus monitored and primarily retrograde facial nerve dissection. This approach appears relatively safe and effective in children with these highly variable anomalies.

Abbreviations

FBCA: First branchial cleft anomaly; CT: Computed tomography

Background

The branchial arches appear as 4 paired arches of tissue at 4 weeks gestational age. The branchial clefts are composed of ectoderm, the pouches are formed of endoderm, while the mesenchyme of the arch will form an artery, nerve, cartilaginous bar, and muscle. With regards to the first branchial arch, the specific structures that develop are the maxillary

artery, trigeminal nerve, muscles of mastication, mylohyoid, anterior belly of digastric muscle, tensor tympani, tensor veli palatini, malleus, incus, and a portion of the mandible. The first branchial cleft forms the external auditory canal and the first branchial pouch forms the Eustachian tube, middle ear cavity, and mastoid air cells. Formation of these structures occurs early and rapidly in gestation; as such this process is predisposed to error and resultant congenital anomalies.

Branchial cleft malformations account for approximately 17% of neck masses and 30% of all congenital neck lesions in children, second only to thyroglossal duct cysts [1]. First branchial cleft anomalies (FBCA) account for only 1% of

all branchial cleft malformations; however, making them exceedingly rare [1]. They tend to present as a cyst, sinus, or fistula occurring in a region known as Pochet's triangle, which is bounded by the external auditory canal superiorly, the mental region anteriorly, and the hyoid bone inferiorly [2]. Symptoms include drainage from a pit-like depression in this region, submandibular adenitis, a parotid mass, or otorrhea. 10% of lesions are also associated with an asymptomatic membranous attachment between the tympanic membrane and floor of the external auditory canal [2,3]. These lesions are not to be confused with pre-auricular sinuses, which by definition are superficial to the first branchial cleft (and were excluded from this study).

Historically, FBCA have been divided into type I and type II lesions by means of a histopathological classification system [1]. Type I lesions are made up of ectoderm exclusively, while type II lesions contain ectoderm and mesoderm [1]. Several authors have reported on the relationship of these types of lesions to the facial nerve, with type I tending to be superficial and type II tending to be deep to the nerve [1,3,4]. It has been recognized however that, in many cases, these anomalies do not abide to these classifications nor anatomical relationships [4].

Our objective was to describe our surgical approach and outcomes with these rare and challenging congenital lesions as well as report on several novel associated otologic malformations encountered in our clinical experience. We have also reviewed the relevant literature.

Methods

Patients

After obtaining IRB approval, the charts of all patients consecutively referred to a two-surgeon team over a 14-year period for FBCA were retrospectively reviewed. 7 patients were identified; 6 female and 1 male. The mean age at presentation was 3.9 years. 5 patients presented with active infection. No associated craniofacial anomalies or syndromes were identified and there was no pre-operative facial nerve dysfunction. Six patients were imaged with computed tomography scan (some after initial ultrasound) and one patient had an MRI due to parent refusal. Figures 1,2 are illustrative.

Surgical equipment and technique

Box 1. Materials:

- Operating Microscope
- 3 Chip Camera and Telescopes (long zero and thirty degree, 3mm and/or 4mm)
- Myringotomy Tray
- 24 and 26 guage plastic angiocatheter
- Methylene Blue
- Facial Nerve Monitor, Facial Nerve Probe

- 1% Xylocaine with Epinephrine
- 67 Beaver Blade
- Guthrie double skin hooks
- Ragnell retractors
- Forceps: small bipolar (Silverglide), Bishop, MacAdoo, Jacobsen Hemostats
- Fine Tenotomy and Iris Scissors
- Peanuts with Epinephrine
- Bacitracin irrigation
- Marcaine 0.25% with epinephrine

Anesthetic induction was performed by the anesthetist using total intravenous anesthesia, which is the standard of practice at our center, using only short acting paralytic agents. The ears were then examined under the microscope. Any cerumen or granulation tissue was carefully debrided; intra-tympanic keratomas and/or wax pockets were carefully

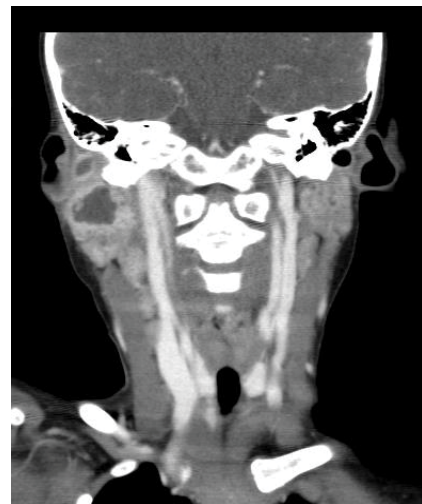


Figure 1: Computed tomography scan with contrast demonstrating a bi-lobed right type II first branchial cleft anomaly.

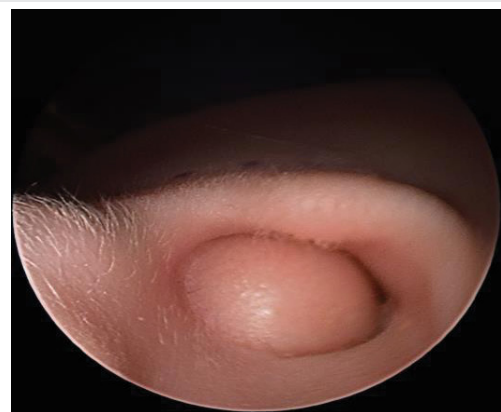


Figure 2: Endoscopic image of the right external auditory canal (tragus seen anteriorly) demonstrating the cutaneous component of the bi-lobed FBCA described in figure 1.

unroofed. Over the course of this series, when the ear canal caliber allowed, an endoscopic approach to the tympanic exam and microsurgery became more commonly employed. High definition endoscopic images were taken of notable findings, using a 0 degree endoscope and 3 chip camera. When an isolated classic myringal web was discovered (14% of cases), no further surgical intervention was performed.

A modified Blair incision was marked, with the cervical limb lying in a natural skin crease, then injected with Marcaine or Xylocaine with epinephrine. When a facial cutaneous opening was present (and no evidence of G6PD deficiency anemia) methylene blue was instilled, using a 24 or 26 gauge plastic angiocatheter, as previously described [5]. If purulent fluid was milked from the tract just prior instillation of methylene blue, then this was sent for culture and sensitivity. The facial nerve monitor was then applied and the patient was prepared and draped with the ipsilateral hemiface exposed. Superficial skin flaps were raised taking great care to identify and avoid the branches of the facial nerve. When possible, the main trunk of the facial nerve was identified at the depth of the posterior belly of the digastric muscle by blunt dissection and followed forward into the parotid gland prior to dissecting the inflammatory mass. When there is distortion of landmarks as a result of the lesion, a small, distal branch of the facial nerve was identified and traced back in retrograde fashion to identify other branches according to the method described by Anjum et al [6]. The mass (and its stalk) was then dissected bluntly using Jacobson forceps and facial nerve probe guidance. Division of subcutaneous tissue was performed in layers using micro-bipolar cautery, but only a facial nerve stimulator was used to verify safety. The entire cyst and epithelial component of the fistula tract was removed; but in certain cases, in order to minimize the risk of injury to the facial nerve, the cartilaginous sleeve component of the lesion was left in situ. Complete hemostasis was achieved with epinephrine soaked peanuts and bipolar cautery.

Before closure, all isolated branches of the facial nerve were stimulated to verify functionality. The site was then irrigated with a saline and bacitracin solution. The superficial parotid fascia was closed using 4-0 PDS or Vicryl in order to prevent Grey's syndrome. The skin was then closed in layers with 4-0 PDS or Vicryl for the dermis and a 6-0 fast-gut running stitch for the epidermis. A Penrose drain was typically left in place at the inferior aspect of the wound under a light pressure dressing and removed the next morning.

Results

Operative approach

In 6 cases (86%) the lesion caused significant distortion of anatomical landmarks, thereby necessitating retrograde facial nerve dissection. 3 lesions were superficial to the facial nerve, 2 were deep, 1 was partly superficial and partly deep to the facial nerve; and in 1 case the nerve was not visualized.

Surgical outcomes

The epithelial portion of the lesion was completely resected in all cases. In 2 cases a distal branch of the facial nerve

was transected; in 1 of these cases this was planned in order to deliver the mass. In these cases, we performed primary re-anastomosis of the nerve, without tension, under the microscope, using simple interrupted 8-0 Prolene.

Five patients (71%) experienced transient facial nerve weakness. However, all patients recovered full facial nerve function with a mean time to recovery of 2 months. There was one mild, late wound infection, which was managed with oral antibiotics. After 7.5 years mean follow-up, there have been no recurrences.

Otologic malformations

Two patients had a classic myringal web (Figure 3); these were not incised or excised. One patient had a large posterior intratympanic keratoma and a partial anterior myringal duplication, creating a potential space which was filled with wax; both lesions were completely removed after 45 minutes of careful microsurgery. Finally, another patient displayed external auditory canal triplication (figure 4) and a small intratympanic keratoma, which was also removed. No tympanic perforations were created. All Patients with complex otologic malformations or any operative manipulation (4 patients) had post-operative audiograms and all were within normal limits.

Discussion

Several other case series have been reported in the scientific literature (Tables 1,2). In 1996, Agaton and colleagues described their series of 35 primarily female patients with a mean age of 23 years [7]. All lesions were excised using a wide transverse cervicotomy incision. At 2 years clinical follow up, a 4% recurrence rate was seen with 0% facial nerve paralysis. Five case series have been published on the excision of type I and II branchial cleft cysts using a superficial parotidectomy approach. Stokroos and colleagues approached FBCA via the standard parotidectomy incision and, depending on the relation of the fistula tract to the facial nerve, performed simple excision vs. superficial parotidectomy [8]. Nicollas et al., Solares et al.,

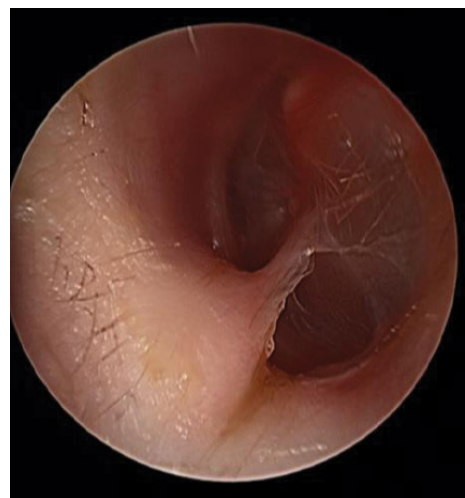

Figure 3: Endoscopic image of the left tympanic membrane demonstrating a Myringal web. A cord of epithelial tissue extends from the floor of the external auditory canal to the umbo of the left ear.

and del Poro et al. performed superficial parotidectomy on all subjects with or without facial nerve monitoring[4,9,10]. In the 105 patients treated by superficial parotidectomy in these studies, recurrence rates ranged from 0–10% and facial nerve paralysis complicated 0–5.6% of cases (Table 2).

In 2012, 2 reports were published detailing the results of a unique surgical approach controlling the sinus from within the cyst lumen under the operating microscope and employing retrograde facial nerve dissection when needed. No blue dye mapping or facial nerve monitoring was employed [11,12]. The 23 patients treated in this fashion experienced no facial nerve paralysis or lesion recurrence [11,12].

In our series, we utilized the novel surgical approach of a mainly retrograde facial nerve dissection (with facial nerve monitoring) plus, when possible, initial methylene blue demarcation to achieve results comparable to other

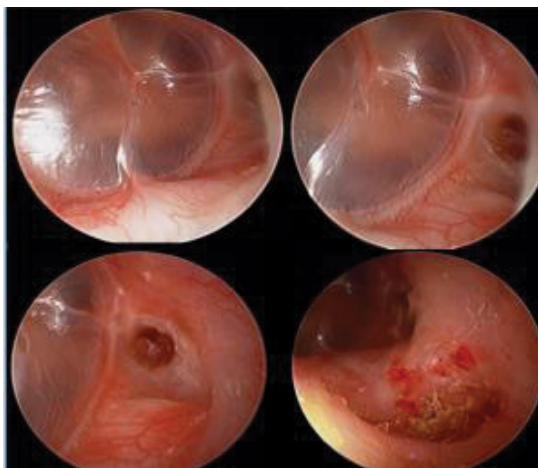


Figure 4: Myringal triPLICATION. Endoscopic images of the right ear. A small pit-like structure filled with cerumen can be seen anterior to the fibrous annulus. Another pit is visualized further lateral within the floor of the external auditory canal.

Table 1: Literature review: Patient characteristics.

Study	Number of Patients	Mean age (yrs)	Sex ratio (M:F)	type (1:2)	Active infection	Otologic Malformation
Gurberg et al.2014	7	3.9	1 : 6	0 : 7	5/7	As described
Chan et al. 2012	8	14.2	4 : 4	4 : 4	8/8	n/a
Nicollas et al. 2000	20	6.5	3 : 17	n/a	n/a	myringeal web
Agaton et al. 1996	35	23.6	7 : 28	n/a	n/a	n/a
Arndal et al. 1996	3	16	2 : 1	2 : 1	1/3	0
Chen et al. 2012	15	17	6 : 9	n/a	15/15	n/a
Kumar et al. 2013	4	29.5	2 : 2	n/a	4/4	n/a
Ikarashi et al. 1996	3	4.6	3 : 0	n/a	2/3	0
Del Pero et al. 2006	18	5.23	6 : 12	n/a	10/18	myringeal web
wittekindt et al. 2001	3	3.25	2 : 1	1 : 2	1/3	eac duplication
Bajaj et al. 2011	15	7.5	8 : 7	n/a	7/15	EAC duplication
Stokroos et al. 2000	18	24.4	9 : 9	12 : 6	3/18	n/a
Triglia et al. 1998	39	6	12 : 27	n/a	12/39	myringeal web
Leu et al. 1998	12	19.6	6 : 6	4 : 8	n/a	n/a
Solares et al. 2003	10	9	4 : 6	n/a	2/10	n/a

Table 2: Literature review: Recurrence and complications.

Study	follow up (yrs)	FN Paresis	FN Paralysis	Other cx	Recurrence
Gurberg et al.2014	6.25	71.4%	0%	1 infection	0%
Chan et al. 2012	1	0%	0%	0	0%
Nicollas et al. 2000	4	0%	0%	0	10%
Agaton et al. 1996	2	5.7%	0%	0	4%
Arndal et al. 1996	1.7	12.5%	0%	0	0%
Chen et al. 2012	6	0%	0%	0	0%
Kumar et al. 2013	n/a	50%	0%	0	n/a
Ikarashi et al. 1996	n/a	33.3%	33.3%	0	n/a
Del Pero et al. 2006	n/a	5.6%	0%	1 painful scar	0%
wittekindt et al. 2001	n/a	33.3%	0%	0	0%
Bajaj et al. 2011	0.5	6.7%	0%	0	0%
Stokroos et al. 2000	10	0%	0%	0	0%
Triglia et al. 1998	3.7	12.8%	5.6%	0	0%
Leu et al. 1998	0.5	0%	0%	0	8.3%
Solares et al. 2003	1	0%	0%	1 infection	0%

published reports. Although five of seven patients experienced transient weakness of a branch of their facial nerve, no patient experienced permanent facial nerve weakness or FBCA recurrence (mean follow-up 7.5 years).

In 210 previously reported cases reviewed, 3 classic myringeal webs and 2 EAC duplications were reported [4,7-11,13-20]. In our case series, the large posterior intratympanic keratoma, partial myringeal duplication (encasing wax), and EAC triPLICATION represent novel FBCA-associated otologic malformations, which to our knowledge have not been previously reported. In both the literature and our series, no postoperative hearing loss has been identified. This is not surprising, as the first branchial arch is not involved in middle ear development. When removing intra-tympanic keratomas or wax pockets (or other lesions which may likely cause conductive hearing loss), careful surgical technique is needed, in order to avoid causing tympanic perforation and traumatic hearing loss.

Conclusion

First branchial cleft anomalies are rare and highly variable lesions, as demonstrated by their unpredictable relationships to the facial nerve and their occasional association with novel otologic malformations. Intratympanic keratomas and partial myringeal duplications (causing wax entrapment) require careful excision, in order to correct conductive hearing loss and also prevent enlargement and subsequent tympanic perforation. In contrast, classic myringeal webs do not require incision or excision.

In our series, monitored, primarily retrograde facial nerve dissection with initial methylene blue demarcation (when applicable) appears relatively safe and effective in children with these highly variable anomalies. Our technique compares favorably with the current literature in terms of completeness

of excision, recurrence rates, and safety. Parents of children with FBCAs should be advised preoperatively, however, regarding the likelihood of temporary facial nerve weakness.

Declarations

Ethics approval and consent to participate: This study was approved by the Children's and Women's Research Ethics Board.

Author's contributions

JG was involved in data collection, data analysis, and manuscript preparation. PM was involved in study design and manuscript preparation. JPL was involved in study design and manuscript preparation.

Acknowledgements

The authors would like to thank Dr. Anali Dadgostar and Ms. Ashley Rose Caufin for assisting in data collection and initial literature review.

References

- Waldhausen JH (2006) Branchial cleft and arch anomalies in children. *Semin Pediatr Surg* 15: 64-69. [Link: https://goo.gl/xnNk5h](https://goo.gl/xnNk5h)
- Maitani T, Pandey A, Dey D, Bhardwaj A, Singh VP (2014) First branchial cleft anomaly: clinical insight into its relevance in otolaryngology with pediatric considerations. *Indian J Otolaryngol Head Neck Surg* 66: 271-276. [Link: https://goo.gl/RvSrYM](https://goo.gl/RvSrYM)
- Nofsinger YC, Tom LW, LaRossa D, Wetmore RF, Handler SD (1997) Periauricular cysts and sinuses. *Laryngoscope* 107: 883-887. [Link: https://goo.gl/II1eQE](https://goo.gl/II1eQE)
- Solares CA, Chan J, Koltai PJ (2003) Anatomical variations of the facial nerve in first branchial cleft anomalies. *Arch Otolaryngol Head Neck Surg* 129: 351-355. [Link: https://goo.gl/jFxEg](https://goo.gl/jFxEg)
- Dickson JM, Riding KH, Ludemann JP (2009) Utility and safety of methylene blue demarcation of preauricular sinuses and branchial sinuses and fistulae in children. *J Otolaryngol Head Neck Surg* 38: 302-310. [Link: https://goo.gl/CSdpWA](https://goo.gl/CSdpWA)
- Anjum K, Revington PJ, Irvine GH (2008) Superficial parotidectomy: antegrade compared with modified retrograde dissections of the facial nerve. *Br J Oral Maxillofac Surg* 46: 433-434. [Link: https://goo.gl/fZj8Ai](https://goo.gl/fZj8Ai)
- Agaton-Bonilla FC, Gay-Escoda C (1996) Diagnosis and treatment of branchial cleft cysts and fistulae. A retrospective study of 183 patients. *Int J Oral Maxillofac Surg* 25: 449-452. [Link: https://goo.gl/WwC3n5](https://goo.gl/WwC3n5)
- Stokroos RJ, Manni JJ (2000) The double auditory meatus—a rare first branchial cleft anomaly: clinical presentation and treatment. *Am J Otol* 21: 837-841. [Link: https://goo.gl/ITqiQj](https://goo.gl/ITqiQj)
- Nicollas R, Guelfucci B, Roman S, Triglia JM (2000) Congenital cysts and fistulas of the neck. *Int J Pediatr Otorhinolaryngol* 55: 117-124. [Link: https://goo.gl/bxf0oU](https://goo.gl/bxf0oU)
- Martinez Del Pero M, Majumdar S, Bateman N, Bull PD (2007) Presentation of first branchial cleft anomalies: the Sheffield experience. *J Laryngol Otol* 121: 455-459. [Link: https://goo.gl/4Uc8EH](https://goo.gl/4Uc8EH)
- Chan KC, Chao WC, Wu CM Surgical management of first branchial cleft anomaly presenting as infected retroauricular mass using a microscopic dissection technique. *Am J Otolaryngol* 33: 20-25. [Link: https://goo.gl/sxfM8Q](https://goo.gl/sxfM8Q)
- Chen Z, Wang Z, Dai C (2010) An effective surgical technique for the excision of first branchial cleft fistula: make-inside-exposed method by tract incision. *Eur Arch Otorhinolaryngol* 267: 267-271. [Link: https://goo.gl/km10BN](https://goo.gl/km10BN)
- Triglia JM, Nicollas R, Ducroz V, Koltai PJ, Garabedian EN (1998) First branchial cleft anomalies: a study of 39 cases and a review of the literature. *Arch Otolaryngol Head Neck Surg* 124: 291-295. [Link: https://goo.gl/HJseUS](https://goo.gl/HJseUS)
- Arndal H, Bonding P (1996) First branchial cleft anomaly. *Clin Otolaryngol Allied Sci* 21: 203-207.
- Cheng J, Elden L (2013) Outcomes in children under 12 months of age undergoing adenotonsillectomy for sleep-disordered breathing. *Laryngoscope* 123: 2281-2284. [Link: https://goo.gl/RP5lnu](https://goo.gl/RP5lnu)
- Kumar R, Sikka K, Sagar P, Kakkur A, Thakar A (2013) First branchial cleft anomalies: avoiding the misdiagnosis. *Indian J Otolaryngol Head Neck Surg* 65: 260-263. [Link: https://goo.gl/G96XRC](https://goo.gl/G96XRC)
- Ikarashi F, Nakano Y, Nonomura N, Kawana M, Okura T (1996) Clinical features of first branchial cleft anomalies. *Am J Otolaryngol* 1996, 17:233-239. [Link: https://goo.gl/Du6txT](https://goo.gl/Du6txT)
- Wittekindt C, Schondorf J, Stennert E, Jungehulsing M (2001) Duplication of the external auditory canal: a report of three cases. *Int J Pediatr Otorhinolaryngol* 58: 179-184. [Link: https://goo.gl/y2ukSK](https://goo.gl/y2ukSK)
- Bajaj Y, Tweedie D, Ifeacho S, Hewitt R, Hartley BE (2011) Surgical technique for excision of first branchial cleft anomalies: how we do it. *Clin Otolaryngol* 36: 371-374. [Link: https://goo.gl/937tsl](https://goo.gl/937tsl)
- Leu YS, Chang KC (1998) First branchial cleft anomalies: report of 12 cases. *Ear Nose Throat J* 77: 832-833. [Link: https://goo.gl/yHFvsw](https://goo.gl/yHFvsw)