



Patricia Ramos<sup>1</sup>, Fernanda Díaz-Sámamo<sup>2</sup> and Enoe Quiñonez<sup>1\*</sup>

<sup>1</sup>Department of Pathology, La Raza National Medical Center, Specialty Hospital, Mexican Institute of Social Security, Calle Seris S/N Azcapotzalco, La Raza, Mexico

<sup>2</sup>La Salle University of Medicine. Calle Benjamín Franklin 47, Cuauhtémoc, Hippodrome Condesa, 06140 Mexico

**Dates:** Received: 08 November, 2016; Accepted: 05 December, 2016; Published: 06 December, 2016

**\*Corresponding author:** Enoe Quiñonez Urrego MD, Department of Pathology, La Raza National Medical Center. Hospital of Specialties, Mexican Institute of Social Security, Calle Seris S/N Azcapotzalco, La Raza, CP, 02990. DF. México, Tel: 5560732638; E-mail: enoequ@hotmail.com

**Keywords:** Composite gastric lymphoma; Diffuse large B-cell lymphoma; Classical hodgkin's lymphoma; Immunohistochemistry

<https://www.peertechz.com>

## Case Report

# Diffuse Large B-Cell Lymphoma and Classical Hodgkin'S Lymphoma Converge in an Unusual Presentation as a Gastric Composite Lymphoma: Case Report

## Abstract

An 88-year-old male, with a history of diffuse abdominal discomfort and weight loss that presented a composite gastric lymphoma (CGL) expressing CD20, BCL-6 and a high cell proliferation index in diffuse large B-cell lymphoma and positive to CD30 and C15 in typical Reed-Stenberg cells forming a Classical Hodgkin's lymphoma. Composite lymphoma represents <5% of the occurrence of lymphoma with a poor prognosis, which were corroborated and demonstrated with a characteristic immunophenotype.

## Background

Composite lymphoma defined as the coexistence of two or more morphologically and phenotypically distinct lymphoma types in a single anatomic organ or tissue [1]. The causes are unknown but several theories have been proposed, including clonal selection with additional mutational accumulation, genomic instability and an evidence with viral factor mostly by Epstein Barr Virus [1-3].

The reported incidence is less than 5% [2]. Composite gastric lymphoma (CGL) is a very rare occurrence with 0.025% and to date only three previous cases have been reported in the literature [1].

## Case Presentation

An 88-years-old male, without previous history of importance, presented eating disorder, diffuse abdominal discomfort with epigastric pain after feeding and weight loss of 10 kilograms, two months before being diagnosed with, a computerized tomography scan revealed a gross wall in gastric fundus, without lymphadenopathy. Endoscopy was performed and revealed an irregular infiltrating lesion in gastric body and fundus. The patient unfortunately declined any further oncology treatment, 6 months after initial diagnosis the patient was still alive with progressive tumor.

## Results

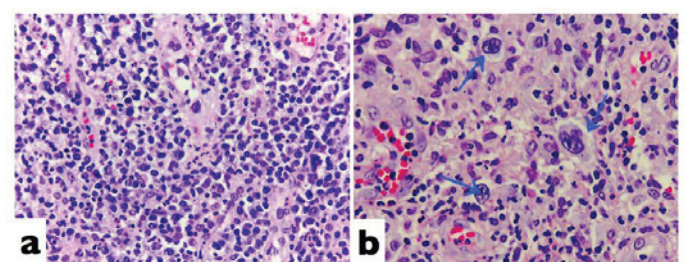
Histologically samples with hematoxylin and eosin showed

a diffuse population of two neoplastic lymphocytes cells. The first ones were characterized as a diffuse and large infiltrating lymphocytes that affects the lamina propria without harming the gastric fundus glands (Figure 1a).

The second type of neoplastic lymphoid cells identified were characterized by the classic Reed-Stenberg cells with abundant eosinophilic cytoplasm and two nuclear lobes with prominent nucleoli in a rich inflammatory background in gastric mucosa (Figure 1b).

## Discussion

This unusual entity exhibit a characteristic immunophenotype that represents the two population cells in



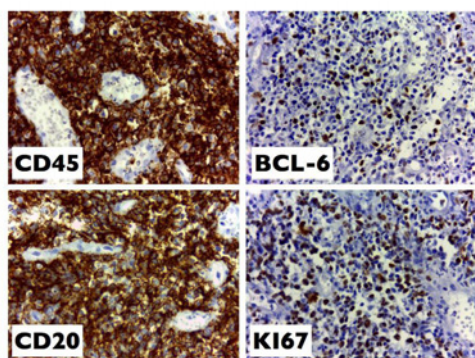
**Figure 1:** 1a. 40x diffuse population of large infiltrating lymphocytes that affects lamina propria without harming gastric glands. 1b. Characteristic Reed-Stenberg cells with abundant eosinophilic cytoplasm with reactive inflammatory background.

the same organ. Four cases, including the present case, have been reported in the literature with gastric localization (Table 1). But there are seven more cases reported as a composite lymphoma in other anatomical localizations one of them in small intestine and colon [3,4] and one case with GCL reported with no evidence of disease in a 67 year-old-man [5].

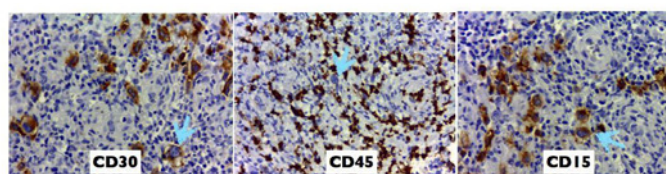
In the present case immunohistochemistry confirmed the presence of the two lymphoma population. Expressed CD45, CD20, BCL-2, BCL-6 and Ki67 was found in approximately 70% that represented the characteristic immunophenotype as a diffuse large B-cell lymphoma (Figure 2) in the other hand we demonstrated the co-existence of a classical Hodgkin's lymphoma with the presence of Reed-Stenberg cells that were positive to CD30, CD15 and with reactive background showed positive to CD45 (Figure 3).

**Table 1:** Composite gastric lymphoma (CGL) reported in the literature.

Author	Gender/Age	Treatment	Prognosis
Prochorec - Sobieszek et al. [5]	Male 67y Male 76 y	Both with chemotherapy	Alive Died (3 months)
Wang et al. [1]	Female 53y	Chemotherapy	Died (7 months)
Ramos et al. (present case)	Male 88y	Without treatment	Died (6 months)



**Figure 2:** Diffuse large B-cell lymphoma expressed positive to CD45, CD20, BCL-6 and Ki67 (70%).



**Figure 3:** Classical Hodgkin's lymphoma with RS cells positive to CD30 (Golgi-stain) CD15 (membrane) and negative to CD45 in RS cells and positive in reactive background.

The main differential morphological diagnosis is the Gray zone lymphoma with intermediate features, characterized by pleomorphic tumor cells with "sheet-like" pattern and a typically immunophenotype exhibiting a transitional features with CD45, CD30, CD15 and CD20 positive in almost all cells [6]. The results of the present report highlight the importance of using immunohistochemistry for the differential diagnosis. Since the composite lymphoma demonstrated the existence of two different lymphoid populations in the same organ without transitional features.

## Conclusion

GCL has been reported in isolated cases that represent a very rare entity that the occurrence may be underestimated. For this reason it is required a multidisciplinary approach with immunohistochemistry complementary studies, in order to detect the presence of two lymphomas in the same anatomic localization.

## Consent

Written informed consent was obtained from the patient for publication of this Short Report and any accompanying images. A copy of the written consent is available for review by the Editor-in-Chief of this journal.

## References

1. Wang HW, Yang W, Wang L, Lu YL, Lu JY (2013) Composite diffuse large B-cell lymphoma and classical Hodgkin's lymphoma of the stomach: Case report and literature review. *World J Gastroenterol* 19: 6304-6309. [Link: https://goo.gl/mimm8b](https://goo.gl/mimm8b)
2. Thirumala S, Esposito M, Fuchs A (2000) An unusual variant of composite lymphoma: a short case report and review of the literature. *Arch Pathol Lab Med* 24: 1376-1378. [Link: https://goo.gl/xdSCMj](https://goo.gl/xdSCMj)
3. Huang Q, Wilczynski SP, Chang KL, Weiss LM (2006) Composite Recurrent Hodgkin Lymphoma and Diffuse Large B-Cell Lymphoma. *American J Clin Pathol* 126: 222-229. [Link: https://goo.gl/bxWuxB](https://goo.gl/bxWuxB)
4. Asharafi F, Kowsari F, Darakhshandeh A, Adibi P (2014) Composite lymphoma in a patient with ulcerative colitis: A case report. *Int J Hematol Oncol Stem Cell Res* 8: 45-48. [Link: https://goo.gl/OW0IBU](https://goo.gl/OW0IBU)
5. Prochorec-Sobieszek M, Majewski M, Sikorska A, Kos K, Huszcza S, et al. (2006) Localized gastric diffuse large B-cell lymphoma and Hodgkin's lymphoma as a secondary neoplasms in two patients with chronic lymphocytic leukemia. *Leuk Lymphoma* 47: 2244-2246. [Link: https://goo.gl/KCa2pS](https://goo.gl/KCa2pS)
6. Jaffe ES, Stein H, Swerdlow SH, Campo E, Pileri SA, Harris NL (2008) WHO Classification of Tumours of Haematopoietic and Lymphoid Tissues. 4th Edition. Lyon 267. [Link: https://goo.gl/wD6xx3](https://goo.gl/wD6xx3)