

Shaik Afsar Pasha<sup>1</sup>, Ankamma Rao<sup>2</sup>, Phani Bhushan<sup>3</sup>, Bhaskara Rao B<sup>4</sup> and Prasunpriya Nayak<sup>5\*</sup>

<sup>1</sup>Department of Neurology, NRI Medical College, General Hospital, Chinakakani, Guntur District, Andhra Pradesh 522503, India.

<sup>2</sup>Department of Radiology, NRI Medical College, General Hospital, Chinakakani, Guntur District, Andhra Pradesh 522503, India.

<sup>3</sup>Department of Psychiatry, NRI Medical College, General Hospital, Chinakakani, Guntur District, Andhra Pradesh 522503, India.

<sup>4</sup>Department of General Medicine, NRI Medical College, General Hospital, Chinakakani, Guntur District, Andhra Pradesh 522503, India.

<sup>5</sup>Department of Physiology, NRI Medical College, General Hospital, Chinakakani, Guntur District, Andhra Pradesh 522503, India.

Dates: Received: 08 March, 2017; Accepted: 31 March, 2017; Published: 03 April, 2017

\*Corresponding author: Dr. Prasunpriya Nayak, Department of Physiology, NRI Medical College, General Hospital, Chinakakani, Guntur, Andhra Pradesh, 522503, India; Email: nprasunpriya@hotmail.com

**Keywords:** Creutzfeldt-Jakob disease; South India.

<https://www.peertechz.com>

## Case Report

# Case Report of Clinically Probable Sporadic Creutzfeldt - Jakob Disease from A Tertiary Care Hospital in South India

## Abstract

We are reporting an otherwise healthy lady of forty eight years suffering from rapidly progressive dementia, behavioural disturbances, myoclonus, ataxia and extrapyramidal features of eight months duration with characteristic abnormalities on brain imaging, electroencephalography with positive cerebrospinal fluid 14-3-3 protein, satisfying the revised World Health organization (WHO) criteria for diagnosis of "clinically probable Sporadic Creutzfeldt-Jakob disease (sCJD)". An attempt was made to clinically differentiate the diagnostic possibilities.

37 years, 85 cases were reported by Shankar et al from 1968 to 2005 [3]. Ten cases were reported from Delhi and seven cases from Mumbai, and eight cases from Bengaluru.

Prions are characterized by their infectious properties and by the intrinsic ability of their structures to act as a template and convert the normal physiological PrP<sup>C</sup> into the pathological disease-causing form, PrP<sup>Sc</sup>. PrP<sup>Sc</sup> acts as a template for the misfolding of PrP<sup>C</sup> into PrP<sup>Sc</sup>.

CJD can present in four forms namely sporadic (85%), familial (10-15%), iatrogenic (<1%) and variant CJD (<1%). Sporadic CJD manifests at 6<sup>th</sup>-7<sup>th</sup> decade with rapidly progressive dementia, behavioral dyscontrol in the form of aggressive outbursts, restlessness, irritable, delirium, hallucinations, delusions, apathy, confusional spells followed by pyramidal, extrapyramidal, cerebellar symptoms including myoclonus. The characteristic features of myoclonus includes-being generalized, fast at a frequency of 1 per second, stimulus sensitive and non-epileptic. Ocular symptoms sometimes coexist in the form of cortical blindness, distortion of seen objects and paralysis of convergence or upgaze. Our patient has multifocal generalized myoclonus on a background of dementia, ataxia and behavioural disturbances. The Variant CJD manifests in relatively young patients with early psychiatric features, chorea, myoclonus, persistent painful paraesthesia followed by dementia. The salient features of Sporadic and Variant CJD are enlisted in (Table 1).

As already mentioned, MRI brain can be normal in the earlier stage of the disease, however, the signal alterations

## Introduction

Sporadic Creutzfeldt-Jakob disease is the most common of the prion diseases affecting the human race [1]. Prion diseases, a group of uniformly fatal neurodegenerative diseases, caused by conformational change of PrP<sup>C</sup> (normal cellular form of prion protein) to abnormal PrP<sup>Sc</sup> (abnormal scrapie of prion protein) which cumulates in various regions of the brain resulting in spongiform degeneration and gliosis [2]. In humans, prion protein is encoded by a gene PRNP located on short arm of chromosome 20. Sporadic CJD has been divided into approximately six molecular subtypes based on the genetic polymorphism at codon 129 in the prion gene (MM, MV, or VV) and the type of protease resistant Prion (type 1 and type 2). Sporadic CJD patient's progress very rapidly starting with dementia, behavioral disturbances, myoclonus and terminally into akinetic mute state.

Creutzfeldt-Jakob disease (CJD) is one of the prion diseases, the characteristic features of which are long asymptomatic incubation period and short symptomatic period with an eventual fatal course resulting in death. Estimated incidence is 1-2 cases per million worldwide while in India, it is 0.01 cases per million population. From National CJD registry over

**Table 1:** Differentiating features of Sporadic CJD from Variant CJD

Clinical feature	Sporadic CJD	Variant CJD
Average age at Clinical Onset	63 years	28 years
Length of survival from date of clinical onset	4 months	14 months
Early symptoms	Cognition, behavioural	Psychosis, depression
MRI Brain	Increased signal in caudate, putamen	Increased signal in Pulvinar region of Thalamus
EEG	Bi-phasic or triphasic complex	Non-specific or slow
CSF 14-3-3 Protein	Usually elevated	Usually not elevated
Histopathology of brain tissue	No amyloid plaques	100% florid plaques
PrP IHC staining pattern of brain tissue	Punctate pattern	Widespread plaque staining pattern
IHC staining of tonsil/ appendix	Negative	PrP <sup>d</sup> present in late stages

precede the changes in EEG and CSF abnormalities. Among the sequences, T2, FLAIR, DWI, ADC mapping has been used to detect the abnormality. DWI sequence is more sensitive (92%) and specific (93%). However combination of DWI and FLAIR signal changes increased the sensitivity to 98% and specificity to 95%. DWI sequence is more sensitive in the diagnosis of CJD in its early stage independent of EEG changes. Two patterns of abnormalities were described like isolated cortical gyri hyperintensities, combined cortical and deep gray nuclear (basal ganglia) involvement and Isolated Basal ganglionic changes could have been Third pattern [4]. Most common type is pattern two. The pathological correlate of T2 and FLAIR hyperintensity is astrogliosis, while vacuole formation which restricts the water diffusion in DWI imaging. Involvement of deep gray matter is associated with shorter disease course with rapidly progressing neurologic deterioration whereas absence of basal ganglia involvement correlates with delayed onset of dementia and longer disease course [5]. Combined DWI and FLAIR has higher sensitivity (91%) and specificity (95%) for CJD [6]. However, Vitali et al reaffirms that the pattern of FLAIR/DWI hyperintensity and reduction of ADC in striatal hyper intensity regions on DWI differentiates sporadic CJD from other rapidly progressive dementia with 98% sensitivity and 100% specificity [7].

## Case Report

48 year old lady, mother of 2 children, uneducated, right handed, was brought by family members with eight months history of forgetfulness involving the household works, failure to recognize the familiar faces and naming them, associated with repeating the words uttered and delayed response to the question asked. She keeps on repeating the same task without interruption. Geographic disorientation and way finding difficulty was present since 1 month. Behavioral symptoms of 2 months duration comprising restlessness, irritable and agitated at times with emotional liability of 1 month duration. She also developed infrequent jerky movements of the trunk and the limbs and tremors of the hands more than legs, bilateral (left side more than right side). Occasional incontinence of urine

was present. She was swaying to either side while walking requiring one person support to walk. No preceding history of fever, headache, vomiting and seizures. No history of recent vaccination, dog bite or head injury. She consumes non-vegetarian diet.

She scored 12 over 28 Mini-mental status examination (Folstein MMSE) scale suggestive of severe dementia. She was suspicious, anxious and fearful with hallucinations. She had insight about her problem but impaired judgement. Significant impairment in recent and immediate memory domains with remote memory being intact. Stimulus sensitive myoclonus was present with auditory startle. No cranial nerve involvement including eye movement abnormalities. She had lower limb rigidity with normal tone in the hands. She had normal power, preserved deep tendon jerks and plantars were flexors. She had postural tremors of both hands, generalised multifocal myoclonic jerks of the trunk and the limbs. Bilateral finger nose in coordination with impaired Tandem gait was present.

She had rapidly progressive dementia to start with frontal lobes followed by temporal and parietal lobes with cerebellar ataxia, tremors and myoclonus. Differential diagnostic possibilities of Paraneoplastic encephalitis, autoimmune encephalitis, Hashimoto's encephalitis, Isolated CNS Vasculitis were considered (Table 2).

## Laboratory evaluation

She had hemoglobin of 11 mg%, total leucocyte count of 8200 cells/cu.mm, ESR of 20 mm in 1<sup>st</sup> hour. Serum Vitamin B12 was within normal limits. Renal function tests were normal, liver profile was normal including plasma ammonia. Serum electrolytes including Calcium were within normal limits. Thyroid profile was normal including anti-thyroid peroxidase (anti-TPO) antibodies. Serum was negative for anti-nuclear antibodies (ANA), Human immunodeficiency virus (HIV), Venereal disease research laboratory test (VDRL) and Voltage gated potassium channel antibody level (VGKC).

Cerebrospinal fluid (CSF) analysis revealed glucose of 72 mg/dl, protein of 20 mg/dl with four lymphocytes. CSF for Gram stain and Acid fast bacillary stain was negative. HSV-DNA PCR was negative in CSF. CSF for 14-3-3 protein was positive 1.5 ng/ml (reference range <1.5 ng/ml). CSF for paraneoplastic panel was negative for anti-Hu, anti-Ma 2 and CV-2. Magnetic resonance imaging of the brain (Figures 1,2) showed more or less symmetrical T2 and FLAIR hyperintensities of bilateral caudate, putamen, with areas of diffusion restriction (hyperintense on DWI sequence and hypointense on corresponding ADC mapping sequences) in bilateral parietal and occipital gyri (cortical ribboning), insular cortices, cingulate gyri with spared thalami with moderate cortical atrophy. Electroencephalogram (Figure 3) revealed periodic sharp waves of diphasic and triphasic morphology without anterior to posterior lag. Table 2 illustrates the differentiating features of diagnostic possibilities and favouring the diagnosis of CJD.

**Table 2:** Differential Diagnosis.

Features	Paraneoplastic encephalitis	Autoimmune encephalitis	Hashimotos Encephalitis	Isolated CNS Vasculitis	CJD
Age	Any age	60's	50's	Any age	60's
Initial symptoms	Memory loss Confusion	Memory loss Psychosis Seizures Movement dis	Behaviouralsyndromes Cognition Seizures	Headache Hemiparesis Seizures Ataxia	Cognition Behaviour Personality
Pathophysiology	Anti-Hu, Ma-2, CV2 T-cell mediat	AMPA GABA-B LGI-1	Elevated TPO TG	Granulomata inflammation	<sup>sc</sup> PrP <sup>sc</sup> cumulation
MRI Brain	Medial Temporal Lobe	Medial Temporal Lobe Cortical-subcortical	Cortical-subcortical	hemorrhages/infarcts	Cortical gyri, basal ganglia
CSF	Elevated cells and protein	Elevated cells and protein	Elevated cells and protein	variable	Normal comp 14-3-3+
EEG	Seizure discharge	Seizure discharge	Triphasic waves	normal	Periodic sharp wave complex
Treatment	Underlying cancer	Tumour/Steroids	IV Steroids	IV Steroids	Palliative
Prognosis	Variable	Variable	Good	Variable	Poor

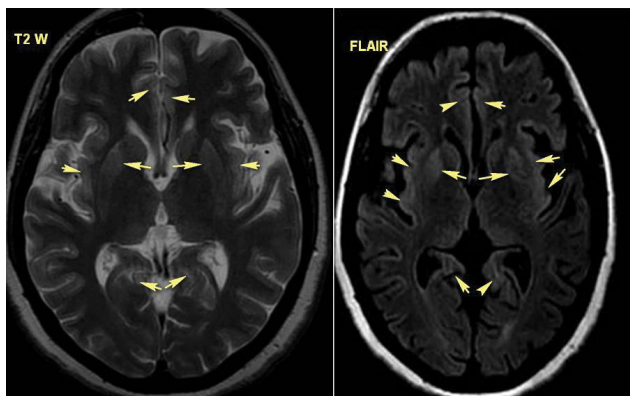


Figure 1: MRI Brain axial T2 and FLAIR sequences showing symmetrical hyperintensities in bilateral caudate, putamen, insular gyri, occipital gyri, cingulate gyri (arrows).

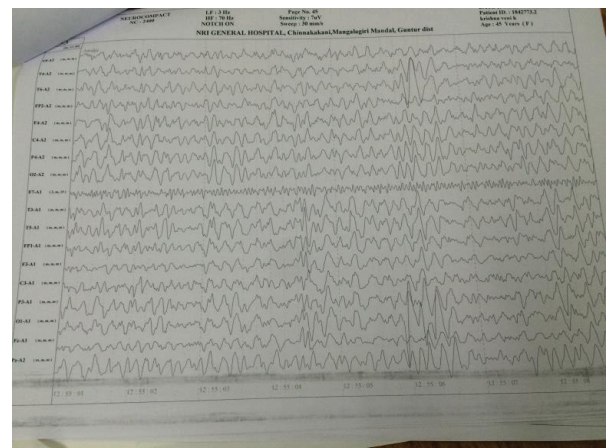


Figure 3: Electroencephalographic recording showing periodic sharp waves and triphasic waves.

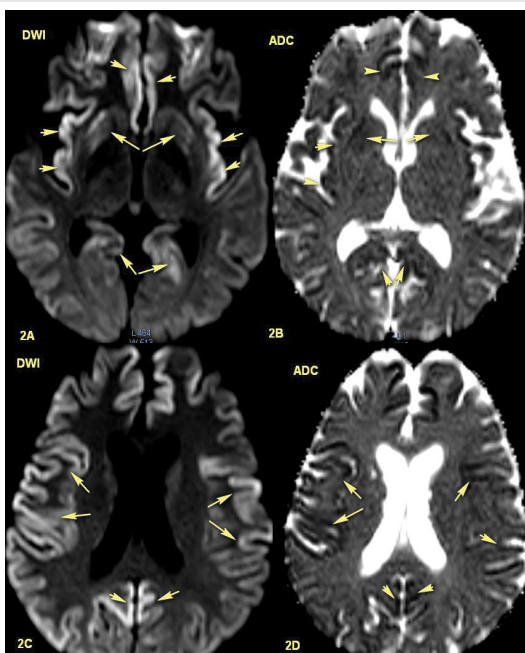


Figure 2: MRI axial DWI and corresponding ADC mapping sequences showing symmetrical hyperintensities of basal ganglia (arrows) and cortical regions with 'cortical ribbon' (arrows, parietal).

## Discussion

This patient was diagnosed as clinically probable CJD in view of rapidly progressive dementia, cerebellar ataxia and cortical myoclonus, disease duration of less than 2 years, EEG abnormality and MRI brain abnormality, which is compatible with the diagnosis of CJD.

The age at onset of the disease was relatively younger in our case as similar to the published cases by Mehndiratta et al. [8]. The female preponderance among the published case series was also reported by Mehndiratta et al. [8]. Our patient had the typical clinical manifestations like rapidly progressive dementia, myoclonus, ataxia, tremors and behavioural symptoms. Similar observations were noted in the case series by Velásquez-Pérez et al. [9] and González Duarte et al. [10]. Behavioural manifestations in CJD occur in 30% of patients at the onset and 57% at later stages of the disease [1]. Mahale et al. found 62% of their patients having behavioural manifestations [11]. Our patient did not have any family history, hence we presume this as sporadic CJD. Familial CJD was reported only in 2 cases by González Duarte et al [10], and single reports by Mehndiratta et al. [8] and Chandra et al. [12]. The time interval between the onset of the symptoms to the diagnosis was 8

months in our case while it ranges from 1-12 months in other case series [8,10]. As per the literature, the mean duration from onset of symptoms to the time of death was 6.6 months (Range: 3-14 months) [8,10]. The mean survival of CJD patients is 5 months and about 80% of patients succumb to disease after 12 months from onset [1]. Our patient is alive and dependent on care givers for her daily functioning.

EEG in our patient showed triphasic waves and periodic sharp wave complexes, however, it can be normal in the earlier part of the disease but classical features would be generalized periodic sharp waves, biphasic and triphasic waves at a rate of one per second. EEG has a sensitivity of 67% and specificity of 74.86% in the diagnosis of CJD [10]. Repeated EEG during the course of disease increases the probability of demonstrating characteristic EEG abnormality. Similar EEG findings is sometimes possible in Hashimoto's encephalopathy and VGKC encephalitis but easily can be differentiated as illustrated in (Table 2).

Imaging study of the current patient revealed abnormality in both deep gray nuclei and cortical gyri. Similar to our observations, Mahale et al. reported six of their eight patients showing symmetrical basal ganglionic hyperintensities, which were showing restriction under DWI imaging, however cortical signal changes (parieto-occipital, frontal and temporal) did not show restriction [11]. Similar abnormalities were also reported by González Duarte et al. [10] in 5 of 7 patients showing only basal ganglionic abnormalities without cortical signal changes (Pattern 3). Recently, Biswas et al. [13] had shown 100% (10/10) of their patients showing Pattern two abnormalities (Basal ganglionic signal changes – 8 patients and parieto occipital signal changes – 2 patients). Magnetic resonance imaging of brain can be normal in the earliest stages of CJD while it may show only atrophy in the terminal stage of the illness with the classical signal alterations might have disappeared.

The detection of the 14-3-3 protein in CSF has been one of the markers for diagnosis of CJD [14]. This protein detection raises the accuracy in diagnosing sporadic CJD with sensitivity of 92% and specificity 80% [15]. But Zerr et al. refuted this observation as they found that imaging findings were equivalent to elevated levels of the 14-3-3 protein in the diagnosis of probable sporadic CJD [16]. Other biomarkers such as t-tau, p-tau, S-100, or neuron-specific enolase (NSE) in the CSF are required in addition to, protein 14-3-3 [15].

## Diagnosis

The diagnosis is based on clinical profile of the onset and course of symptoms, EEG changes and typical imaging abnormalities. Several clinical criteria exist, but the better bedside one is the CDC's Clinical criteria for diagnosis of CJD 2010 which is the Revised WHO criteria (Table 3) [17]. Of late, other than CSF 14-3-3 which is a surrogate marker for the diagnosis of CJD, several other markers like Neuron specific enolase (NSE), S-100 beta amyloid, p-tau, t-tau are available. Focusing the possibilities of early detection of prion diseases, recently, anti-prion screening test using real time quacking-

induced conversion has been reported [18]. Though, olfactory epithelium is a known peripheral target of PrP<sup>sc</sup> deposition in sCJD [19], CSF and urine are also reliable source for early detection of sCJD [20], whereas, a new blood test has been recently identified with 100% sensitivity and specificity in vCJD [21]. Yield of different diagnostic tests is enlisted in the (Table 4).

## Conclusion

High index of suspicion is required to identify the patients with classical manifestations so as to register to the national authority and to take necessary preventable action, if possible, and to treat symptomatically in view of lack of definite curative treatment at present for this fatal disease.

**Table 3:** CDC's Diagnostic Criteria for Creutzfeldt-Jakob Disease (CJD), 2010 (Revised WHO criteria 1998).

<b>Definite:</b> Diagnosed by standard neuropathological techniques; and/or immunocytochemically and/or western blot confirmed protease-resistant PrP and/or presence of scrapie-associated fibrils
<b>Probable:</b> Progressive dementia; and at least two out of the following four clinical features: Myoclonus visual or cerebellar disturbance pyramidal/extrapyramidal dysfunction akinetic mutism; and a typical EEG during an illness of any duration and/or a positive 14-3-3 CSF assay and a clinical duration to death routine investigations should not suggest an alternative diagnosis
<b>Possible:</b> Progressive dementia; and at least two out of the following four clinical features: Myoclonus visual or cerebellar disturbance pyramidal/extrapyramidal dysfunction akinetic mutism, and no EEG or atypical EEG; duration to death <2 years
<b>Iatrogenic CJD:</b> Progressive cerebellar syndrome in a recipient of human cadaveric-derived pituitary hormone; or sporadic CJD with a recognized exposure risk, e.g., antecedent neurosurgery with dura mater graft
<b>Familial CJD:</b> Definite or probable CJD plus definite or probable CJD in a first-degree relative; and/or neuropsychiatric disorder plus disease-specific PrP gene mutation.

**Table 4:** Yield of Diagnostic tests in CJD.

Test Name	Sensitivity (%)	Specificity (%)
CSF 14-3-3	92	80
CSF tau >1300 pg/ml	86	88
CSF NSE	73	95
S100Beta	82	76
Real-time quaking-induced conversion (RT-QuIC)	80-87	98-100
MRI Brain	60-90	94
FLAIR+DWI	98	95

## References

- Brown P, Gibbs CJ Jr, Rodgers-Johnson P, Asher DM, Sulima MP, et al. (1994) Human spongiform encephalopathy: The National Institutes of Health series of 300 cases of experimentally transmitted disease. *Ann Neurol* 35: 513-529. [Link: https://goo.gl/CKZ9EA](https://goo.gl/CKZ9EA)
- Glatzel M, Ott PM, Linder T, Gebbers JO, Gmür A, et al. (2003). Human prion diseases: Epidemiology and integrated risk assessment. *Lancet Neurol* 2: 757-763. [Link: https://goo.gl/sP7sZG](https://goo.gl/sP7sZG)

3. Shankar SK, Satishchandra P (2005) Did BSE in the UK originate from Indian subcontinent? *Lancet* 366: 790-791. [Link: https://goo.gl/yXjA7J](https://goo.gl/yXjA7J)
4. Meissner B, Kallenberg K, Sanchez-Juan P, Krasnianski A, Heinemann U, et al. (2008) Isolated cortical signal increase on MR imaging as a frequent lesion pattern in sporadic Creutzfeldt-Jakob disease. *AJNR Am J Neuroradiol* 29: 1519-1524. [Link: https://goo.gl/Ak5Fif](https://goo.gl/Ak5Fif)
5. Meissner B, Körtner K, Bartl M, Jastrow U, Mollenhauer B, et al. (2004) Sporadic Creutzfeldt-Jakob disease: Magnetic resonance imaging and clinical findings. *Neurology* 63: 450-56. [Link: https://goo.gl/oR2VJY](https://goo.gl/oR2VJY)
6. Young GS, Geschwind DM, Fischbein NJ, Martindale JL, Henry RG, et al. (2005) Diffusion weighted and fluid attenuated inversion recovery imaging in Creutzfeldt Jakob disease: High sensitivity and specificity for diagnosis. *AJNR Am J Neuroradiol* 26: 1551-1562. [Link: https://goo.gl/BjhUcc](https://goo.gl/BjhUcc)
7. Vitali P, Maccagnano E, Caverzasi E, Henry RG, Haman A, et al. (2011) Diffusion-weighted MRI hyperintensity patterns differentiate CJD from other rapid dementias. *Neurology* 76: 1711-1719. [Link: https://goo.gl/nH8gn](https://goo.gl/nH8gn)
8. Mehndiratta MM, Bajaj BK, Gupta M, Anand R, Tatke M, et al. (2001) Creutzfeldt-Jakob disease: Report of 10 cases from North India. *Neurol India* 49: 338-341. [Link: https://goo.gl/72UxvN](https://goo.gl/72UxvN)
9. Velásquez-Pérez L, Rembao-Bojorquez J, Guevara J, Guadarrama-Torres RM, Trejo-Contreras A (2007) Creutzfeldt-Jakob disease in Mexico. *Neuropathology* 27: 419-428. [Link: https://goo.gl/Exv7EF](https://goo.gl/Exv7EF)
10. González-Duarte A, Medina Z, Balaguer RR, Calleja JH (2011) Can prion disease suspicion be supported earlier? Clinical, radiological and laboratory findings in a series of cases. *Prion* 5: 20-207. [Link: https://goo.gl/bxdTYV](https://goo.gl/bxdTYV)
11. Mahale RR, Javali M, Mehta A, Sharma S, Acharya P, et al. (2015). A study of clinical profile, radiological and electroencephalographic characteristics of suspected Creutzfeldt-Jakob disease in a tertiary care centre in South India. *J Neurosci Rural Pract* 6: 39-50. [Link: https://goo.gl/ES6fND](https://goo.gl/ES6fND)
12. Chandra SR, Issac TG, Philip M, Gadad V (2016) Creutzfeldt–Jakob disease phenotype and course: Our experience from a tertiary center. *Indian J Psychol Med* 38: 438-442. [Link: https://goo.gl/gfQjR5](https://goo.gl/gfQjR5)
13. Biswas A, Khandelwal N, Pandit A, Roy A, Guin DS, et al. (2013) Case series of probable sporadic Creutzfeldt-Jakob disease from Eastern India. *Ann Indian Acad Neurol* 16: 659-63. [Link: https://goo.gl/qCl8Db](https://goo.gl/qCl8Db)
14. Zerr I, Pocchiari M, Collins S, Brandel JP, de Pedro Cuesta J, et al. (2000) Analysis of EEG and CSF 14-3-3 proteins as aids to the diagnosis of Creutzfeldt-Jakob disease. *Neurology* 2000 55: 811-815. [Link: https://goo.gl/pUMb2x](https://goo.gl/pUMb2x)
15. Muayqil T, Gronseth G, Camicioli R (2012) Evidence-based guideline: Diagnostic accuracy of CSF 14-3-3 protein in sporadic Creutzfeldt-Jakob disease: Report of the Guideline Development Subcommittee of the American Academy of Neurology. *Neurology* 79: 1499-1506. [Link: https://goo.gl/LozQQ4](https://goo.gl/LozQQ4)
16. Zerr I, Kallenberg K, Summers DM, Romero C, Taratuto A, et al. (2009) Updated clinical diagnostic criteria for sporadic Creutzfeldt-Jakob disease. *Brain* 132: 2659-2668. [Link: https://goo.gl/mLBo4r](https://goo.gl/mLBo4r)
17. Revised WHO Definition of CJD Subtypes (Incorporating the New Definition of Probable Sporadic CJD as Per Section 3.1. [Link: https://goo.gl/RNYMKO](https://goo.gl/RNYMKO)
18. Hyeon JW, Kim SY, Lee SM, Lee J, An SSA, et al. (2017) Anti-Prion Screening for Acridine, Dextran, and Tannic Acid using Real Time–Quaking Induced Conversion: A Comparison with PrPSc-Infected Cell Screening. *PLoS ONE* 12: 1. [Link: https://goo.gl/PpAilM](https://goo.gl/PpAilM)
19. Zanusso G, Ferrari S, Cardone F, Zampieri P, Gelati M, et al. (2003) Detection of pathologic prion protein in the olfactory epithelium in sporadic Creutzfeldt-Jakob disease. *N Engl J Med* 348: 711-719. [Link: https://goo.gl/voPkiC](https://goo.gl/voPkiC)
20. Vetrugno V, Puopolo M, Cardone F, Capozzoli F, Ladogana A, et al. (2015) The future for treating Creutzfeldt-Jakob disease. *Expert Opin Orphan Drugs* 3: 57-74. [Link: https://goo.gl/M114h2](https://goo.gl/M114h2)
21. Concha-Marambio L, Pritzkow S, Moda F, Tagliavini F, Ironside JW, et al. (2016) Detection of prions in blood from patients with variant Creutzfeldt-Jakob disease. *Sci Transl Med*. 8: 370ra183. [Link: https://goo.gl/QGWkpY](https://goo.gl/QGWkpY)