



Vedat Goral^{1*}, Ragip Ortac² and Nevin Yilmaz³

¹Istanbul Medipol University School of Medicine
Department of Gastroenterology, Istanbul, Turkey

²Medicalpark Hospital Department of
Gastroenterology and Pathology, Izmir, Turkey

³Mugla Sitki Kocman University School of Medicine
Department of Gastroenterology, Turkey

Dates: Received: 14 July, 2017; Accepted: 22 August, 2017; Published: 23 August, 2017

***Corresponding authors:** Vedat Goral, Istanbul Medipol University, School of Medicine, Department of Gastroenterology, Turkey,
E-mail: vegoral@hotmail.com

Keywords: Multipl myeloma, Amyloidosis, Rectal bleeding

<https://www.peertechz.com>

Case Report

Amyloidosis in colon presenting with rectal bleeding in multipl myeloma: A Case Report

Abstract

Multiple myeloma (MM) is a malignant proliferation of plasma cells that secrete monoclonal immunoglobulin (M protein). It accounts for 1% of all cancers and 10% of hematological malignancies. Mean age at diagnosis is 66 years. The most common findings are bone pain, pathological fractures, anemia, bone marrow failure, Infections triggered by neutropenia and immunodeficiency, and kidney failure and rarely can cause acute hypercalcaemia, symptomatic hyperviscosity, neuropathy, amyloidosis and coagulopathy.

Amyloidosis is a rare disease characterized by nonspecific symptoms and signs. It can be seen anywhere in the gastrointestinal tract.

In this case, a colonoscopy was performed on the patient who was directed to gastroenterology clinic with rectal bleeding and amyloidosis was detected in the biopsy from tumoral lesions seen in the colonoscopy.

Case Report

A 76-year-old female patient with multiple myeloma was directed to gastroenterology with rectal bleeding while hospitalized with acute renal failure and hypercalcemia. The patient underwent colonoscopy and lumen-narrowing, vegetan, erosional, moderately hard, pseudotumor-like, muco-pleural lesions were detected at approximately between 50-60. cm on colonoscopy. There was partial narrowing and pseudotumor in the colon. Six different biopsies were taken from different places on lesions. Homogenous, amorphous material accumulation in the submucosa and around the veins were detected in the

biopsy specimens stained with hematoxylin and eosin dye and Congo red. Colonoscopic images are shown in figure 1, and images of pathological specimens are shown in figures 2a,b. The patient underwent a second colonoscopy 1 month later for control. The lesions detected in the first colonoscopy were not found (Figure 3). On the second colonoscopy, biopsy was taken again from the rectosigmoid region, but it has been observed that the amyloidosis continues in biopsy.

Discussion

Multiple myeloma (MM) is a malignant proliferation of plasma cells that secrete monoclonal immunoglobulin (M

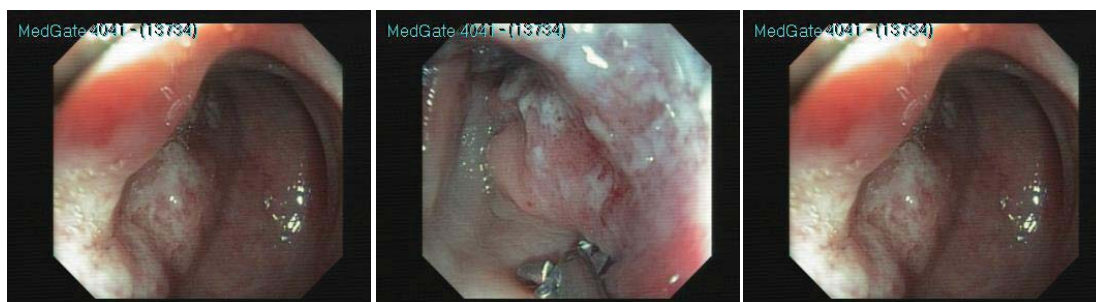


Figure 1: Colonoscopy views.

protein) [1-5]. It accounts for 1% of all cancers and 10% of hematological malignancies. Mean age at diagnosis is 66 years. Radiation, genetics such as t (11; 14), t (14; 18), t (8; 14), 13q deletion, familial predisposition, IL-6 and IL1- β are implicated in etiology. The disease is characterized by lytic lesions in the bones, (humoral) immunodeficiency, renal, and neurological symptoms. In addition to the clinical features of myeloma; anemia and roll formation, serum M protein concentration > 3 g / dl, elevation of sedimentation rate, > 30% plasma cell in bone marrow, and immunophenotype such as (+) staining with CD38, CD56, and CD138 were also detected. As clinically heterogeneous disease, MM can be classified into two types, usually untreated, silent myeloma (SMM) and MM (active) requiring treatment. The diagnostic criteria for MM were revised in 2014 by the International Myeloma Working Group (IMWG) [2,4]. The most common findings are bone pain, pathological fractures, anemia, bone marrow failure, Infections triggered by neutropenia and immunodeficiency, and kidney failure and rarely can cause acute hypercalcaemia,

symptomatic hyperviscosity, neuropathy, amyloidosis and coagulopathy.

In amyloidosis, amyloid, the abnormal protein, is deposited in the tissues as an extracellular deposit [6-9]. Amyloid deposits are found in the vascular veins and in the intestinal system in the mucosa, submucosa, muscularis mucosa layer [10-12]. Similar amyloid deposits were present in our case. Amyloid deposits in the intestines are seen as pseudotumor or ulceration. Amyloid protein accumulates irreversibly in the colon. However, in some publications it is reported that amyloid deposition can be reversible with chemotherapy treatment, especially with melphalan and steroid therapy, in the early stages [13-15].

AL amyloidosis is characterized by plasma cell dyscrasia and monoclonal light chain in in serum and / or urine; and this type of amyloidosis largely seen in the gastrointestinal system [7]. AL amyloidosis is characterized by multiple myelomas in 15% of the cases. It is a rare disease characterized by nonspecific symptoms and signs. It can be seen anywhere in the gastrointestinal tract. Amyloidosis can mimic other diseases of the gastrointestinal tract, such as inflammatory bowel diseases, ischemic colitis, collagenous colitis, and malignancies [6-8]. Due to non-specific symptoms, diagnosis can easily be missed in patients who have not been diagnosed previously with amyloidosis or a related disease. The prognosis of MM involving the GI tract is unfavorable. Stomach and duodenal involvement is rare, and asymptomatic, or can cause nausea, vomiting, pain and sometimes hematemesis. Diarrhea, protein losing enteropathy, ulcers, masses, gastric ulcer, hypotonia and dilatation may be present in small bowel involvement. The endoscopic detection of a submucosal petechial hematomas and polypoid lesions in the setting of gastrointestinal bleeding should raise suspicion of the disease. Rarely, colonic amyloidosis can be the first sign of multiple myeloma [7,11,12,16]. Sometimes it can also cause upper gastrointestinal bleeding in cases of jejunal involvement [17]. The development of amyloidosis in multiple myeloma negatively affects the disease and shortens the survival [15].

Amyloid is most commonly located in the sigmoid colon and rectosigmoid region in the gastrointestinal tract. There is rectal bleeding in 25-45% of cases, caused by ischemia, infarction, or ulceration in cases with amyloidosis involvement in the colon, Amyloid involvement in the colon and gastrointestinal bleeding linked to multiple myeloma cases have been reported in the literature [6].

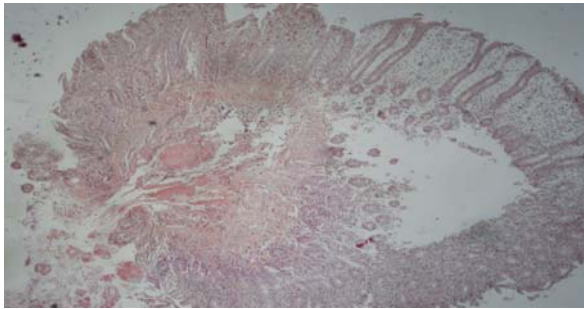


Figure 2a: Congo red positive amyloid deposits on submucosal vessel walls in colon biopsy (x40; Congo red, photo 7394).

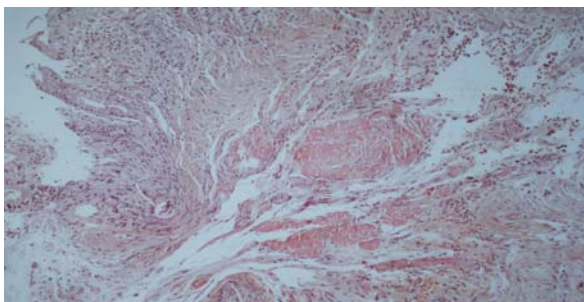


Figure 2b: Thickening of the walls of the submucosa due to congo red-positive amyloid deposits (x100; Congo red, photo 7396).

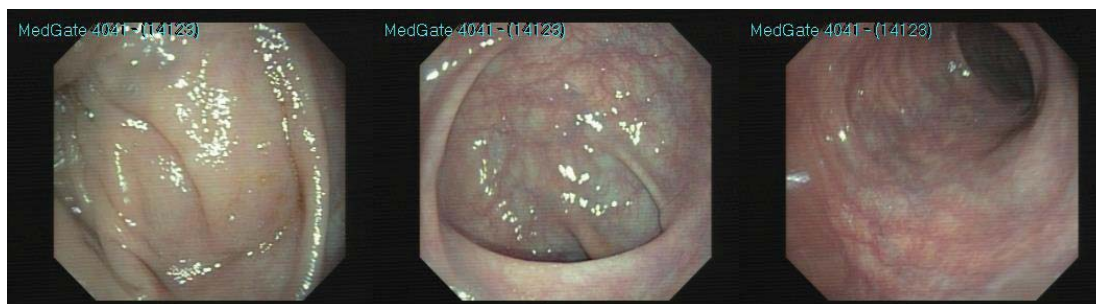

Figure 3: Normal colonoscopic appearance.

In our case, the case of amyloidosis in the colon with rectal bleeding is very rare. The disease treatment and supportive care were applied to the patient; surgical intervention or endoscopic intervention (such as APC, selective micro-coil remobilization therapy, or injection therapy) were not done. It was seen that the lesions completely disappeared in the control colonoscopy 1 month after. This case demonstrates that although it is rare, amyloidosis can be seen in colon in patients with multiple myeloma and this patients can be presented with rectal bleeding.

References

- Kazandjian D (2016) Multiple myeloma epidemiology and survival: A unique malignancy. *Semin Oncol* 43: 676-681. [Link: https://goo.gl/PHvHHP](https://goo.gl/PHvHHP)
- Pratt G, Morris TC (2016) Review of the NICE guidelines for multiple myeloma. *Int J Lab Hematol* 20. [Link: https://goo.gl/mHMuxX](https://goo.gl/mHMuxX)
- Smith D, Yong K (2016) Advances in understanding prognosis in myeloma. *Br J Haematol* 175: 367-380. [Link: https://goo.gl/CFCm98](https://goo.gl/CFCm98)
- Fonseca R, Monge J, Dimopoulos MA (2014) Staging and prognostication of multiple myeloma. *Expert Rev Hematol* 7: 21-31. [Link: https://goo.gl/qzRnAu](https://goo.gl/qzRnAu)
- Fonseca R, Monge J (2013) Myeloma: classification and risk assessment. *Semin Oncol* 40: 554-566. [Link: https://goo.gl/qRxfm5](https://goo.gl/qRxfm5)
- Ebert EC, Nagar M (2008) Gastrointestinal manifestations of amyloidosis. *Am J Gastroenterol* 103: 776-787. [Link: https://goo.gl/YPvMY8](https://goo.gl/YPvMY8)
- Hurlston DP (2002) Iron-deficiency anemia complicating AL amyloidosis with recurrent small bowel pseudo-obstruction and hindgut sparing. *J Gastroenterol Hepatol* 17: 623-624. [Link: https://goo.gl/YqZtPx](https://goo.gl/YqZtPx)
- Matsui H, Kato T, Inoue G, Onjie E (1996) Amyloidosis localized in the sigmoid colon. *J Gastroenterol* 31: 601-617. [Link: https://goo.gl/L5ncag](https://goo.gl/L5ncag)
- Harada K, Ichikawa D, Konishi H, Komats S, Shiozaki A, et al. (2014) Perforation of the sigmoid colon and massive ischemia of the small intestine caused by amyloidosis associated with multiple myeloma: a case report. *Int Surg* 99: 685-690. [Link: https://goo.gl/1CkkXm](https://goo.gl/1CkkXm)
- Garay M, Bollo J, Balaque C, Tarqarone E, Trias M (2014) Gastrointestinal bleeding as a first symptom of a focal jejunal amyloidosis. *Cir Esp* 92: 696-698. [Link: https://goo.gl/eM1DLN](https://goo.gl/eM1DLN)
- Kon T, Nakagawa N, Yoshikawa F, et al. (2016) Systemic immunoglobulin light-chain amyloidosis presenting hematochezia as the initial symptom. *Clin J Gastroenterol* 9: 243-251. [Link: https://goo.gl/13Yw2U](https://goo.gl/13Yw2U)
- Maza I, Vlodaysky E, Eliakim RA (2010) Rectal bleeding as a presenting symptom of AL amyloidosis and multiple myeloma. *World J Gastrointest Endosc* 2: 44-46. [Link: https://goo.gl/ky9Tpt](https://goo.gl/ky9Tpt)
- Lim AY, Lee Jh, Jung KS, Gwag HB, Kim DH, et al. (2015) Clinical features and outcomes of systemic amyloidosis with gastrointestinal involvement: a single-center experience. *Korean J Intern Med* 30: 496-505. [Link: https://goo.gl/bSebtZ](https://goo.gl/bSebtZ)
- Oqasawara N, Kitagawa W, Obayashi K, et al. (2013) Solitary amyloidosis of the sigmoid colon featuring submucosal tumor caused hematochezia. *Intern Med* 52: 2523-2527. [Link: https://goo.gl/d6U2m4](https://goo.gl/d6U2m4)
- Audemard A, Lepennec V, Riffaut N, Ficheux M, Macro M, et al. (2013) Pseudo-tumoral intestinal amyloidosis. *QJM* 106: 1139. [Link: https://goo.gl/hfcRN8](https://goo.gl/hfcRN8)
- Kwon YH, Kim JY, Kim JH, Park HW, Yang HM, et al. (2012) A case of primary colon amyloidosis presenting as hematochezia. *Korean J Gastroenterol* 59: 44-47. [Link: https://goo.gl/iwU96a](https://goo.gl/iwU96a)
- Yau AH, Cornell IS, Cheung J (2012) Jejunal amyloidosis: a rare cause of severe gastrointestinal bleeding. *Can J Gastroenterol* 26: 320-321. [Link: https://goo.gl/MZEHYp](https://goo.gl/MZEHYp)