



James P Dworkin-Valenti*, Esmael H Amjad, Noah Stern and Samba SR Bathula

Department of Otolaryngology, Head & Neck Surgery, Detroit Medical Center, Detroit, Michigan, USA

Dates: **Received:** 04 December, 2017; **Accepted:** 28 December, 2017; **Published:** 29 December, 2017

***Corresponding author:** Dworkin-Valenti JP, Ph.D., Department of Otolaryngology, Head & Neck Surgery, Detroit Medical Center, Detroit, Michigan, USA, 5807 Cedar Ridge Dr. Ann Arbor, MIM, USA, 48103, E-mail: voicedx@yahoo.com

<https://www.peertechz.com>

Research Article

Aggressive Thyroid Gland Carcinoma: A Case Series

Abstract

In 2017 there were approximately 62000 new cases of thyroid cancer (TC) in the United States, with a death toll of less than 5%. This relatively low mortality rate is based on a grouping of all TC subtypes, which masks the small minority of patients with biologically aggressive tumors who have dismal prognoses for survival. The paper begins with a brief overview of TC variants relative to their alternative differential diagnostic characteristics, risk factors, and treatment options. We then proceed with presentations of 5 patients with different forms of aggressive TC, two of whom suffered from very rare collision tumor subtypes. Four of these individuals died of persistent disease, notwithstanding complex treatments with curative intent; the fifth patient suffers from metastatic disease and numerous postoperative morbidities. This case series highlights the significant shortcomings of current diagnostic and treatment methodologies for aggressive thyroid gland tumors. We discuss our clinical experiences with these patients, and we offer suggestions regarding methods that might facilitate early identification of aggressive TC and rational treatment decisions.

Introduction

The lifetime relative risk of developing thyroid cancer (TC) is 1.2%. According to the American Cancer Society there were 62000 new cases of TC in the United States over the past year, which accounted for 3% of all new cancer diagnoses. There is a 4:1 female to male incidence ratio. Virtually all thyroid gland tumors present as palpable neck masses that can be evaluated via fine needle aspiration procedures followed by cytological appraisal (FNAC). The vast majority of these masses are benign lesions that may or may not require intervention. When FNAC or open biopsy of a suspicious growth reveals underlying malignancy, there is a 90% chance that the diagnosis of a well-differentiated TC will be rendered [1-3]. In each case, after appropriate treatments, the long-term prognosis for disease free survival is usually very good [4,5]. Whereas the exact mechanism for malignant tissue transformation and growth remains unclear, a causal association has been shown in many individuals whose histories include X-ray treatments for tonsillitis, thymus gland edema, acne, and cancers such as Hodgkin's disease [6]. Interestingly, numerous cases of TC were reported by health authorities following the Chernobyl nuclear plant melt-down [7,8].

Papillary TC is the most common type, accounting for approximately 80% of all patients with thyroid malignancies. This tumor variant is usually slowly growing or indolent, and often only involves one lobe of the gland. Diagnosis is normally

achieved via FNAC. Treatment modalities usually include total thyroidectomy (+/- central neck dissection, +/- radioactive iodine treatment [RAI]) [9]. The histological features of the tumor and clinical presentation of the patient are important predictors, relative to treatment choice, local-regional control, and disease free survival. Tall cell, columnar cell, solid, diffuse sclerosing, and some follicular variants are considered aggressive subtypes of papillary TC. In general, patients with extra-thyroidal extension, nodal disease, and/or distant metastasis are considered to have poorer prognoses from the outset [10].

Follicular TC is the second most common (~10%) malignancy of the thyroid gland, and it usually presents as a solitary tumor. Classically, it is defined as a carcinoma with follicular cell differentiation that lacks papillary nuclear features [11]. These papillary nuclear features, when identified during pathological analysis, constitute a diagnosis of a follicular variant of papillary TC [12].

There are three subtypes of follicular TC: 1) minimally invasive without angioinvasion, 2) minimally invasive with angioinvasion, and 3) widely invasive. High risk patients are those who present with any one or more of the following conditions: over 45 years of age, tumors greater than 4 cm, extra-capsular invasion, extra-thyroidal disease, widely invasive tumor, angioinvasion, and Hurthle cell features [13]. Total thyroidectomy is usually the treatment of choice

for all high risk patients; level VI neck dissection is often recommended for those with nodal disease [14]. Because tumor invasion is only detectable at the level of the gland capsule, FNAC has a limited role in patients with follicular TC; excision biopsy is most often required for the differential diagnosis [12].

Medullary TC arises from parafollicular C-cells of the thyroid gland. This tumor type accounts for about 4% of all thyroid gland malignancies [15]. Diagnosis often is achieved via FNAC [16]. Total thyroidectomy with prophylactic or therapeutic central neck dissection (level VI) is considered the standard of care. Because this tumor subtype doesn't concentrate iodine, RAI treatment is not effective [17]. External beam radiation may be considered for those patients with postoperative residual disease and for those with distant metastasis. However, overall survival following such adjuvant therapy may not be significantly improved [18,19]. Chemotherapy is considered when surgery and/or radiation therapy are not options [20-23]. Overall, 10-year survival rate is 90% when the disease is confined to the thyroid gland; involvement of cervical lymph nodes and/or distant sites reduces this rate to 70% and 20%, respectively [24-29].

Mucoepidermoid carcinomas, sclerosing mucoepidermoid carcinomas with eosinophilia, squamous cell carcinomas, and mucinous carcinomas are considered thyroid gland epithelial tumors of uncertain cell origin [30-34]. For mucoepidermoid TC, total thyroidectomy often yields a good prognosis; the remaining epithelial subtypes often act rather aggressively with poor prognoses, irrespective of treatments rendered [35-37].

Insular thyroid gland carcinoma is a very rare entity, with recurrence/metastasis rates ranging from 20% to 60%; the 10-year mortality rate ranges from 13% to 41% [38-42]. For this subtype, total thyroidectomy plus central lymphadenectomy are often the treatments of choice; followed by prophylactic RAI, which may improve survival [43]. Anaplastic TC is another very rare disease. It is observed most often in older females and in those with preexisting goiter or follicular or papillary TC. Even with aggressive palliative treatment, this disease is almost always fatal within the first year. Surgical resection, with adjuvant chemoradiation therapy, may improve survival and quality of life [44,45].

Mixed medullary and follicular carcinomas [46,47], mixed medullary and papillary carcinomas [48], papillary and squamous cell carcinomas [49,53], and follicular and squamous cell carcinomas of the thyroid gland represent collision tumor variants [54]. These are also very rare conditions with dismal prognoses in most cases, irrespective of the traditional surgical or adjuvant treatment alternatives that may be employed for control.

When grouped together, the five year survival for all patients with TC is greater than 95%. However, when segregated, there are tumor subgroups that act very aggressively. These variants of thyroid gland malignancies are often fatal. For patients with these cancers, comprehensive diagnostic testing is of paramount importance to the formation of prompt, appropriate,

and rational treatment recommendations. Currently, most standard surgical and non-surgical approaches to management are less than effective for these unfortunate individuals.

The primary objective of this paper is to present a series of patients who were referred to our department for differential diagnoses and treatments of thyroid gland masses that were later delineated as aggressive cancers with very poor prognoses. The full work-up, treatment paradigm, clinical course, and final outcome in each case are described in detail along with a comprehensive discussion about the important pathological distinctions and similarities between commonly occurring non-aggressive thyroid carcinomas and their rare aggressive counterparts.

Methods

This investigation is based on retrospective chart reviews of 5 patients with unusually aggressive thyroid cancer variants. Specific focus during analysis of each patient's chart was placed on: 1) clinical presenting symptoms, 2) results of the physical examination, 3) thyroid ultrasound and CT and MRI scan findings, 4) preliminary cytopathology results obtained via FNAC or excisional biopsy, 5) thyroid specimen pathology post-operatively, 6) all treatments rendered, and 7) final outcomes relative to local control and disease free survival. All 5 patients were treated by board certified otolaryngologists at the Detroit Medical Center. All chart data and pathology specimens were independently analyzed by at least 2 pathologists or otolaryngologists to ensure inter-rater reliability of all results reported. When rater differences were noted, discrepant chart extractions were reviewed carefully with the outcome objective of achieving 100% inter-rater agreement for each of the pertinent study variables listed above. To be included in this case series each patient had to present initially with an abnormal thyroid mass that proved to be an unusually aggressive form of cancer; the poor clinical course and treatment outcome in each case could not have been attributable to significant co-morbid medical conditions.

Results

Charts of 5 female patients who met the previously defined inclusion criteria were comprehensively analyzed by the team of judges to assemble the data described below for each case. Inter-rater agreement achieved the benchmark of 100% for the specific focus points of this investigation, as listed earlier. Summarily, two patients were middle aged and three were elderly. Their diagnoses varied as follows: 1) well-differentiated follicular variant of papillary thyroid carcinoma with lympho-vascular and capsular invasion, 2) well-differentiated mixed papillary and follicular variant of papillary thyroid carcinoma with lympho-vascular and capsular invasion, 3) poorly differentiated insular thyroid carcinoma, 4) poorly differentiated follicular thyroid carcinoma with widely invasive malignant high grade neuroendocrine carcinoma (collision tumor), and 5) moderately well-differentiated papillary thyroid carcinoma with poorly differentiated squamous cell carcinoma (collision tumor).

Case 1

This is a 68 year old African American female who presented with a 3 month history of a left sided painful neck mass. Past medical history was negative for radiation exposure. She had breast cancer for which she had undergone a right modified radical mastectomy and adjuvant chemotherapy 12 years earlier. Social history was positive for cigarette smoking. There was no history of thyroid cancer among her family members. Clinical examination revealed a 2X2 cm lymph node in the left supraclavicular region. Due to excessive adipose neck tissue, the thyroid was not able to be appreciated. Laryngoscopic findings were normal. A neck MRI with contrast was obtained because the patient refused CT imaging. The MRI revealed a large left thyroid mass with extensive involvement of neck structures, including a tumor thrombus in the left internal jugular vein and a subcarinal lymph node. Thyroid gland core biopsy results demonstrated papillary thyroid carcinoma. A PET CT scan showed FDG avidity in the left thyroid lobe, left side of the neck, and left sacral ala. The patient refused a recommended sacral biopsy. The cancer was staged as T4bN1bMx. The Tumor Board recommendation was for adjuvant RAI after surgical management. The patient underwent a total thyroidectomy, left radical neck dissection, mediastinoscopy with mediastinal lymphadenectomy. Intra-operatively, the tumor encircled the vagus & recurrent laryngeal nerves on the left, and was tightly adhered to the left carotid artery with a concurrently thrombosed left internal jugular vein. The right thyroid gland was grossly uninvolved.

The final pathology result was consistent with a well-differentiated follicular variant of papillary thyroid carcinoma. The tumor size, localized to the left, was 5 cm in its greatest dimension with significant capsular invasion and extra-thyroidal extension, lympho-vascular invasion, and involvement of two level 2 nodes with extra-nodal extension. There was also transmural invasion of the left internal jugular vein. The right thyroid lobe was free of disease. Figure 1 illustrates the pathological features of this patient's thyroid carcinoma as described.

Post-operative videostroboscopy revealed left vocal fold paralysis, resulting in mild-moderate dysphonia, without

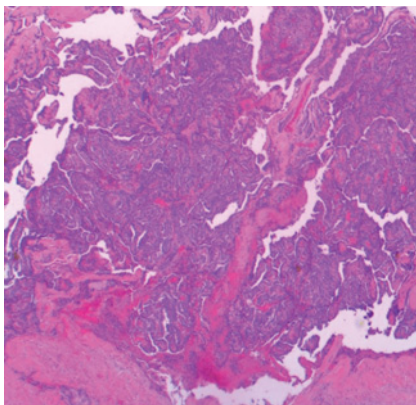


Figure 1: Well-differentiated follicular variant of papillary TC with lymphovascular and capsular invasion.

dysphagia. Two months post-operatively she received 209 mCi of I131 (RAI). Approximately 1 month after this therapy, neck ultrasonography revealed a clean thyroid bed. The patient was placed on levothyroxine therapy for hypothyroidism.

Five months post-treatment, a repeat PET-CT scan demonstrated complete response to all treatments. At 6 months post-treatment, results of a nuclear medicine whole body bone scan confirmed the absence of osseous metastatic disease. One year post-treatment the patient underwent a routine nuclear medicine thyroid scan. A subtle focal area of tracer deposition was seen in the left side of the thyroid bed, which was interpreted as residual thyroid tissue without scintigraphic evidence of distant metastasis. Three months later, however, a 2.2 cm osseous lesion in the left hemi sacrum consistent with metastatic disease was identified on MRI. Palliative radiation therapy was administered. Five months later, the patient's thyroglobulin levels were elevated, suggesting recurrence. To date, the patient struggles with persistent bone cancer metastases and vocal fold paralysis. She is on a close clinical surveillance schedule.

Case 2

This is a 55 year African American female who presented with complaints of intermittent hemoptysis for over a year. Past medical history included breast cancer 4 years prior, treated with a mastectomy and routine use of tamoxifen therapy; a small untreated goiter was diagnosed 30 years ago. Family history was negative for thyroid cancer. Her social history was positive for cigarette smoking, marijuana, and cocaine.

At initial clinical examination hemoptysis was observed with signs of respiratory distress. Physical examination revealed a diffusely enlarged goiter with multiple nodules, the greatest of which was 2 cm to the right of the isthmus. Direct laryngoscopy demonstrated mild left vocal fold paresis with a large ulcerative mass in the immediate subglottic space. This lesion was actively oozing bright red blood.

CT angiogram demonstrated multiple enhancing lymph nodes involving levels 2 through 5 on the left side, thyroid gland heterogeneous density with stippled calcifications greater in the left lobe with tracheal invasion in the upper left lateral wall region. These results were interpreted to represent thyroid carcinoma with tracheal involvement. Staging was set at T4aN1bM0.

A total thyroidectomy was performed with concurrent bilateral modified radical neck dissections and central neck dissections. The patient underwent partial tracheal resection with reconstruction, tracheostomy, and left recurrent laryngeal nerve resection.

The final pathological diagnosis was well-differentiated mixed multifocal papillary and follicular thyroid carcinoma involving most of the thyroid gland with lympho-vascular and capsular invasion; extension into adjacent tracheal perichondrium without involvement of the hyaline cartilage was also determined. Virtually all margins were positive

for residual carcinoma. Although the right internal jugular vein was pathologically negative, all dissected lymph nodes proved positive for metastatic spread. Figure 2 illustrates the cytological features of this patient's mixed thyroid carcinoma, as described.

One month postoperatively the patient underwent a nuclear medicine thyroid scan. Focal increased radiotracer uptake was noted in the thyroid bed, with increased uptake also observed in the left upper and lower neck, suggestive of positive lymph nodes. No distant metastasis was identified.

At 3 months post-operatively the patient received orally administered RAI therapy (151 mCi of I131). She was followed closely for 8 months after such treatment, and was judged to be doing well from an oncologic point of view; she did not suffer from dysphonia or dysphagia. Unfortunately, we lost her to follow-up. We were informed that she had died of cardiac arrest, approximately 16 months after the aforementioned thyroid cancer surgeries.

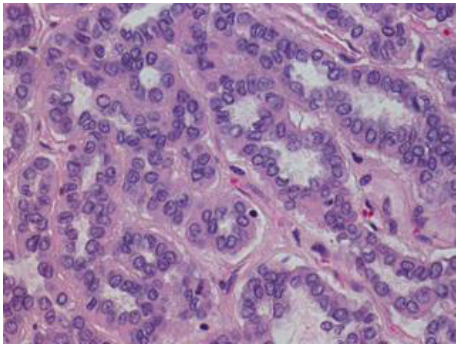


Figure 2: Well-differentiated mixed papillary and follicular variant of papillary TC with lymphovascular and capsular invasion.

Case 3

This is an 87 year old Caucasian female who initially presented to us with chief complaints of dysphonia without dysphagia. Her past medical and social history was negative for radiation exposure, smoking, illicit drugs, or alcohol abuse. There was no family history of thyroid cancer.

Upon neck examination, a firm and fixed left thyroid mass was detected. Laryngeal videostroboscopy revealed left vocal fold hypomobility and a small ectasia posteriorly. Thyroid ultrasonography illustrated an enlarged heterogeneous thyroid gland with hypervascularity and bilateral jugular vein thromboses. Neoplastic infiltration was not excluded. CT scan demonstrated a large left thyroid lobe tumor with a poorly defined outline that compressed and narrowed the proximal trachea. FNAC revealed that the thyroid mass was consistent with a well-differentiated follicular neoplasm. Staging was set at T4bN1aMx.

The patient underwent a left thyroid gland lobectomy and tracheostomy. The final pathology report converted the diagnosis to a poorly differentiated insular carcinoma of

the thyroid gland, as illustrated in figure 3. The patient was subsequently referred to radiation oncology for palliative IMRT. Unfortunately, she passed away half-way through her planned course of 24 fractions, due to respiratory distress.

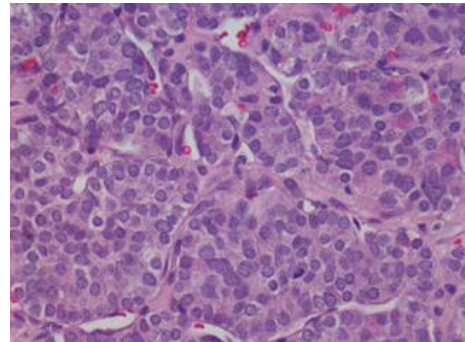


Figure 3: Poorly differentiated insular carcinoma.

Case 4

This is a 51 year old African American female who presented to our ER with stridor, dyspnea, odynophagia, and dysphonia. She felt a neck mass 4 weeks prior to her visit to the ER, which she suggested had progressively enlarged along with worsening of all symptoms. She denied fever or chills, but admitted to mild weight loss over the 4 week course of her symptoms. Her past medical history was negative for radiation exposure. Social history was negative for cigarette smoking, illicit drugs, or alcohol abuse. Family history was negative for thyroid cancer.

On physical examination a 5X5 cm firm non-tender fixed anterior neck mass without any other palpable lymphadenopathy was identified. Laryngoscopy revealed right vocal fold paralysis, left vocal fold hypomobility, glottal incompetence during phonation, and hoarse-breathy voice quality with limited phonation time. Imaging of the neck demonstrated a very large heterogeneously enhancing right neck mass that extended from the hyoid bone to the mediastinum; the trachea deviated to the left. There was no evidence of distant metastases.

In view of the patient's notable respiratory distress, fiberoptic intubation in the operating room with a # 5 size endotracheal tube was conducted to secure the airway. A tracheostomy with subtotal thyroidectomy, and bilateral modified radical neck dissections were performed. Final pathology revealed 1) widely invasive, poorly differentiated follicular carcinoma of the thyroid gland with tumor necrosis and extensive intra and extra-glandular vascular invasion, and 2) high grade neuroendocrine carcinoma, with extensive tumor necrosis and vascular invasion. These concurrent findings led to the diagnosis of a collision tumor, staged as T4aN1aM0. Figure 4 illustrates these cytological results.

The patient was presented to the Tumor Board post-operatively. Without unequivocal literature guidelines for this rare tumor subtype, concurrent chemoradiation therapy was

recommended, albeit with a guarded prognosis for local control and disease free survival. This treatment plan was enacted 3 weeks following initial surgery. After 29 fractions (3600 cGY-6MV photons) the patient died of respiratory distress, approximately 2 months after she first presented to the ER.

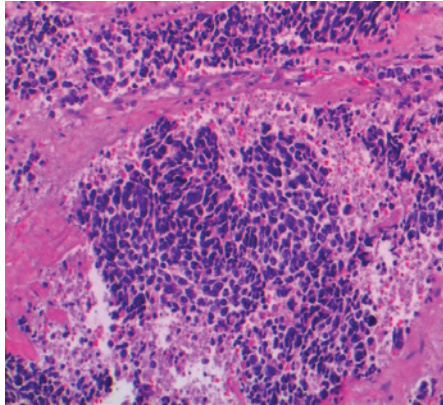


Figure 4: Poorly differentiated follicular TC with invasive malignant high grade neuroendocrine carcinoma (collision tumor).

Case 5

This is a 64 year old Caucasian female with multiple medical problems, including morbid obesity, diabetes, osteoarthritis, vertigo, congestive heart failure, and generalized pain. She presented to our ER with difficulty ambulating. Our otolaryngology service was consulted for a 4 week history of dysphagia, dysphonia, dyspnea, and 2 palpable neck masses. Her past medical history was negative for radiation exposure. Social history was negative for illicit drugs or alcohol abuse; she had quit smoking cigarettes 30 years ago.

Head and neck examination demonstrated right thyroid enlargement and right levels 3 and 5 lymphadenopathy corresponding to her palpable masses. Laryngoscopy revealed bilateral arytenoid and aryepiglottic fold edema with accompanying hypomobility of the right vocal fold. CT scan of the neck revealed a 6.7 cm mass arising from the right lobe of the thyroid gland that extended below the sternum, deviating the proximal esophagus and trachea. Jugulo-digastric lymph nodes were enlarged bilaterally; a 3 cm prominent supra-clavicular lymph node was also identified. CT scan of the chest and head did not reveal signs of thoracic or intracranial metastases. FNAC illustrated papillary thyroid carcinoma.

The patient underwent quadruple endoscopy, near total thyroidectomy, central neck dissection, and tracheostomy. Intra-operative findings included a very large infiltrating right thyroid mass that extended posteriorly to the esophagus and trachea and invaded the right thyroid cartilage. The final pathology findings of the right thyroid lobe suggested a collision tumor comprised of 1) moderately well-differentiated papillary carcinoma, and 2) poorly differentiated non-keratinizing squamous cell carcinoma, without angiolymphatic invasion. Most surgical margins were positive for tumor. Staging was set as T4N1bM0. Figure 5 demonstrates the histology of this collision tumor.

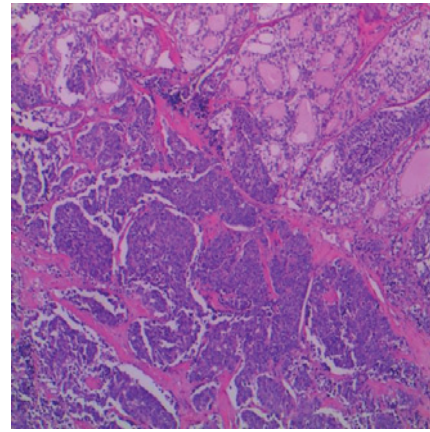


Figure 5: Moderately well-differentiated papillary TC with poorly differentiated squamous cell carcinoma (collision tumor).

At Tumor Board, consensus was reached to offer the patient concurrent chemoradiation therapy, which was started 6 weeks after the aforementioned surgeries. Four weeks later she developed dyspnea. Chest and neck CT scans revealed signs of persistent disease enlargement as well as interval development of axillary lymphadenopathy and lung masses, consistent with metastases. CT guided right lung needle biopsy revealed a high grade malignant neoplasm without cytological patterns of papillary tissue or squamous differentiation. The patient completed 24 fractions (4734cGY) of radiation therapy, but unfortunately died of respiratory distress shortly thereafter, owing to extensive primary and metastatic disease.

Discussion

Nearly 15 years ago the term poorly differentiated TC was used to describe neoplasms of the follicular thyroid epithelium that produced scattered structural cell differentiation and limited thyroglobulin, without the typical morphological characteristics of papillary or follicular well-differentiated carcinomas [39,40]. In general, poorly differentiated TCs are considered intermediate entities between well differentiated and undifferentiated TCs, but it is possible that they are genetically distinct. Unlike the generally good long-term prognoses for most well-differentiated thyroid cancers these malignancies are usually biologically aggressive with metastatic tendencies [43].

More recently, efforts to elucidate prognostic factors have focused on molecular markers. Researchers analyzed 112 patients with differentiated thyroid cancers and demonstrated that a lack of E-cadherin and Beta-Catenin predicted a poor prognosis [55]. Similarly, it has been suggested that EpCAM nuclear localization may serve as a marker for aggressive TCs [56]. This search for bio-markers draws attention to the inefficiency of current diagnostic modalities for accurate identification of aggressive thyroid gland malignancies. As with well-differentiated tumors, these rare TCs usually present as neck masses, and as such are typically evaluated via ultrasound guided FNAC. For aggressive cancerous lesions this routine evaluation technique often proves diagnostically inaccurate, insufficient, or impractical.

We elected not to perform FNAC procedures for three of our patients (Cases 1, 2, & 4). Imaging for Case 1 revealed a large thyroid mass with extensive neck and sacral disease, which required core biopsy for definitive diagnosis. Results revealed a well-differentiated follicular variant of papillary TC with significant capsular and lymphovascular invasion and extra-thyroidal extension. Although she refused evaluation of the sacral mass, she initially responded well to extensive surgical intervention and postoperative RAI for the thyroid and neck disease. Unfortunately, one year post-treatment she exhibited signs of persistent disease in the thyroid bed and bone metastasis in the hemi-sacrum region. Still alive at the time of this report, the patient continues to struggle with various medical problems, including vocal fold paralysis. Her well-differentiated TC was by no means an indolent disease entity. Rather, this common tumor variant in this case proved to be biologically aggressive and likely life threatening.

Case 2 presented with an ulcerative thyroid mass with associated airway distress, requiring emergent management in the operating room. Pathologic analysis of the excised specimen revealed a well-differentiated mixed papillary and follicular TC with lymphovascular and capsular invasion and tracheal metastasis. As with Case 1, this patient's disease was aggressive. In her case, she eventually succumbed to the disease and cardiac arrest.

Case 4 did not undergo an FNAC because she presented with a large firm and fixed thyroid mass with clinical signs of lymphadenopathy and respiratory distress. As with Case 2, emergent surgery was necessary to secure the airway via tracheotomy and treat the thyroid and neck disease. Unlike Cases 1 and 2, this patient's final pathology findings were very rare. She suffered from a collision tumor with associated necrosis and extra-glandular vascular invasion. Not unexpectedly, she died quickly from this very aggressive form of TC, despite all of the treatments rendered.

For two of our patients (Cases 3 and 5), FNAC was conducted in the usual way for differential diagnosis. Unfortunately, in each case the pathological results proved inaccurate. Initially and surprisingly, Case 3 was diagnosed with a well-differentiated follicular TC, which normally responds favorably to standard surgical management. Because this tumor type almost always requires excision biopsy for definitive diagnosis, the patient underwent a diagnostic surgery. Final specimen analysis converted the FNAC result to insular or poorly differentiated TC. Not long after surgery the patient died of disease persistence and respiratory distress.

FNAC for Case 5 suggested the diagnosis of a large well-differentiated papillary TC. She was taken to the operating room for standard thyroid and neck surgical intervention and a tracheotomy for associated dyspnea. As with Case 4, this common pathology finding was converted to a collision tumor diagnosis upon final specimen analysis. This patient also died soon after her surgery due to disease persistence and respiratory distress.

Summarily, four of our five patients (Cases 1, 2, 3 and 5)

were initially diagnosed with well-differentiated TCs, which are normally biologically non-aggressive. FNAC results for two of these individuals (Cases 3 and 5) proved inaccurate at final pathological analysis with diagnosis conversion to insular carcinoma in one case and a collision tumor in the other. These final pathology outcomes helped explain the aggressive behaviors of these masses. Three of these patients (Cases 2, 3, and 5) died soon after extensive surgical interventions, and the first one (Case 1) is riddled with numerous morbidities. In retrospect, for these cases there were a few warning signs on physical examination, FNAC, and/or initial imaging studies regarding the possibility of an underlying aggressive variant of the presenting thyroid tumors. At the outset, these included 1) age greater than 45 years, 2) primary tumor size greater than 4 cm, 3) nodal disease, and 4) metastasis. We remain uncertain that these initial findings were sufficient enough to compel us to have treated these patients more conservatively. Clearer understanding of the severity of the disease in each of these cases was only achieved intraoperatively and at final pathological specimen analyses. Had we known upfront of the aforementioned aggressive histology in Cases 3 and 5, for example, we likely would have recommended a non-surgical, ultra conservative course of management, owing to the generally dismal prognosis for insular carcinoma and collision tumors. Similarly, had we been aware of the full extent of disease in Cases 1 and 2 prior to surgery it is likely that these high risk factors, coupled to the known signs of metastasis in each case, would have clearly influenced us to consider alternative, less morbid methods of intervention.

Although Case 4 was more complicated than the other cases in this series, her course was straightforward at the outset. She was in distress when she presented to the emergency room with several respiratory symptoms. During emergency airway intervention we discovered a collision tumor. The patient died within two months of this diagnosis. For her, our reflections regarding the services we provided are not quite so concerning as those for the other four cases presented. The biologically aggressive nature of her disease was discovered almost immediately and we were unable to offer much more than comfort care once her tumor was debulked and a tracheotomy was performed.

Clinical hindsight is almost always 20/20. As such, we have learned several very important lessons from the patients in this case series. First, at the outset of examination, an aggressive TC may occasionally masquerade as a non-aggressive tumor, with histological features that initially prompt positive expectations for local control and long-term disease free survival with standard surgical and postoperative adjuvant interventions. Second, not all well-differentiated variants of TC behave non-aggressively; some may be biologically aberrant and fatal. Third, be prepared for the possibility that histological analysis of a final specimen may convert the pathological diagnosis from an originally suspected non-aggressive TC, with a very good prognosis, to a definitively aggressive tissue variant that may quickly overturn the value of the surgery just completed. This was undoubtedly true for Case 5 who died of a collision tumor after the initial diagnosis of a normally treatable, well-

differentiated papillary carcinoma. Fourth, stay focused on the patient's presenting high risk factors because these currently are our best prognostic tools, given the possible limitations of FNAC in the individual with an aggressive TC. Fifth, poorly differentiated and collision tumors of the thyroid gland usually act very aggressively, and in many instances, they are not necessarily good candidates for extensive surgical management other than techniques for securing an airway. Local regional control and long-term survival are very poor in most cases. Sixth, whereas FNAC may yield an accurate diagnosis for many thyroid gland masses, there is a subset of patients with TC whose definitive tissue diagnoses and overall prognoses require and depend upon excision biopsy and intraoperative appraisal of the full extent of the disease. This fact inherently challenges efficient and practical treatment decisions, because in such cases the risks of surgery may be greater than the anticipated benefits. Seventh, there is a strong need for more accurate diagnostic methods that can be employed reliably to differentiate all TC variants prior to decisions about treatment alternatives. These may include a) the development of various type-specific genetic and/or molecular marker analyses, b) prospective, randomized experimental investigations of novel, commercially available, gene sequencing (ThyGenX) and microRNA gene expression classifiers (ThyMIR) for additional insight into the biology of thyroid gland masses and to improve pre-operative diagnostic accuracy, c) advances in PET-CT imaging algorithms for appraisal of thyroid gland masses, d) use of 3-D CT imaging for more definitive assessment of anatomical tumor characteristics, e) enhanced ultrasound sensitivity during FNAC, f) more elaborate FNAC technology, and g) practical approaches to excisional biopsy in the clinic setting. Eighth, we must create a validated risk factor algorithm that flashes invaluable warning signs regarding the probability of an underlying aggressive thyroid gland malignancy. Information gleaned from these purported examination data will undoubtedly lead to differential surgical and non-surgical treatment protocols, consistent with the suspected tumor biology and prognosis for cure. Ninth, it does not seem rational to continue treating aggressive and non-aggressive TC using equivalent methodologies, when from the outset we can anticipate disparate outcomes. As noted above, for very aggressive disease it is imperative that prompt pathological diagnosis is reached so as to avoid unnecessary heroic surgical treatments that are not likely to result in improved survival or quality of life. Additionally, randomized, prospective experimental investigations of novel chemotherapeutic (possibly immune mediating agents, marker specific agents) and chemoradiation regimens are needed to discover efficacious treatments for aggressive TC, in lieu of extensive surgical intervention.

Finally, TC in most cases is a treatable disease with good long-term prognoses when various standard surgical and adjuvant interventions are strategically and appropriately employed. However, physicians must remain mindful of the popular biblical idiom that can be modified to apply to this subject matter: Any given patient with suspected TC may actually be a "wolf in sheep's clothing". That is to say, what may appear to be simple and manageable at the outset may

upon deeper examination prove to be quite complex and intractable in the final analysis; as was true for all five of our patients. Four died of their disease, and the fifth one struggles to date with metastatic disease and vocal fold paralysis.

Acknowledgment

We extend our sincere appreciation to Yaser Zaidi, M.D. and Dongping Shi, M.D, for their expert assistance in interpreting all pathology specimens.

References

- Cady B, Ross R (1988) An expanded view of risk group definition in differentiated thyroid carcinoma. *Surgery* 104: 947-953. [Link: https://goo.gl/THsnXs](https://goo.gl/THsnXs)
- Hay ID, Grant CS, Taylor WF, McConahey WM (1987) Ipsilateral lobectomy versus bilateral lobar resection in papillary thyroid carcinoma: a retrospective analysis of surgical outcome using a novel prognostic scoring system. *Surgery* 102: 1088-1095. [Link: https://goo.gl/PtSvR5](https://goo.gl/PtSvR5)
- Yolanda MD, Oertelabc C, Oertelabc JE (1988) Diagnosis of malignant epithelial thyroid lesions: Fine needle aspiration and histopathologic correlation. *Annals of Diagnostic Pathology* 2: 377-400. [Link: https://goo.gl/Xwpm5V](https://goo.gl/Xwpm5V)
- Shaha AR (2004) Implications of prognostic factors and risk groups in the management of differentiated thyroid cancer. *Laryngoscope* 114: 393-402. [Link: https://goo.gl/JTLb7E](https://goo.gl/JTLb7E)
- Hay ID, Taylor WF, McConahey WM (1986) A prognostic score for predicting outcome in papillary thyroid carcinoma. *Endocrinology* 119(Suppl): 1-15. [Link: https://goo.gl/SJCwPY](https://goo.gl/SJCwPY)
- Iglesias ML, Schmidt A, Ghuzlan AA, Lacroix L, et al. (2017) Radiation exposure and thyroid cancer: a review. *Arch Endocrinol Metab.* 61: 180-187. [Link: https://goo.gl/QgmjQG](https://goo.gl/QgmjQG)
- Nikiforov YE (2006) Radiation-induced thyroid cancer: what we have learned from chernobyl. *Endocr Pathol* 17: 307-317. [Link: https://goo.gl/zoKzA9](https://goo.gl/zoKzA9)
- Tronko M, Bogdanova T, Voskoboinyk L, Zurnadzy L, Shpak V, et al. (2010) Radiation induced thyroid cancer: Fundamental and applied aspects. *Exp Oncol* 32: 200-204. [Link: https://goo.gl/Lfbh31](https://goo.gl/Lfbh31)
- Popadich A, Levin O, Lee JC, et al. (2011) A multicenter cohort study of total thyroidectomy and routine central lymph node dissection for cN0 papillary thyroid cancer. *Surgery* 150: 1048-57. [Link: https://goo.gl/ef4LwK](https://goo.gl/ef4LwK)
- Yu XM, Wan Y, Sippel RS, Chen H (2011) Should all papillary thyroid microcarcinomas be aggressively treated? An analysis of 18,445 cases. *Ann Surg* 254: 653-60. [Link: https://goo.gl/WiVtpj](https://goo.gl/WiVtpj)
- Sobrinho Simões M, Asa SL, Kroll TG, et al. (2004) Follicular carcinoma. In: DeLellis RA, Lloyd RV, Heitz PU and Eng C (eds). *WHO Classification of Tumors. Pathology and Genetics. Tumours of Endocrine Organs.* IARC Press: Lyon, France 67-76. [Link: https://goo.gl/8PTkor](https://goo.gl/8PTkor)
- Sobrinho-Simões M, Eloy C, Magalhães J, Lobo C, Amaro T (2011) Follicular thyroid carcinoma. *Modern Pathology* 24: S10-S18. [Link: https://goo.gl/oc26rc](https://goo.gl/oc26rc)
- Grebe SK, Hay ID (1995) Follicular thyroid cancer. *Endocrinology and Metabolism Clinics of North America* 24: 761-801. [Link: https://goo.gl/4Xpizb](https://goo.gl/4Xpizb)
- Mitchell AL, Gandhi A, Scott-Coombes D, Perros P (2016) Management of thyroid cancer. *J Laryngol Otol* 130(Suppl 2): S150-S160. [Link: https://goo.gl/jSePvH](https://goo.gl/jSePvH)
- Hundahl SA, Cady B, Cunningham MP, Mazzaferri E, et al. (2002) Initial

- results from a prospective cohort study of 5583 cases of thyroid carcinoma treated in the united states during 1996. *Cancer* 89: 202-217. [Link: https://goo.gl/Y6xkTn](https://goo.gl/Y6xkTn)
16. Mehdi G, Maheshwari V, Ansari HA, Sadaf L, Khan MA (2010) FNAC diagnosis of medullary carcinoma thyroid: A report of three cases with review of literature. *J Cytol* 27: 66–68. [Link: https://goo.gl/wYkj6Y](https://goo.gl/wYkj6Y)
 17. Wu LS, Roman SA, Sosa JA (2011) Medullary thyroid cancer: an update of new guidelines and recent developments. *Curr Opin Oncol* 23: 22-27. [Link: https://goo.gl/8SQ5t](https://goo.gl/8SQ5t)
 18. (2010) Author manuscript available in PMC 2011 Aug 1. Adjuvant External Beam Radiation for Medullary Thyroid Carcinoma. *J Surg Oncol* 102: 175–178. [Link: https://goo.gl/v2EUDs](https://goo.gl/v2EUDs)
 19. Brierley JD, Tsang RW (1996) External radiation therapy in the treatment of thyroid malignancy. *Endocrinol Metab Clin North Am* 25: 141–157. [Link: https://goo.gl/uKpcLK](https://goo.gl/uKpcLK)
 20. Wells SA, Robinson RF, Gagel H, Dralle JA, et al. (2010) Vandetanib (VAN) in locally advanced or metastatic medullary thyroid cancer (MTC): A randomized, double-blind phase III trial (ZETA). *J Clin Oncol* 28: (suppl: abstr 5503. [Link: https://goo.gl/9fXDNb](https://goo.gl/9fXDNb)
 21. Wells SA, Robinson BG, Gagel RF, Dralle H, et al. (2012) Vandetanib in patients with locally advanced or metastatic medullary thyroid cancer: a randomized, double-blind phase III trial. *J Clin Oncol* 30: 134-141. [Link: https://goo.gl/BbDqts](https://goo.gl/BbDqts)
 22. Solomon B, Rischin D (2012) Progress in molecular targeted therapy for thyroid cancer: vandetanib in medullary thyroid cancer. *J Clin Oncol* 30: 119-121. [Link: https://goo.gl/Eynzfn](https://goo.gl/Eynzfn)
 23. Schoffski P, Elisei R, Muller S, Brose MS, et al. (2012) An international, double-blind, randomized, placebo-controlled phase III trial (EXAM) of cabozantinib (XL184) in medullary thyroid carcinoma (MTC) patients with documented RECIST progression at baseline. Presented at the American Society of Clinical Oncology (ASCO) 2012 Annual Meeting. June 1-5, 2012, Chicago, IL [Link: https://goo.gl/tJhUN6](https://goo.gl/tJhUN6)
 24. Modigliani E, Cohen R, Campos JM, et al. (1988) Prognostic factors for survival and for biochemical cure in medullary thyroid carcinoma: results in 899 patients. The GETC Study Group. Groupe d'etude des tumeurs a calcitonine. *Clin Endocrinol (Oxf)* 48 :265–273. [Link: https://goo.gl/52JVVD](https://goo.gl/52JVVD)
 25. Bhattacharyya N (2003) A population-based analysis of survival factors in differentiated and medullary thyroid carcinoma. *Otolaryngol Head Neck Surg* 128: 115–123. [Link: https://goo.gl/PAKLGw](https://goo.gl/PAKLGw)
 26. Kebebew E, Greenspan FS, Clark OH, et al. (2005) Extent of disease and practice patterns for medullary thyroid cancer. *J Am Coll Surg* 200: 890–896. [Link: https://goo.gl/bsnTE8](https://goo.gl/bsnTE8)
 27. Hundahl SA, Fleming ID, Fremgen AM, Menck HR (1988) A National Cancer Data Base report on 53,856 cases of thyroid carcinoma treated in the U.S. 1985–1995. *Cancer* 83: 2638–2648. [Link: https://goo.gl/qhWupr](https://goo.gl/qhWupr)
 28. Esik O, Tusnady G, Tron L, et al. (2002) Markov model-based estimation of individual survival probability for medullary thyroid cancer patients. *Pathol Oncol Res* 8: 93–104. [Link: https://goo.gl/LG91by](https://goo.gl/LG91by)
 29. Leboulleux S, Travagli JP, Caillou B, et al. (2002) Medullary thyroid carcinoma as part of a multiple endocrine neoplasia type 2B syndrome: influence of the stage on the clinical course. *Cancer* 94: 44–50. [Link: https://goo.gl/DV8RGw](https://goo.gl/DV8RGw)
 30. Zimmer PW, Wilson D, Bell N (2003) Primary squamous cell carcinoma of the thyroid gland. *Mil. Med* 168: 124–125. [Link: https://goo.gl/ozixqh](https://goo.gl/ozixqh)
 31. Korovin GS, Kuriloff DB, Cho HT, Sobol SM (1989) Squamous cell carcinoma of the thyroid: a diagnostic dilemma. *Ann Otol Rhinol Laryngol* 98: 59–65. [Link: https://goo.gl/2my1Dh](https://goo.gl/2my1Dh)
 32. Tunio MA, Al Asiri M, Fagih M, Akasha R (2012) Primary squamous cell carcinoma of thyroid: a case report and review of literature. *Head Neck Oncol* 4: 8. [Link: https://goo.gl/GXvYVL](https://goo.gl/GXvYVL)
 33. Jang JY, Kwon KW, Kim SW, Youn I (2014) Primary squamous cell carcinoma of thyroid gland with local recurrence: ultrasonographic and computed tomographic findings. *Ultrasonography* 33: 143-148. [Link: https://goo.gl/kishVE](https://goo.gl/kishVE)
 34. Chan JK, Albores-Saavedra J, Battifora H, Caracangiu ML, Rosai J (1991) Sclerosing mucoepidermoid thyroid carcinoma with eosinophilia. A distinctive low-grade malignancy arising from the metaplastic follicles of Hashimoto's thyroiditis. *Am J Surg Pathol* 15: 438-448. [Link: https://goo.gl/oy5qBA](https://goo.gl/oy5qBA)
 35. Chen KH, Chou YH, Cheng AL (2012) Primary squamous cell carcinoma of the thyroid with cardiac metastases and right ventricle outflow tract obstruction. *J Clin Oncol* 30: e260–e263. [Link: https://goo.gl/B7GtMg](https://goo.gl/B7GtMg)
 36. Syed MI, Stewart M, Syed S, Dahill S, et al. (2011) Squamous cell carcinoma of the thyroid gland: primary or secondary disease? *J. Laryngol. Otol* 125: 3–9. [Link: https://goo.gl/w6LeRY](https://goo.gl/w6LeRY)
 37. D'Antonio A, Adesso M, De Dominicis G, Boscaio A, et al. (2007) Mucinous carcinoma of thyroid gland. Report of a primary and a metastatic mucinous tumour from ovarian adenocarcinoma with immunohistochemical study and review of literature. *Virchows Arch* 451: 847-851. [Link: https://goo.gl/izTCd3](https://goo.gl/izTCd3)
 38. Carcangiu ML, Zampi G, Rosai J (1984) Poorly differentiated (“insular”) thyroid carcinoma. A reinterpretation of Langhans’ “wuchernde struma.” *Am J Surg Pathol* 8: 655–668. [Link: https://goo.gl/H6SsM9](https://goo.gl/H6SsM9)
 39. Flynn SD, Formann BH, Stewart AF, Kinder BK (1988) Poorly differentiated (insular) carcinoma of the thyroid gland: an aggressive subset of differentiated thyroid neoplasms. *Surgery* 104: 963–970. [Link: https://goo.gl/SxzJEO](https://goo.gl/SxzJEO)
 40. Papotti M, Botto MF, Favero A, Palestini N, Bussolati G (1993) Poorly differentiated thyroid carcinomas with primordial cell component. *Am J Surg Pathol* 17: 291–301. [Link: https://goo.gl/1MXpX5](https://goo.gl/1MXpX5)
 41. Killeen RM, Barnes L, Waston CG, Marsh WL, et al. (1990) Poorly differentiated (“insular”) thyroid carcinoma. *Arch Otol Head Neck Surg* 116: 1082–1086.
 42. Albareda M, Puig-Domingo M, Wengrowicz S, et al. (1988) Clinical forms of presentation and evolution of diffuse sclerosing variant of papillary carcinoma and insular variant of follicular carcinoma of the thyroid. *Thyroid* 8: 385–391. [Link: https://goo.gl/S8CEdT](https://goo.gl/S8CEdT)
 43. Pellegriti G, Giuffrida D, Scollo S, Vigneri R, et al. (2002) Long-Term Outcome of Patients with Insular Carcinoma of the Thyroid The Insular Histotype Is an Independent Predictor of Poor Prognosis. *Cancer* 95: 2076-2085. [Link: https://goo.gl/DSasdz](https://goo.gl/DSasdz)
 44. Mohebbati A, Dilorenzo M, Palmer F, Patel SG, et al. (2014) Anaplastic thyroid carcinoma: A 25-year single-institution experience. *Ann. Surg. Oncol* 21: 1665–1670. [Link: https://goo.gl/2ZokgX](https://goo.gl/2ZokgX)
 45. Brignardello E, Palestini N, Felicetti F, Castiglione A, et al. (2014) Early surgery and survival of patients with anaplastic thyroid carcinoma: Analysis of a case series referred to a single institution between 1999 and 2012. *Thyroid*. [Link: https://goo.gl/GvHY1M](https://goo.gl/GvHY1M)
 46. Kostoglou-Athanassiou I, Athanassiou P, Vecchini G, Gogou L, Kaldrymides P (2004) Mixed medullary-follicular thyroid carcinoma: report of a case and review of the literature. *Hormone Research* 61: 300–304. [Link: https://goo.gl/T3RKXF](https://goo.gl/T3RKXF)
 47. Luboshitzky R, Dharan M (2004) Mixed follicular-medullary thyroid carcinoma: a case report. *Diagnostic Cytopathology* 30: 122–124. [Link: https://goo.gl/kgsAKL](https://goo.gl/kgsAKL)

48. Hasney CP, Amedee RG (2010) Mixed medullary-papillary carcinoma of the thyroid: A case report. *Laryngoscope* 120(Suppl 4): S153. [Link: https://goo.gl/vA3ENj](https://goo.gl/vA3ENj)
49. Sarda AK, Bal S, Arunabh, Singh MK, Kapur MM (1988) Squamous cell carcinoma of the thyroid. *J Surg Oncol* 39:175–178. [Link: https://goo.gl/tCQ7pX](https://goo.gl/tCQ7pX)
50. Simpson WJ, Carruthers J (1988) Squamous cell carcinoma of the thyroid gland. *Am J Surg* 156: 44–46. [Link: https://goo.gl/7tLvT8](https://goo.gl/7tLvT8)
51. Shimaoka K, Tsukada Y (1980) Squamous cell carcinomas and adenosquamous carcinomas originating from the thyroid gland. *Cancer* 46: 1833–1842. [Link: https://goo.gl/nyTJEo](https://goo.gl/nyTJEo)
52. Cook AM, Vini L, Harmer C. Squamous cell carcinoma of the thyroid: outcome of treatment in 16 patients. *Eur. J. Surg. Oncol.* 1999;25:606–609. [Link: https://goo.gl/Mr5uRj](https://goo.gl/Mr5uRj)
53. Kleer CG, Giordano TJ, Merino MJ (2000) Squamous cell carcinoma of the thyroid: an aggressive tumor associated with tall cell variant of papillary thyroid carcinoma. *Mod. Pathol* 13:742–746. [Link: https://goo.gl/qP8rAS](https://goo.gl/qP8rAS)
54. Son DH, Roh JL, Cho KJ (2014) Combined Squamous Cell Carcinoma and Follicular Carcinoma of the Thyroid. *Korean J Pathol* 48: 418–422. [Link: https://goo.gl/QGwse1](https://goo.gl/QGwse1)
55. Ivanova K, Ananiev J, Aleksandrova E, Ignatova MM, Gulubova M (2017) Expression of E-Cadherin/Beta-Catenin in Epithelial Carcinomas of the Thyroid Gland. *Open Access Maced J Med Sci* 5: 155–159. [Link: https://goo.gl/3Vgx48](https://goo.gl/3Vgx48)
56. Ralhan R, Cao J, Lim T, MacMillan C, et al. (2010) EpCAM nuclear localization identifies aggressive Thyroid Cancer and is a marker for poor prognosis. *BMC Cancer* 10: 331. [Link: https://goo.gl/3w5LK6](https://goo.gl/3w5LK6)