

Musuraca Gerardo^{1*}, Agostoni Pierfrancesco², Boldi Emiliano³, Terraneo Clotilde⁴, Imperadore Ferdinando¹ and Del Greco Maurizio¹

¹Division of Cardiology, S. Maria del Carmine Hospital, Rovereto, Italy

²Division of Cardiology, University Medical Center Utrecht, Utrecht, Netherlands

³Division of Cardiology, Clinica S. Rocco di Franciacorta, Ome, Italy

⁴Division of Cardiology, Policlinico Hospital, Monza, Italy

Dates: Received: 27 July, 2015; Accepted: 14 August, 2015; Published: 17 August, 2015

***Corresponding author:** Dott Gerardo Musuraca, Division of Cardiology, S Maria del Carmine Hospital, 38068 Rovereto (TN), Italy, Tel: 0039 0464 403428; E-mail: musuraca@yahoo.it

www.peertechz.com

ISSN: 2455-2976

Case Report

Mitral Valve Obstruction and Pulmonary Hypertension Caused by a Giant Left Atrial Myxoma Prolapsing in the Left Ventricle

Abstract

Atrial myxomas are the most common primary cardiac tumors to diagnose. They are benign and have variable presentation. They have an excellent prognosis following surgical excision. We report a case of a 60 year old female who presented with initial signs of both right and left heart failure, fever and cough. Auscultation of the heart revealed an apical mid diastolic murmur. Trans-thoracic and trans-esophageal echocardiography revealed a pedunculated, giant left atrial myxoma that prolapsed through the mitral valve into the left ventricle in diastole producing functional mitral valve stenosis. The patient underwent a successful surgical excision of the tumor. The diagnosis and management of atrial myxomas is here reviewed.

Learning Objective

Atrial myxomas are benign and have variable presentation. They have an excellent prognosis following complete surgical excision if the diagnosis is early.

Objective

The diagnosis and management of atrial myxomas is here reviewed.

Introduction

Atrial myxomas are the most common primary cardiac tumors to diagnose. They are benign and have variable presentation. They have an excellent prognosis following surgical excision. We report a case of a 60 year old female who presented with initial signs of both right and left heart failure, fever and cough. Auscultation of the heart revealed an apical mid diastolic murmur. Trans-thoracic and trans-esophageal echocardiography revealed a pedunculated, giant left atrial myxoma that prolapsed through the mitral valve into the left ventricle in diastole producing functional mitral valve stenosis. The patient underwent a successful surgical excision of the tumor. The diagnosis and management of atrial myxomas is here reviewed.

Case Report

We describe a case of an unusually giant left atrial myxoma in a 60-year-old woman that led to pulmonary hypertension and mimicking mitral valve functional obstruction. Shortness of breath, easy fatigability with minimal exertion, chest pain or other symptoms were absent in our case. Trans-thoracic (TTE) and trans-esophageal echocardiogram (TEE) revealed a left atrial (LA) giant mass attached to the atrial septum (Figures 1-3) obstructing flow at the level of the mitral valve during diastole, moderate pulmonary hypertension

and normal left ventricular systolic function. The patient underwent surgery with cardiopulmonary bypass under moderate systemic hypothermia, with a tumor measuring 7.6 x 5 x 3.2 cm (Figure 1) resected via a trans-septal approach, following which the septum was reconstructed with a Dacron patch. Post-operative course was uneventful and the patient was discharged one week later. Pathology report confirmed atrial myxoma.

Discussion and Conclusions

Metastases (most commonly from the lung, breast, melanoma, lymphomas and leukemias) are responsible for the majority of cardiac

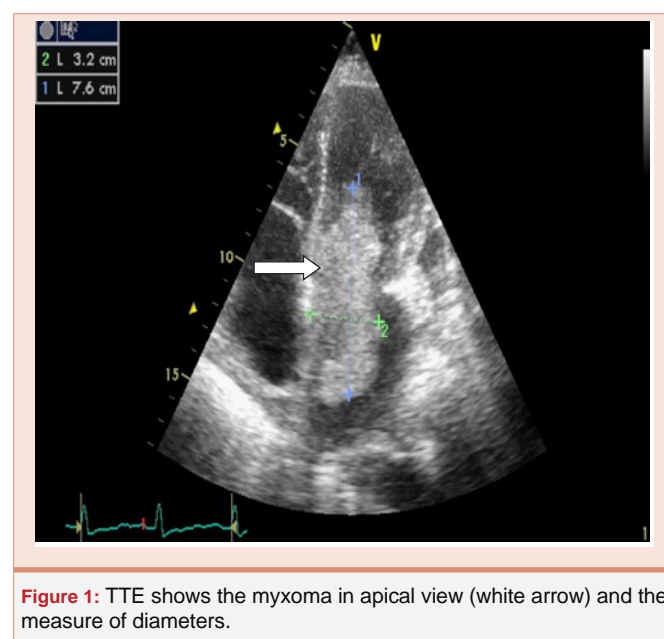


Figure 1: TTE shows the myxoma in apical view (white arrow) and the measure of diameters.

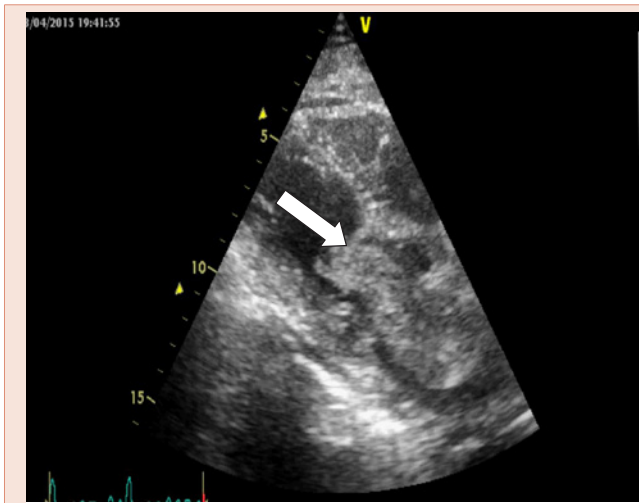


Figure 2: TTE shows the myxoma in parasternal view protruding (white arrow) in left ventricular chamber and mimicking functional valvular stenosis.

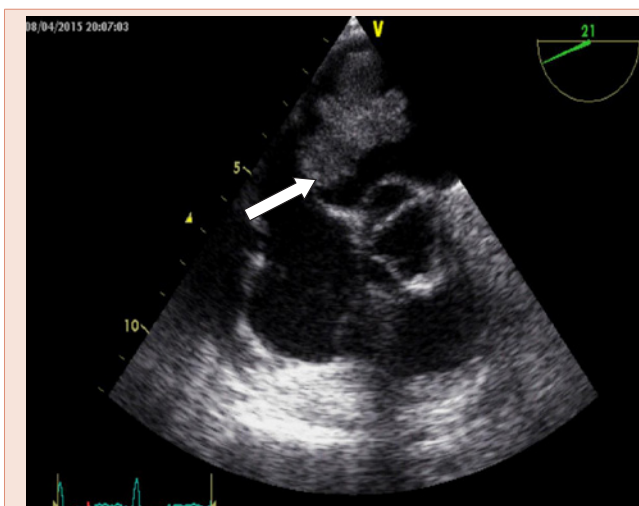


Figure 3: TEE shows the atrial mass attached to the left side of atrial septum.

tumors [2-4]. Primary tumors are relatively rare in the heart and most of them are benign. Myxomas are the most common accounting for about 50% of all primary tumors and 75% of all benign tumors. Atrial myxoma is a tumor of the heart that occurs primarily in the LA [1]. The clinical signs and symptoms may be aspecific. The size of the tumor differs widely among patients but generally ranges from 2 to 6 cm. Depending on the size and location, it may cause mitral valve

functional obstruction and pulmonary hypertension. Seventy five percent of mixomas are found in the LA and most present between the third and sixth decade of life, with 75% of patients being female. Similar to ours, all patients in reported surgical series [5-7] were symptomatic and presented with one or more triad of constitutional, embolic or obstructive manifestations.

In reviewing some of the largest surgical series, Lukacs et al. [5], over a 20 year period operated on 50 myxomas, with 42 (84%) in the LA, and operative mortality of 10% primarily from low cardiac output syndrome. Hanson et al. [6] with a 24 year review of 33 patients with atrial myxomas reported 3% mortality from tumor emboli to the coronary circulation. Similarly, Cleveland et al. [7] 15 years review of 20 patients with cardiac tumors reported 10% mortality. There was a preponderance of females in the three series but there was no racial breakdown.

Myxomas are easily diagnosed by echocardiogram, with trans-esophageal echocardiogram (TEE) nearly 100% sensitive. Without echocardiogram they can be misdiagnosed as mitral valve disease, dilated cardio-myopathy, pulmonary emboli, transient ischaemic attack or cerebro-vascular accident [7]. In conclusion, the treatment of choice for myxomas is surgical removal, and this is usually curative. After the diagnosis has been established, surgery should be performed in a short time frame because of the possibility of embolic complications or sudden death [8]. The prognosis is excellent with reported surgical mortality rates ranging from 3% to 7-10% [9].

References

1. MacGee W (1991) Metastatic and Invasive tumours involving the heart in a geriatric population: A necropsy study. *Virchows Arch-A pathol Anat Histopathol* 419: 183-189.
2. Bulkley BH, Hutchins GM (1979) Atrial Myxomas: A fifty year review. *Am Heart J* 97: 639-643.
3. Livi U, Bortolotti U, Milano A, Valente M, Prandi A, et al. (1984) Cardiac Myxomas: Results of 14 years experience. *Thorac Cardiovasc Surg* 32: 143-147.
4. St John Sutton MG, Mercier LA, Giuliani ER, Lie JT (1980) Atrial Myxomas: A review of clinical experience in 40 patients. *Mayo. Clin. Proc* 55: 371-376.
5. Lukács L, Lengyel M, Szedő F, Haán A, Nagy L, et al. (1997) Surgical treatment of Cardiac myxomas: 20 year follow up. *Cardiovasc Surg* 5: 225-228.
6. Hanson EC, Gill CC, Razavi M, Loop FD (1985) The surgical treatment of Atrial Myxomas. Clinical experience and late results in 33 patients. *J. Thorac. Cardiovasc Surg* 89: 298-303.
7. David C Cleveland, Stephen Westaby, Robert B Karp (1983) Treatment of Intra atrial Cardiac Tumours: *JAMA* 249: 2799-2802.
8. Mundi A (2009) Large atrial myxoma. *N Engl J Med* 26: 361.
9. Nwilo J, Oludara M, Adebola P (2011) Left atrial Myxoma: case report and Literature Review. *East African Medical Journal* Vol. 88: 71-72.

Copyright: © 2015 Gerardo M, et al. This is an open-access article distributed under the terms of the Creative Commons Attribution License, which permits unrestricted use, distribution, and reproduction in any medium, provided the original author and source are credited.

Citation: Gerardo M, Pierfrancesco A, Emiliano B, Clotilde T, Ferdinando I, et al. (2015) Mitral Valve Obstruction and Pulmonary Hypertension Caused by a Giant Left Atrial Myxoma Prolapsing in the Left Ventricle. *J Cardiovasc Med Cardiol* 2(2): 016-017. DOI: 10.17352/2455-2976.000015