

## Review Article

# A review on Cone Beam Computed Tomography in dentistry

Nimeshkumar Patel<sup>1\*</sup> and Ekta Mistry<sup>2</sup>

<sup>1</sup>Assistant Professor, Department Oral Medicine and Radiology, Goenka Research Institute of Dental Sciences, Gujarat University, India

<sup>2</sup>Assistant Professor, Department of Oral and Maxillofacial Surgery, College of Dental Science and Research Center, Gujarat University, India

**Received:** 28 October, 2021

**Accepted:** 03 November, 2021

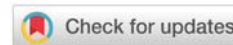
**Published:** 05 November, 2021

**\*Corresponding author:** Nimeshkumar Patel, Ass. Prof, Department Oral Medicine and Radiology, Goenka Research Institute of Dental Sciences, Gujarat University, India, Tel: +91-9925153833, +91-7016993042; E-mail: nimesh590@gmail.com

**Keywords:** Cone Beam Computed Tomography; Three dimensional radiographs; Dentistry; Dental radiography; X-rays; Oral imaging

**Copyright Licence:** © 2021 Nimeshkumar P, et al. This is an open-access article distributed under the terms of the Creative Commons Attribution License, which permits unrestricted use, distribution, and reproduction in any medium, provided the original author and source are credited.

<https://www.peertechzpublications.com>



## Abstract

**Introduction:** Cone Beam Computed Tomography (CBCT) has transformed the manner in which radiological evaluation is performed.

**Methods:** This article discusses the different aspects of CBCT, common dental applications of CBCT for diagnosis and treatment in different dental specialties from the current literature.

**Results:** CBCT has been widely accepted into different dental practices. The main reasons are the decreased size, low cost, less exposure to radiation as compared to computed tomography. CBCT enables the three dimensional assessment of the region of maxilla, mandible, cranium, and associated structures.

**Conclusions:** Dentists and dental specialists can utilize three dimensional radiography- CBCT for a comprehensive diagnosis. CBCT can also help in identifying the structures such as root canals, bifurcated canals, supernumerary teeth, impacted teeth in different planes and thus are a valuable tool for dental treatment planning.

## Abbreviations

CBCT: Cone Beam Computed Tomography; CT: Computed Tomography; MARPE: Mini-Screw Assisted Rapid Palatal Expansion; TMJ: Temporomandibular Joint

## Introduction

Cone beam computed tomography is a three dimensional radiograph used in dental diagnosis and treatment planning. CBCT shows the head and neck structures without overlap which enables the radiologist to identify the landmarks clearly. Even though CBCT is routinely used in dentistry today, the development of CBCT has taken several years to arrive at this stage. It all started with the discovery of x-rays by Wilhelm Roentgen in the late 1800s [1]. In addition to clinical examination of tissues, clinicians used radiological examination to support

their diagnosis. The imaging technology for two dimensional radiographs were developed to identify the dental structures. However, as the dental structures are three dimensional and they are projected in only two dimensions, there are limitations in two dimensional radiographs [1,2]. One major limitation is the rotation of the head movement while recording the radiographs. It was reported by Mehta et al. comparing CBCT and two dimensional radiographs that the rotation of head structures can lead to difference in the measurements performed with two dimensional radiographs [3]. With this discovery and report, the way diagnostic imaging was performed in dentistry changed completely. It was realized after this study that even in seemingly normal two dimensional radiographs, the rotational position of head and neck can be different affecting the diagnosis negatively [3]. Three dimensional radiography on the other hand does not show such errors due to head position

as it can be changed even after the recording of the radiograph. Before CBCT was developed, two dimensional radiographs were the norm. Later on, developments in the radiological field led to the development of computed tomography which is a three dimensional radiograph.

Computed Tomography (CT) utilizes the principle of transverse axial scanning which results in the three dimensional image [1]. However, CT had limitations such as high cost, limited access, and most of all high radiation to the patient. Therefore, developments were made in dental radiography resulting in the development of CBCT [2]. CBCT was developed by Arai et al. in Japan and Mozzo et al. in Italy working independently [4-6]. CBCT was mainly developed for three dimensional evaluations for dental examinations. In Contrast to CT, CBCT is recorded with a cone-shaped beam of x-rays and a reciprocating solid state flat-panel detector. The detector rotates around the patient either by 180° or 360° once and records the field of view rather than a slice by slice imaging performed in conventional CT [7]. CBCT can be recorded with different field of view such as limited volume for local CBCT to evaluate impacted canines, or one arch or the whole face. A single scan rotation of CBCT reduces the absorbed x-ray dose from 6 to 15 times as compared to CT. CBCT has decreased cost compared to CT scans and allows for a greater accuracy for diagnostic imaging compared to two dimensional radiographs. CBCT is nowadays used in multiple dental fields by clinicians, academicians, and researchers because of the advantages and ease of use [8]. Currently, with the help of artificial intelligence, automated measurements are performed for two dimensional radiographs [9]. In the future, with the help of artificial intelligence, automated measurements and evaluation of CBCT would also become possible.

## Materials and methods

The current available dental literature on Cone beam computed tomography was searched and the information was compiled to provide a comprehensive review of the topic. This article discusses the different aspects of CBCT, common dental applications of CBCT for diagnosis and treatment in different dental specialties from the current literature.

## Results and discussion

### CBCT and implants

The dental implants inserted into the areas of missing teeth in maxillary or mandibular arch necessitate an accurate evaluation of the implant site. To insert the implants successfully, an appropriate assessment of the available bone is imperative [10]. In addition, it should be noted that the dental implant is away from the vital structures such as nerves, artery, or adjacent teeth. For the comprehensive assessment of dental structures related to implants, radiological examination is necessary in addition to the clinical examination [11]. Two dimensional radiographs do not provide adequate information regarding dental implant insertion. Today CBCT is the most popular choice for the evaluation of implant insertion site [12]. CBCT enables the identification of nerve structures such as

the inferior alveolar nerve course through the mandible [13]. This provides valuable information regarding where to place the implant so that it is at a safe distance from the nerve. The use of CBCT has decreased the amount of failures in dental implants and also enable to safely insert implants without damaging vital structures. In case of bone grafting, CBCT can also be used to analyze the bone graft and implant location after the procedure is completed.

### CBCT and oral surgery

CBCT is extensively used in the field of oral and maxillofacial surgery. In the even of injury to oral and maxillofacial structures, CBCT can provide precise assessment of the surface continuity and distances between the different surfaces [14]. In case of orbital fractures, midfacial fractures, mandibular fractures, and dentoalveolar fractures CBCT can provide valuable information for comprehensive evaluation of the fractures [15-17]. In addition, it allows intraoperative evaluation of the bones during the surgical procedure. After the surgical procedures are completed, CBCT also provides valuable information for post fracture evaluation. CBCT allows the location of pathologies such as odontogenic tumors, cysts, osteomyelitis, calcifications [18,19]. Incidental findings observed on CBCT are much higher than those observed on the two dimensional radiographs. CBCT allows the inspection of unerupted teeth, impacted teeth, supernumerary teeth [20,21].

### Cbct and orthodontics

CBCT allows the orthodontist to evaluate the hard and soft tissues of face in lateral cephalometric view as well as frontal posteroanterior view as well as panoramic view. It provides the images without magnification which allows the orthodontist to perform superimposition of images without distortion [22]. CBCT can also be used to evaluate the thickness and density of palatal bone, ramal bone, buccal bone for the application of mini implants in orthodontics. In recent years, aligners have gained wide popularity in the orthodontic field. This is because of their esthetic appearance as compared to fixed orthodontic appliances. With the advanced understanding of aligners, even complex tooth movements can now be undertaken with aligner therapy [23]. However, some authors question that with aligners, only crown tipping movement occurs and the roots are not moved effectively [24]. Therefore, in a few studies, attempts have been made to use CBCT before aligner treatment to identify the root and bone structure and design treatment for better outcomes [25]. In addition, CBCT can allow the measurements of airway volume of patients [26]. The effects of orthodontic intervention such as rapid palatal expansion and mini implant supported rapid palatal expansion can be investigated with the help of CBCT [26-28]. CBCT can also be used for the evaluation of facial growth as well as discrepancies in dental eruption, especially with patients with Class III malocclusion and orthodontic treatment [29,30].

An important aspect of the evaluation of CBCT is the treatment planning. Many surgical methods and virtual treatment planning software have been developed after CBCT was widely adopted. CBCT allows the three dimensional

simulation of maxillary and mandibular surgery in orthodontic patients. This is an important breakthrough in the recent years as the surgical treatment is planned virtually in three dimensions for maxillary and mandibular advancement, rotation as well as yaw correction [31]. Maxillary downfracture and mandibular setback can also be performed with ease in three dimensional surgical simulations with CBCT due to the generation of computer designed splint [32].

In addition to treatment planning, evaluation of treatment outcomes such as root resorption is critical in identifying the negative sequelae of orthodontic treatment. With animal studies, this can be done easily with micro-Computed Tomography (micro-CT) which has very high resolution and allows the calculation of root volume after tooth movement [33]. In clinical studies, micro CT cannot be performed, but the technological advances in the resolution of CBCT has enabled researchers to evaluate the volumetric root resorption after orthodontic treatment [34]. Most common teeth to undergo root resorption with orthodontic treatment have been identified to be maxillary incisors [35]. Therefore, CBCT is an important tool not only for diagnosis and treatment planning but also for evaluating treatment outcomes.

### CBCT and TMJ

CBCT provides accurate evaluation of three dimensional images of Temporomandibular Joint (TMJ). It allows the evaluation of condyle, glenoid fossa, and surrounding structures. CBCT can be viewed with multiplanar reconstruction images in axial images, sagittal images, and coronal images. The joint spaces can be visualized in the cross-sectional slices. CBCT can be a useful diagnostic modality for cases with asymmetry to visualize and compare the right TMJ with the left TMJ. It also allows the location of the mandibular condyle within the glenoid fossa. This can be helpful in identifying the potential problems with disc and dislocations of joint [36]. The effects of orthodontic interventions such as mandibular advancement on the TMJ can be evaluated with the help of CBCT [37]. Additionally, the effects of orthodontic expansion procedures such as mini implant supported rapid palatal expansion (MARPE) on the TMJ can be evaluated with the help of CBCT [38]. CBCT is useful for assessment of developmental anomalies of condyle, trauma of mandible and TMJ, ankylosis, cortical erosion and osteoarthritic changes in the condyle [39].

### CBCT and endodontics

CBCT has been reported to be better than two dimensional radiographs in the diagnosis of periapical lesions. It allows the visualization of lesions close to maxillary sinus as well involvement of membrane of maxillary sinus and proximity to mandibular canal [40]. For endodontic purposes, a small volume CBCT can be recorded. It allows the evaluation of root canals in the teeth and allows a complete evaluation of the course of the canal with the curves and bifurcation [40]. CBCT can be helpful in establishing working length of the root canal while performing endodontic procedures [41]. In addition, CBCT has helped in increasing the success rates of endodontic treatment as it helps in identification of accessory root canals.

It can also be useful for diagnosis of root resorption, whether it is in internal root resorption or external root resorption. CBCT has been instrumental in identification of pulp horn extensions in talons cups. This allows the clinician to recognize the extent to which the talons cusps can be recontoured.

### Artificial intelligence

The assessment and interpretation of CBCT images are complex, time consuming, and operator sensitive. Therefore with machine learning, the automated identification of CBCT landmarks would be beneficial for clinicians [8]. Different machine learning techniques have been researched for this purpose. One particular method for evaluation of CBCT is a feature based and voxel based method for automated landmark identification in a CBCT [42]. However, the accuracy has not found to be high. This is because of the high susceptibility to errors with registration based approaches. Recently, deep learning based methods have been applied to evaluate CBCT scans [43,44]. This method has shown some promise but further research is required for the assessment of the automated landmark identification and segmentation in CBCT scans.

### Conclusions

This review article discussed the basics of CBCT and the uses of CBCT in different dental fields. CBCT allows the evaluation of various oral and maxillofacial problems. Until recently two dimensional imaging has been used in dentistry for diagnosis and dental treatment. Now with the advances in CBCT, it has become the new standard for dental imaging for many conditions. CBCT provides lower radiation than computed tomography and has a shorter scanning time than computed tomography. CBCT has helped the dental clinicians and patients alike by improving the diagnostic aspects of dentistry and improving the success rates of the treatment outcomes. CBCT enables the clinicians to accurately evaluate the implant site for patient selection. CBCT has been used extensively in the field of oral and maxillofacial surgery for diagnosis of preoperative, intraoperative and postoperative evolution. In orthodontics, CBCT plays a vital role in diagnosis, evaluation of facial growth as well as discrepancies in dental eruption. Furthermore, CBCT is useful in treatment planning especially for surgical cases, generation of computer designed splint. The evaluation of treatment outcomes such as root resorption is another important utility of CBCT scans. The ability of CBCT to enable the evaluation of condyle, glenoid fossa, and surrounding structures is important for patients with TMJ symptoms and to assess the asymmetry by comparing the right and left TMJ. CBCT is widely used in endodontics for evaluation of periapical lesions as it depicts accurately the involvement of membrane of maxillary sinus and proximity to mandibular canal and allows treatment planning by complete evaluation of root canals. CBCT provides a lot of information and therefore, the assessment and interpretation of CBCT images are complex, time consuming, and operator sensitive. Therefore, automated identification of CBCT landmarks with machine learning or artificial intelligence can make CBCT evaluation more efficient for the clinicians.

## References

- White SC, Pharoah M (2014) Oral radiology principles and interpretation. St. Louis: Mosby Elsevier 199-212.
- Ito K, Yoshinuma N, Goke E, Arai Y, Shinoda K (2001) Clinical application of a new compact computed tomography system for evaluating the outcome of regenerative therapy: A case report. *J Periodontol* 72: 696-702. [Link: https://bit.ly/3q0MrUE](https://bit.ly/3q0MrUE)
- Mehta S, Dresner R, Gandhi V, Chen PJ, Allareddy V, et al. (2020) Effect of positional errors on the accuracy of cervical vertebrae maturation assessment using CBCT and lateral cephalograms. *J World Fed Orthod* 9: 146-154. [Link: https://bit.ly/2ZNxVo2](https://bit.ly/2ZNxVo2)
- Goldman LW (2007) Principles of ct and ct technology. *J Nucl Med Technol* 35: 115-128. [Link: https://bit.ly/3GMD803](https://bit.ly/3GMD803)
- Arai Y, Tammisalo E, Iwai K, Hashimoto K, Shinoda K (1999) Development of a compact computed tomographic apparatus for dental use. *Dentomaxillofac Radiol* 28: 245-248. [Link: https://bit.ly/3k4fcfg](https://bit.ly/3k4fcfg)
- Mozzo P, Procacci C, Tacconi A, Martini PT, Andreis IA (1998) A new volumetric ct machine for dental imaging based on the cone-beam technique: Preliminary results. *Eur Radiol* 8: 1558-1564. [Link: https://bit.ly/3wbBZdU](https://bit.ly/3wbBZdU)
- Taneja S, Barbee DL, Rea AJ, Malin M (2020) CBCT image quality QA: Establishing a quantitative program. *J Appl Clin Med Phys* 21: 215-225. [Link: https://bit.ly/3q0Mpw0](https://bit.ly/3q0Mpw0)
- Danforth RA, Miles DA (2007) Cone beam volume imaging (cbvi): 3d applications for dentistry. *Irish Dent* 10: 14-18.
- Mehta S, Suhail Y, Nelson J, Upadhyay M (2021) Artificial Intelligence for radiographic image analysis. *Semin Orthod* 27: 109-120. [Link: https://bit.ly/3wjtY72](https://bit.ly/3wjtY72)
- Tischler M (2008) In-office cone beam computerized tomography: Technology review and clinical examples. *Dent Today* 27: 102-106. [Link: https://bit.ly/3bDRP7G](https://bit.ly/3bDRP7G)
- Nickenig HJ, Eitner S (2007) Reliability of implant placement after virtual planning of implant positions using cone beam ct data and surgical (guide) templates. *J Craniomaxillofac Surg* 35: 207-211. [Link: https://bit.ly/3blkOXX](https://bit.ly/3blkOXX)
- Tyndall DA, Price JB, Tetradis S, Ganz SD, Hildebolt C, et al. (2012) Position statement of the american academy of oral and maxillofacial radiology on selection criteria for the use of radiology in dental implantology with emphasis on cone beam computed tomography. *Oral Surg Oral Med Oral Pathol Oral Radiol* 113: 817-826. [Link: https://bit.ly/3mMRoyB](https://bit.ly/3mMRoyB)
- Almog DM, LaMar J, LaMar FR, LaMar F (2006) Cone beam computerized tomography-based dental imaging for implant planning and surgical guidance, part 1: Single implant in the mandibular molar region. *J Oral Implantol* 32: 77-81. [Link: https://bit.ly/3k3Pm1p](https://bit.ly/3k3Pm1p)
- Cevdanes LH, Bailey LJ, Tucker GR, Styner MA, Mol A, et al. (2005) Superimposition of 3d cone-beam ct models of orthognathic surgery patients. *Dentomaxillofac Radiol* 34: 369-375. [Link: https://bit.ly/3q3vLvW](https://bit.ly/3q3vLvW)
- Heiland M, Schulze D, Rother U, Schmelzle R (2004) Postoperative imaging of zygomaticomaxillary complex fractures using digital volume tomography. *J Oral Maxillofac Surg* 62: 1387-1391. [Link: https://bit.ly/2ZYk5zE](https://bit.ly/2ZYk5zE)
- Pohlentz P, Blessmann M, Blake F, Heinrich S, Schmelzle R, et al. (2007) Clinical indications and perspectives for intraoperative cone-beam computed tomography in oral and maxillofacial surgery. *Oral Surg Oral Med Oral Pathol Oral Radiol Endod* 103: 412-417. [Link: https://bit.ly/3EFelJe](https://bit.ly/3EFelJe)
- Pohlentz P, Blessmann M, Blake F, Gbara A, Schmelzle R, et al. (2008) Major mandibular surgical procedures as an indication for intraoperative imaging. *J Oral Maxillofac Surg* 66: 324-329. [Link: https://bit.ly/3nMkEEM](https://bit.ly/3nMkEEM)
- Yajima A, Otonari-Yamamoto M, Sano T, Hayakawa Y, Otonari T, et al. (2006) Cone-beam ct (cb throne) applied to dentomaxillofacial region. *Bull Tokyo Dent Coll* 47: 133-141. [Link: https://bit.ly/3EFekW6](https://bit.ly/3EFekW6)
- Tetradis S, Anstey P, Graff-Radford S (2010) Cone beam computed tomography in the diagnosis of dental disease. *J Calif Dent Assoc* 38: 27- 32. [Link: https://bit.ly/3wddZHx](https://bit.ly/3wddZHx)
- Liu DG, Zhang WL, Zhang ZY, Wu YT, Ma XC (2008) Localization of impacted maxillary canines and observation of adjacent incisor resorption with cone-beam computed tomography. *Oral Surg Oral Med Oral Pathol Oral Radiol Endod* 105: 91-98. [Link: https://bit.ly/3bBX7ko](https://bit.ly/3bBX7ko)
- Pawelzik J, Cohnen M, Willers R, Becker J (2002) A comparison of conventional panoramic radiographs with volumetric computed tomography images in the preoperative assessment of impacted mandibular third molars. *J Oral Maxillofac Surg* 60: 979-984. [Link: https://bit.ly/3w8WtnP](https://bit.ly/3w8WtnP)
- Harrell WE (2007) Three-dimensional diagnosis and treatment planning: The use of 3d facial imaging and 3d cone beam CT in orthodontics and dentistry. *Australasian Dent Pract* 18: 102-113. [Link: https://bit.ly/3wbYGyO](https://bit.ly/3wbYGyO)
- Mehta S, Patel D, Yadav S (2021) Staging orthodontic aligners for complex orthodontic tooth movement. *Turk J Orthod* 34: 202-206. [Link: https://bit.ly/3mHrIU0](https://bit.ly/3mHrIU0)
- Haouili N, Kravitz ND, Vaid NR, Ferguson DJ, Makki L (2020) Has Invisalign improved? A prospective follow-up study on the efficacy of tooth movement with Invisalign. *Am J Orthod Dentofacial Orthop* 158: 420-425. [Link: https://bit.ly/3CGtVUZ](https://bit.ly/3CGtVUZ)
- Jiang T, Jiang YN, Chu FT, Lu PJ, Tang GH (2021) A cone-beam computed tomographic study evaluating the efficacy of incisor movement with clear aligners: Assessment of incisor pure tipping, controlled tipping, translation, and torque. *Am J Orthod Dentofacial Orthop* 159: 635-643. [Link: https://bit.ly/3mH8ZYG](https://bit.ly/3mH8ZYG)
- Mehta S, Wang D, Kuo CL, Mu J, Vich ML, et al. (2021) Long-term effects of mini-screw-assisted rapid palatal expansion on airway. *Angle Orthod* 91: 195-205. [Link: https://bit.ly/2ZKoEgE](https://bit.ly/2ZKoEgE)
- Abu Arqub S, Mehta S, Iverson MG, Yadav S, Upadhyay M, et al. (2021) Does Mini Screw Assisted Rapid Palatal Expansion (MARPE) have an influence on airway and breathing in middle-aged children and adolescents? A systematic review. *Int Orthod* 19: 37-50. [Link: https://bit.ly/2ZNMu6c](https://bit.ly/2ZNMu6c)
- Dzingle J, Mehta S, Chen PJ, Yadav S (2020) Correction of Unilateral Posterior Crossbite with U-MARPE. *Turk J Orthod* 33: 192-196. [Link: https://bit.ly/3byrsjl](https://bit.ly/3byrsjl)
- Kapila S, Conley RS, Harrell WE (2011) The current status of cone beam computed tomography imaging in orthodontics. *Dentomaxillofac Radiol* 40: 24-34. [Link: https://bit.ly/3GLtzPk](https://bit.ly/3GLtzPk)
- Mehta S, Chen PJ, Upadhyay M, Yadav S (2021) Intermaxillary elastics on skeletal anchorage and MARPE to treat a class III maxillary retrognathic open bite adolescent: A case report. *Int Orthod* S1761-7227: 107-108. [Link: https://bit.ly/3EJmpJU](https://bit.ly/3EJmpJU)
- Alkhayer A, Piffkó J, Lippold C, Segatto E (2020) Accuracy of virtual planning in orthognathic surgery: a systematic review. *Head Face Med* 16: 34. [Link: https://bit.ly/3wiG5B9](https://bit.ly/3wiG5B9)
- Zinser M, Zoeller J (2015) Computer-Designed Splints for Surgical Transfer of 3D Orthognathic Planning. *Facial Plast Surg* 31: 474-490. [Link: https://bit.ly/3wfk04T](https://bit.ly/3wfk04T)
- Mehta S, Chen PJ, Kalajzic Z, Ahmida A, Yadav S (2021) Acceleration of orthodontic tooth movement and root resorption with near and distant surgical insults: An in-vivo study on a rat model. *Int Orthod* S1761-7227: 125-X. [Link: https://bit.ly/3EHSnpA](https://bit.ly/3EHSnpA)
- Aras I, Unal I, Huniler G, Aras A (2018) Root resorption due to orthodontic treatment using self-ligating and conventional brackets : A cone-beam



- computed tomography study. J Orofac Orthop 79: 181-190. [Link: https://bit.ly/31gRDJE](https://bit.ly/31gRDJE)
35. Puttaravutti P, Wongsuwanlert M, Charoemratrote C, Leethanakul C (2018) Volumetric evaluation of root resorption on the upper incisors using cone beam computed tomography after 1 year of orthodontic treatment in adult patients with marginal bone loss. Angle Orthod 88: 710-718. [Link: https://bit.ly/3EAu0Ku](https://bit.ly/3EAu0Ku)
36. Tsiklakis K, Syriopoulos K, Stamatakis HC (2004) Radiographic examination of the temporomandibular joint using cone beam computed tomography. Dentomaxillofac Radiol 33: 196-201. [Link: https://bit.ly/3wda8j](https://bit.ly/3wda8j)
37. Jung J, Kim JH, Lee JW, Ohe JY, Choi BJ (2018) Three-dimensional volumetric analysis of condylar head and glenoid cavity after mandibular advancement. J Craniomaxillofac Surg 46: 1470-1475. [Link: https://bit.ly/3CGAnLX](https://bit.ly/3CGAnLX)
38. Mehta S, Chen PJ, Vich ML, Upadhyay M, Tadinada A, et al. (2021) Bone-anchored versus tooth-anchored expansion appliances: Long-term effects on the condyle-fossa relationship. J World Fed Orthod S2212-4438: 31-X. [Link: https://bit.ly/3bR0fqZ](https://bit.ly/3bR0fqZ)
39. Honda K, Larheim TA, Johannessen S, Arai Y, Shinoda K, et al. (2001) Ortho cubic superhigh resolution computed tomography: A new radiographic technique with application to the temporomandibular joint. Oral Surg Oral Med Oral Pathol Oral Radiol Endod 91: 239-243. [Link: https://bit.ly/3GMCrEr](https://bit.ly/3GMCrEr)
40. Nakata K, Naitoh M, Izumi M, Inamoto K, Arijji E, Nakamura H (2006) Effectiveness of dental computed tomography in diagnostic imaging of periradicular lesion of each root of a multiradical tooth: A case report. J Endod 32: 583-587. [Link: https://bit.ly/3GPbslj](https://bit.ly/3GPbslj)
41. Nagaraja S, Sreenivasa Murthy BV (2010) Ct evaluation of canal preparation using rotary and hand ni-ti instruments: An in vitro study. J Conserv Dent 13: 16-22. [Link: https://bit.ly/3bBTVVL](https://bit.ly/3bBTVVL)
42. Shahidi S, Bahrapour E, Soltanimehr E, Zamani A, Oshagh M, et al. (2014) The accuracy of a designed software for automated localization of craniofacial landmarks on CBCT images. BMC Med Imaging 14: 32. [Link: https://bit.ly/3GXcOB9](https://bit.ly/3GXcOB9)
43. Gupta A, Kharbanda OP, Sardana V, Balachandran R, Sardana HK, et al. (2015) A knowledgebased algorithm for automatic detection of cephalometric landmarks on CBCT images. Int J Comput Assist Radiol Surg 10: 1737-1752. [Link: https://bit.ly/3nRKQxK](https://bit.ly/3nRKQxK)
44. Chen L, Liang X, Shen C, Jiang S, Wang J (2020) Synthetic CT generation from CBCT images via deep learning. Med Phys 47: 1115-1125. [Link: https://bit.ly/3EHa0Gg](https://bit.ly/3EHa0Gg)

### Discover a bigger Impact and Visibility of your article publication with Peertechz Publications

#### Highlights

- ❖ Signatory publisher of ORCID
- ❖ Signatory Publisher of DORA (San Francisco Declaration on Research Assessment)
- ❖ Articles archived in worlds' renowned service providers such as Portico, CNKI, AGRIS, TDNet, Base (Bielefeld University Library), CrossRef, Scilit, J-Gate etc.
- ❖ Journals indexed in ICMJE, SHERPA/ROMEO, Google Scholar etc.
- ❖ OAI-PMH (Open Archives Initiative Protocol for Metadata Harvesting)
- ❖ Dedicated Editorial Board for every journal
- ❖ Accurate and rapid peer-review process
- ❖ Increased citations of published articles through promotions
- ❖ Reduced timeline for article publication

Submit your articles and experience a new surge in publication services (<https://www.peertechz.com/submission>).

*Peertechz journals wishes everlasting success in your every endeavours.*