



Vlad Budu^{1,2*}, Tatiana Decuseară¹, Andreea-Nicoleta Costache¹, Lavinia Sava¹, B Dima¹ and M Tuşaliu^{1,2}

¹ENT Institute "Prof. Dr. D. Hociotă", Bucharest, Romania

²University of Medicine and Pharmacy "Carol Davila", Bucharest, Romania

Dates: Received: 06 March, 2017; **Accepted:** 07 April, 2017; **Published:** 08 April, 2017

***Corresponding author:** Vlad Budu, Associated Professor, ENT Institute, University of Medicine and Pharmacy "Carol Davila", Bucharest, Romania, Tel: +40788413218; E-mail: vladbudu@yahoo.com

Keywords: Tornwaldt cyst; Endoscopic sinus surgery; Nasopharyngeal tumor

<https://www.peertechz.com>

Short Communication

Tornwaldt's Cyst – Comments on Clinical Cases

Abstract

Tornwaldt's cyst represents a benign tumor which develops in the midline of the nasopharyngeal mucosa. Due to the fact that it doesn't usually cause any symptoms, it is often discovered incidentally during a nasal endoscopy or another imaging investigation (either CT or MRI). Treatment is only advised when the cyst becomes symptomatic. In this paper, the authors aim to illustrate the optimal approach when dealing with a Tornwaldt's cyst and to underline the importance of a correctly executed endoscopic surgery.

Introduction

Tornwaldt's cyst is a benign nasopharyngeal structure that results from a developmental remnant and which may cause clinically significant symptoms. It is named after Gustav Ludwig Tornwaldt who established it as a pathological entity in 1885, despite being previously discovered by Mayer in 1840 during an autopsy.

The overall incidence of Tornwaldt's cyst varies from one author to another. Therefore, whilst some authors report an incidence of 1.4% to 3.3% in autopsy specimens, others describe the cyst based on MRI findings ranging from 0.2% to 5% of the cases [1].

Generally speaking, a Tornwaldt's cyst is an uncommon discovery, with no gender predilection, which may occur at any age, especially in the 2nd and 4th decades of life [2].

From an embryologic point of view, Tornwaldt's cysts form as a result of the notochord retracting from its contact point with the endoderm of the primitive pharynx, as the former ascends through the clivus in order to create the neural plate. Therefore a persistent communication appears between the roof of the nasopharynx and the notochord.

Discussions

There are two types of Tornwaldt's cysts depending whether the orifice of the remnant is obstructed or not. Thus, the first type is described as cystic when the orifice is obliterated. Secondly, Tornwaldt's cysts may appear as crusting when

there are adhesions that do not close the orifice entirely [3]. The cyst is lined by respiratory epithelium that may present areas of squamous metaplasia especially once it's obstructed and it develops an inflammatory process.

Tornwaldt's cyst is usually located in the midline of the posterior nasopharyngeal wall, but it may also be found slightly off midline, especially extending upwards and backwards toward the occipital bone. Therefore, Tornwaldt's cyst lies posteriorly of the path taken by Rathke's pouch as it descends from the sella turcica. By understanding this localization, we can easily enlist several differential diagnoses to rule out.

Most Tornwaldt's cysts are small and asymptomatic, but they may develop symptoms as their volume increases due to mucous secretion. This happens either spontaneously or secondary to inflammation when edema of the orifice leads to further aggravation of the pathophysiological cycle (Figure 1).

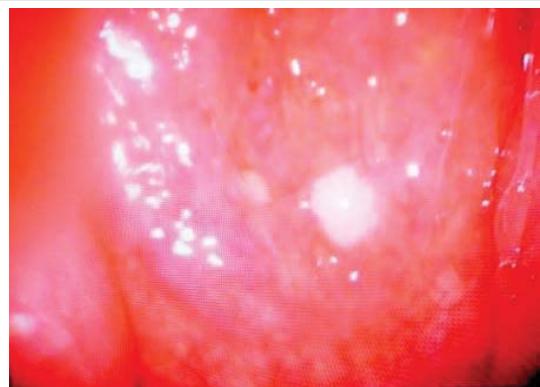

Figure 1: Small asymptomatic cyst.

The most important symptoms described by patients with Tornwaldt's cysts are: postnasal drainage, nasal obstruction, cervical stiffness associated with headache, aural fullness and serous otitis media. The latter is caused by the obstruction of Eustachian tube. Moreover, if the content of the cyst becomes infected, it leads to periodic discharge of foul tasting fluid into the patient's mouth associated with halitosis [4].

Tornwaldt's cyst can be diagnosed by nasal endoscopy or imaging examinations. Nasal endoscopy shows a smooth midline mass, of various sizes, on the posterior wall of the nasopharynx. Depending of the size of the cyst, it can cause various levels of nasal obstruction and dysfunction of the Eustachian tube (Figure 2).

On computed tomography it appears as a well-defined low density mass in the roof of the nasopharynx. MRI is the investigation of choice. It can have a high signal intensity on both T1 and T2 weighted images, depending on the protein content, the presence of hemorrhage within the cyst or both [5] (Figure 3).

Differential diagnosis includes adenoid retention cyst, Rathke's pouch, malignant tumors, branchial cleft cyst, meningocele, meningoencephalocele craniopharyngioma.

Results

Asymptomatic small cysts require no treatment. If the lesion is large, symptomatic or close to the Eustachian tube torus, surgical marsupialization under general anesthesia is the treatment of choice. Drainage alone can lead to recurrence. Endonasal approach with 0 degree rigid endoscope is recommended for small cysts, while for large lesions the transoral retrovelar approach using a 70 degree endoscope is preferred [6]. Surgery can be performed using cold instruments, powered instruments (microdebrider) or by laser technique (longer operation time and higher costs). The cyst must be drained and the aspirate sent for culture and antibiotic sensitivity (Figure 4). After complete drainage we resect the anterior wall of the cyst, without any damage on the prevertebralis muscles or fascia (Figure 5).

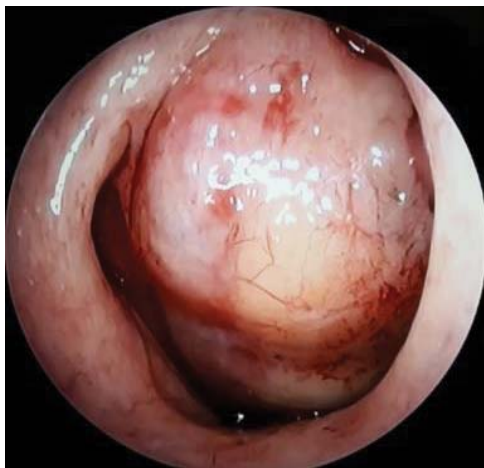

Figure 2: Cyst causing nasal obstruction.

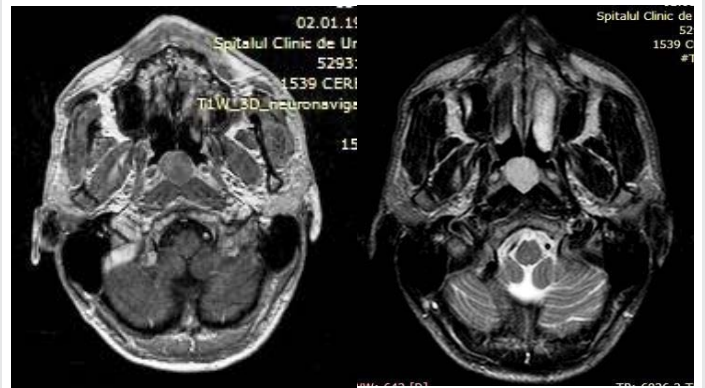


Figure 3: MRI in T1 and T2.

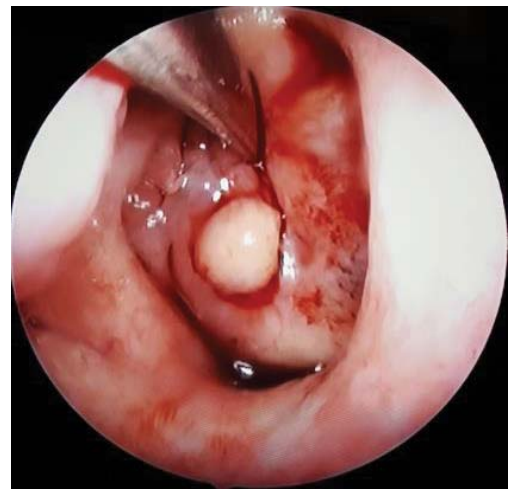

Figure 4: Drainage of the cyst.

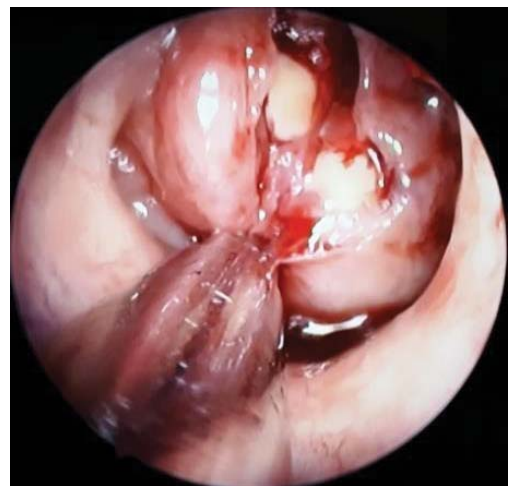

Figure 5: Resection of the cyst wall.

At the end of the procedure the surgical field is represented posteriorly by the prevertebral muscles, without any rhinopharyngeal obstruction and a normal nasal airflow. Marsupialization using a microdebrider is a fast method and provides less bleeding and less trauma on the surrounding tissues [7]. The cyst wall must be removed and sent for histopathological examination in order to confirm the diagnosis.

Complications that can occur are represented by damaging fascia prevertebralis or the Eustachian tube rhinopharyngian opening. The injury of sphenopalatine artery or vidian artery is responsible of intraoperative bleeding. Late complications are represented by rhinopharyngeal scars and adhesions or recurrence of the cyst due to incomplete removal. Usually we do not pack the nasal cavity and the rhinopharynx.

Conclusion

Tornwaldt's cyst is a benign tumour, usually located in the midline of the posterior nasopharyngeal wall. MRI is considered the best imaging examination to diagnose this inflammatory benign cyst. It is commonly asymptomatic and requires no treatment. If the cyst is large or symptomatic the treatment of choice is marsupialization, which assures no recurrences. Complete drainage and microbiological sampling is required in order to initiate the adequate therapy. A normal airflow is achieved after surgery which ensures a good quality of life for the patient.

References

1. Jyotirmay H, Kumar SA, Preetam P, Manjunath D, Bijiraj VV (2014) Recent Trends in the Management of Thornwaldts cyst: A Case Report. *J Clin Diagn Res* 8: KD03-KD04. [Link: https://goo.gl/uNU6JP](https://goo.gl/uNU6JP)
2. Wenig BM (2015) *Atlas of Head and Neck Pathology*, 3rd ed. 411. [Link: https://goo.gl/k2rnyS](https://goo.gl/k2rnyS)
3. Miyahara H, Matsunaga T (1995) Tornwaldt's disease. *Acta Otolaryngol Suppl* 517: 36-39. [Link: https://goo.gl/1T5X7f](https://goo.gl/1T5X7f)
4. Baisakhiya N, Deshmukh P, Pawar V (2011) Tornwaldt Cyst: A Cause of Neck Pain and Stiffness. *Indian J Otolaryngol Head Neck Surg* 63: 147-148. [Link: https://goo.gl/JCJTHU](https://goo.gl/JCJTHU)
5. Vijayashree MS, Viswanatha B (2014) "Tornwaldt's Cyst, Tornwaldt's Bursitis and Tornwaldt's Disease: A Review". *Research in Otolaryngology* 3: 60-63. [Link: https://goo.gl/BMqlrT](https://goo.gl/BMqlrT)
6. Eloy P, Watelet JB, Hatert AS, Bertrand B (2006) "Tornwaldt's cyst and surgery with powered instrumentation". *B-ENT* 2: 135-139. [Link: https://goo.gl/Lfyec4](https://goo.gl/Lfyec4)
7. Ketenci I, Cihan MC, Doğan M, Akay E, Ünlü Y (2014) "A Giant Thornwaldt Cyst: Case Report". *Erciyes Med J* 36: 170-173. [Link: https://goo.gl/kXzuGh](https://goo.gl/kXzuGh)