

Islam Abdou Elzahaby^{1*} and Elsherbini Elazazy Elshal²

¹Lecturer of surgical oncology at oncology center
Mansoura University, Egypt

²Consultant of oral and maxillofacial surgery at
Mansoura international hospital, Egypt

Dates: Received: 21 December, 2016; Accepted: 27
January, 2017; Published: 28 January, 2017

*Corresponding author: Islam Abdou Elza-
haby, Dr. Lecturer of Surgical Oncology at
Oncology Center Mansoura University, E-mail:
islamabdou2010@yahoo.com

Keywords: Styloid; Eagle syndrome; Stylalgia; Styloid-
ectomy

<https://www.peertechz.com>

Case Report

Stylohyoid Syndrome and its Surgical Treatment – A Case Report and Review of the Literature

Abstract

Stylohyoid syndrome or eagle's syndrome is caused by calcification of the stylohyoid ligament or elongation of the bony styloid process. It may remain asymptomatic or it may present with facial neuralgia, foreign body sensation in pharynx, throat pain or even otalgia and cephalgia. Diagnosis is mainly based on clinical examination and confirmed by the radiological findings. The mainstay treatment is surgical excision via external approach or intraoral approach. We are reporting a case of unilateral stylohyoid syndrome along with the literature review.

Introduction

Stylohyoid syndrome or Eagle syndrome or stylalgia is an uncommon syndrome that affects about 4% of population and is more common in middle aged females between 30-50 years [1,2].

The aetiology of this syndrome was reported to be due to anatomical or pathological elongation of the styloid process or calcified stylohyoid ligament. Eagle defined the length of a normal styloid process at 2.5-3.0 cm [1,3,4].

In most instances this syndrome is diagnosed incidentally or by exclusion due to its rarity and heterogeneous symptomatology, nevertheless its primary symptom is oropharyngeal pain or stylalgia which may radiate to the ear and may be exaggerated by head movement or even chewing, yawning and speaking [5,6].

The diagnosis of this syndrome therefore represents a challenge [7]. Patients with eagle syndrome may pass undiagnosed or even receive psychotherapy being diagnosed as having a psychological disturbance rather than an organic disease.

Stylohyoid syndrome can be successfully treated by surgical styloidectomy either intra or extra-orally (transcervical), however, some authors reported successful conservative medical treatment [8-10].

We hereby reporting a patient of stylohyoid syndrome who sought medical advice at different clinics without relief and

lastly he came at our oncology clinic for exclusion of malignancy due to his cancer phobia as his father has had nasopharyngeal carcinoma where we suspected stylohyoid syndrome and was proved by the 3D reformatted CT.

Case presentation

A 45-year-old male patient presented to the oncology center at Mansoura University, complaining of a dull-aching intermittent pain in left upper neck region of ten months duration, the pain was radiating to oropharynx, the patient also gave a history of long standing intermittent odynophagia and a foreign body sensation in the throat. The pain is exacerbating with turning the head to the right side. There was no recent history of tonsillectomy or any other cervicopharyngeal trauma. The patient sought medical advice at a dental, otolaryngology and neurology clinics with no improvement. Cancer phobia was the drive that made the patient seek service at our oncology center since his father has had nasopharyngeal carcinoma.

Physical examination revealed no palpable masses in the neck or in the tonsillar regions however moderate tenderness was expressed by the patient while palpating the left tonsillar region.

Radiographic evaluation revealed (3D reformatted computed tomography) elongated styloid process (calcified stylohyoid complex), measuring 6.7 cm on left side and 2.3 cm on right side (Figure 1). So we suspected a stylohyoid (Eagle) syndrome. Confirmation of the diagnosis was made by local infiltration of 2% lidocaine in the left paratonsillar region which led to immediate pain relief.

Surgical excision of the elongated left styloid process was decided via an extra-oral trans-cervical submandibular approach. In this approach we made a curvilinear incision in the left upper neck from the anterior border of the left sternocleidomastoid and forwards towards the hyoid bone then upwards towards the midline. (Figures 2,3) After cephalad and medial retraction of the submandibular gland, excision of the elongated styloid process together with the calcified stylohyoid ligament till the lesser cornu of the hyoid bone was done. The postoperative course was smooth and the patient was discharged in the second postoperative day after removing the suction drain with no complications. Symptoms dramatically improved during the weekly postoperative follow up, till he became completely asymptomatic within about one month postoperative. The patient was kept under regular follow up for a period of one year post styloidectomy and the patient was free of any symptom.

Discussion

Stylohyoid syndrome or stylalgia was primarily called eagle syndrome, due to its first documentation by the otolaryngologist Watt W eagle in 1937. It may be unilateral or bilateral [3], the prevalence of this syndrome was primarily thought to be 4% of population then claimed to be as low as 1.4% [11], and then reported to be as high as 30% by Keur et al., in 1986 [12].

The stylohyoid syndrome results from anatomical or pathological abnormality in the stylohyoid complex or apparatus which arises embryonically from the Reichert cartilage of the second branchial arch and is formed of styloid process, stylohyoid ligament and lesser cornu of the hyoid bone [3,6,13].

The stylohyoid apparatus lies in a critical position within the parapharyngeal space crossing the upper lateral neck from the lateral skull base to the anterolateral neck, positioned in close proximity to the important neurovascular structures as 5th, 7th, 9th, 10th cranial nerves; internal jugular vein and internal carotid artery (with its surrounding sympathetic nerves) which lie in the maxilla-vertebro-pharyngeal recess [3,4,14]. Therefore, anatomical or pathological abnormalities in the length and/or

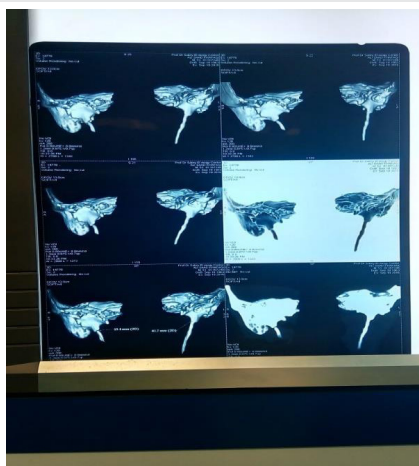


Figure 1: Reformatted 3D CT image of left stylohyoid syndrome patient.

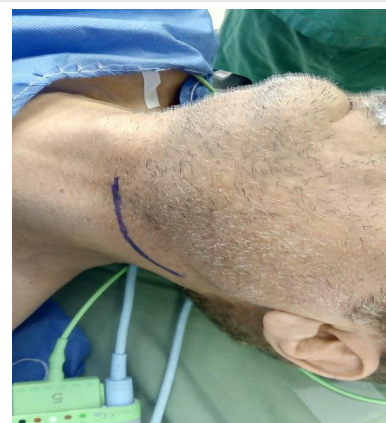

Figure 2: Preoperative marking for external styloidectomy.

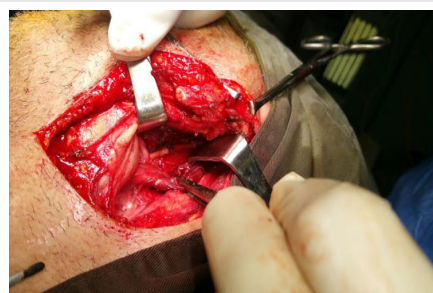

Figure 3: Intraoperative view before styloidectomy.

direction of the styloid process or calcification of its attached ligaments could lead to variable degrees of compression on these related important neurovascular structures expressing variable degrees of clinical symptoms ranging from no symptoms [15], or phantom foreign body sensation in throat to compressive cranial neuropathy most commonly presenting with odynophagia and radiating otalgia (classical type of eagle syndrome) or even compression over the internal carotid artery leading to pain in the parietal region of the skull or in the superior periorbital region or even cerebral ischemia (stylo-carotid type of eagle syndrome [6,16,17] (Figures 4,5).

The clinical symptoms are vague and variable and had other several differential diagnoses [10]. Two clinical signs are considered pathognomonic or characteristic to this syndrome which are tenderness elicited while palpating the components of the stylohyoid complex especially at the tonsillar region and the rare presence of a tender bony projection on the ipsilateral submandibular region anterior to the sternocleidomastoid muscle [18].

History of tonsillectomy or cervicofacial trauma may be typically found in many patients with classic type eagle syndrome due to resultant traumatic scarring and hyperplasia in stylohyoid complex [3,16]. Nevertheless, inherited familial ossification or embryonic ossification or osteoarthritis changes within the stylohyoid complex are all reported as possible etiologies of this syndrome [1,19]. The presence of associated psychological problems is described by some authors [20].

Radiological imaging with computed tomography especially with 3 D reformatted images is considered the optimal

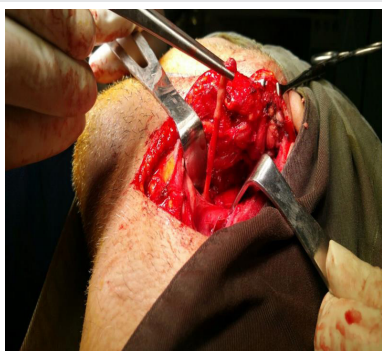


Figure 4: Intraoperative view after cutting the styloid process.

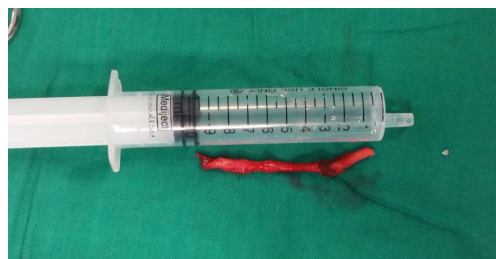

Figure 5: Gross appearance of the resected styloid and stylohyoid ligament.

method for confirmation of eagle's syndrome diagnosis [1,21,22], however, Eagle syndrome cases that result from stylopharyngeus muscle calcification may be missed by this type of imaging [5]. In our case, we believe that the length given by the radiologist is the combined length of the left styloid process and the calcified part of the stylohyoid ligament which was 6.7 on the left side.

The diagnosis of this syndrome represents a challenge not only because of its rarity but also due to its vague and heterogeneous symptomatology and several available different differential diagnoses, which include trigeminal neuralgia, glossopharyngeal neuralgia, temporomandibular joint dysfunction, carotidynia, atypical migraine temporal arteritis, salivary gland problems, chronic tonsillitis, pharyngeal tumors, laryngopharyngeal reflux, dental problems, , otitis externa or media, and mastoiditis [5], so diagnosis requires good awareness of this condition together with high index of suspicion, furthermore it might be suspected in those patient having psychiatric problems [6,7,23].

Treatment of this quite rare clinical entity is mainly surgical by excision of the elongated styloid process with or without the calcified stylohyoid ligament and/or elongated hyoid bone via an extra-oral or intra-oral approach [8,24]. Some authors advocated the intra-oral approach for cases with styloid bony process elongation; and the extra-oral approach for ossified stylohyoid ligament or elongated hyoid bone cornu [5]. Naik reported successful treatment of 15 cases of eagle's syndrome with tonsillo-styloidectomy. [10]. Interestingly, Maru K and Patidar K. reported successful transoral styloidectomy under local anaesthesia in 332 patients with stylohyoid syndrome [25]. Others reported successful treatment of this syndrome with conservative non- surgical modalities including analgesics,

pain killers, antidepressants, local injection of local anesthetics and steroids in peritonsillar region and stellate ganglion block [9,26], however, we and other authors do believe that conservative medical treatment provides only a temporary relief and cannot replace surgical treatment [26,27].

Conclusion

Stylohyoid syndrome is not extremely rare and is more common than generally thought. Its symptoms could be severe and life limiting. Stylohyoid syndrome patients usually seek medical advice at several clinics even the oncology clinic as occurred with our patient. This syndrome should be excluded in any patient with chronic throat pain referred to the ear or cheek or lateral neck especially if the pain is initiated or exaggerated by swallowing or neck movement and cannot be explained by other etiologies. Stylohyoid syndrome patients frequently pass undiagnosed and are claimed to be psychoneurotic despite having an organic lesion.

We do believe that the best way for catching up the diagnosis is the high index of suspicion together with thorough knowledge and awareness of the vague and heterogeneous symptomatology of this syndrome.

Financial disclosure

“None of the authors has a financial interest in any of the products, devices, or drugs mentioned in this manuscript.”

Informed consent and ethical approval: Written informed consent was obtained from the patient for publication of this case report and any accompanying images.

References

1. Fusco DJ, Asteraki S, Spetzler RF (2012) Eagle's syndrome: embryology, anatomy, and clinical management. *Acta Neurochir (Wien)* 154: 1119-1126. [Link: https://goo.gl/KM4WC1](https://goo.gl/KM4WC1)
2. Piagkou M, Anagnostopoulou S, Kouladouros K, Piagkos G (2009) Eagle's syndrome: a review of the literature. *Clin Anat* 22: 545-558. [Link: https://goo.gl/b04pnt](https://goo.gl/b04pnt)
3. Eagle WW (1937) Elongated styloid processes: report of two cases. *Archives of Otolaryngology* 25: 584-587. [Link: https://goo.gl/hJvzG9](https://goo.gl/hJvzG9)
4. Eagle WW (1948) Elongated styloid process: further observations and a new syndrome. *Arch Otolaryngol* 47: 630-640. [Link: https://goo.gl/XChs16](https://goo.gl/XChs16)
5. Colby CC, Del Gaudio JM (2011) Stylohyoid complex syndrome: a new diagnostic classification. *Arch Otolaryngol Head Neck Surg* 137: 248-252. [Link: https://goo.gl/dJaFNX](https://goo.gl/dJaFNX)
6. Mendelsohn AH, Berke GS, Chhetri DK (2006) Heterogeneity in the clinical presentation of Eagle's syndrome. *Otolaryngol Head Neck Surg* 134: 389-393. [Link: https://goo.gl/5qvuQ2](https://goo.gl/5qvuQ2)
7. Kaushik A, Tanwar R, Garg P, Kaushik M, Panwar R, et al. (2012) Calcified stylohyoid ligaments: A diagnostic dilemma. *SRM Journal of Research in Dental Sciences* 3:275-278. [Link: https://goo.gl/EwNOsB](https://goo.gl/EwNOsB)
8. Chase DC, Zarmen A, Bigelow WC, McCoy JM (1986) Eagle's syndrome: a comparison of intraoral versus extraoral surgical approaches. *Oral Surg Oral Med Oral Pathol* 62: 625-629. [Link: https://goo.gl/vMxfUT](https://goo.gl/vMxfUT)



9. Glogoff MR, Baum S, Cheifetz I (1981) Diagnosis and treatment of Eagle's syndrome. *Journal of oral surgery (American Dental Association)* 39: 941-944. [Link: https://goo.gl/HNuy3h](https://goo.gl/HNuy3h)
10. Naik SM, Naik SS (2011) Tonsillo-styloidectomy for Eagle's syndrome: a review of 15 cases in KVG Medical College Sullia. *Oman Med J* 26: 122-126. [Link: https://goo.gl/XuZ8iU](https://goo.gl/XuZ8iU)
11. Gossman JR, Tarsitano JJ (1977) The styloid-stylohyoid syndrome. *J Oral Surg*, 35: 555-560. [Link: https://goo.gl/JYKltL](https://goo.gl/JYKltL)
12. Keur JJ, Campbell JP, McCarthy JF, Ralph WJ (1986) The clinical significance of the elongated styloid process. *Oral Surg Oral Med Oral Pathol*, 61: 399-404. [Link: https://goo.gl/eU7AkJ](https://goo.gl/eU7AkJ)
13. Mortellaro C, Biancucci P, Picciolo G, Vercellino V (2002) Eagle's syndrome: importance of a corrected diagnosis and adequate surgical treatment. *J Craniofac Surg* 13: 755-758. [Link: https://goo.gl/B4jRHX](https://goo.gl/B4jRHX)
14. Feldman VB (2003) Eagle's syndrome: a case of symptomatic calcification of the stylohyoid ligaments. *J Can Chiropr Assoc* 47: 21-27. [Link: https://goo.gl/BBxReZ](https://goo.gl/BBxReZ)
15. Desai V, Maghu S, Sharma R, Koduri S (2014) Unique asymptomatic long bilateral calcified styloid process: A case report. *Journal of Indian Academy of Oral Medicine and Radiology* 26: 302-305. [Link: https://goo.gl/IPqkml](https://goo.gl/IPqkml)
16. Eagle WW (1949) Symptomatic elongated styloid process; report of two cases of styloid process-carotid artery syndrome with operation. *Arch Otolaryngol* 49: 490-503. [Link: https://goo.gl/k7VUGV](https://goo.gl/k7VUGV)
17. Infante-Cossío P, García-Perla A, González-García A, Gil-Peralta A, Gutiérrez-Pérez JL (2003) [Compression of the internal carotid artery due to elongated styloid process]. *Revista de neurologia* 39: 339-343. [Link: https://goo.gl/c3S4LR](https://goo.gl/c3S4LR)
18. Khandelwal S, Hada YS, Harsh A (2011) Eagle's syndrome—A case report and review of the literature. *Saudi Dent J* 23: 211-215. [Link: https://goo.gl/skTldq](https://goo.gl/skTldq)
19. Morrison PJ, Morrison RJ, McKinstry CS (2012) Familial ossification of the stylohyoid ligament in a three generation family—a new clinical entity displaying autosomal dominant inheritance. *Br J Radiol* 85: 458-459. [Link: https://goo.gl/9mgaAh](https://goo.gl/9mgaAh)
20. Hampf G, Aalberg V, Tasanen A, Nyman C (1986) A holistic approach to stylalgia. *Int J Oral Maxillofac Surg* 15: 549-552. [Link: https://goo.gl/qStjE6](https://goo.gl/qStjE6)
21. Beder E, Ozgursoy OB, Karatayli Ozgursoy S, Anadolu Y (2006) Three-dimensional computed tomography and surgical treatment for Eagle's syndrome. *Ear Nose Throat J* 85: 443-446. [Link: https://goo.gl/sMC1Aw](https://goo.gl/sMC1Aw)
22. Murtagh RD, Caracciolo JT, Fernandez G (2001) CT findings associated with Eagle syndrome. *AJNR Am J Neuroradiol* 22: 1401-1402. [Link: https://goo.gl/lxUWdo](https://goo.gl/lxUWdo)
23. Woolery WA (1990) The diagnostic challenge of styloid elongation (Eagle's syndrome). *J Am Osteopath Assoc* 90: 88-89. [Link: https://goo.gl/w2bM7g](https://goo.gl/w2bM7g)
24. Ilgüy M, Ilgüy D, Güler N, Bayirli G (2005) Incidence of the type and calcification patterns in patients with elongated styloid process. *J Int Med Res* 33: 96-102. [Link: https://goo.gl/8iP714](https://goo.gl/8iP714)
25. Maru YK, Patidar K (2003) Stylalgia and its surgical management by intra oral route -clinical experience of 332 cases. *Indian J Otolaryngol Head Neck Surg* 55: 87-90. [Link: https://goo.gl/vFFmfJ](https://goo.gl/vFFmfJ)
26. Han MK, Kim DW, Yang JY (2013) Non Surgical Treatment of Eagle's Syndrome-A Case Report. *Korean J Pain* 26: 169-172. [Link: https://goo.gl/gPTdPh](https://goo.gl/gPTdPh)
27. Prasad KC, Kamath MP, Reddy KJ, Raju K, Agarwal S (2002) Elongated styloid process (Eagle's syndrome): a clinical study. *J Oral Maxillofac Surg* 60: 171-175. [Link: https://goo.gl/Fmnq04](https://goo.gl/Fmnq04)