



Hülya Erbaba¹ and Gül Pinar^{2*}

¹Hülya Erbaba, Nursing Department, Ankara Yıldırım Beyazıt University, Turkey

²Gül Pinar, Nursing Department, Ankara Yıldırım Beyazıt University, Turkey

Received: 31 May, 2019

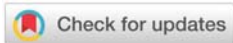
Accepted: 16 July, 2019

Published: 17 July, 2019

***Corresponding author:** Gül Pinar, Yıldırım Beyazıt University, Faculty of Health Science, Department of Nursing (Formerly), Bilkent Campus, zip code: 0810, Ankara-Turkey, Tel: 05337278255; E-mail: gpinar_1@hotmail.com

Keywords: Orem's self-care theory; Axillary ectopic breast tissue; Fibro-adenoma; Nursing care

<https://www.peertechz.com>



Case Report

Fibroadenoma of bilateral axillary ectopic breast tissue: A rare case report based on Orem's Self Care theory

Abstract

Introduction: Ectopic Breast Tissue (EBT) is still a condition seen as sporadic (2-5%), and it is often delayed and ignored due to lack of awareness, whereas it may be exposed to malignant diseases. It must be always kept in mind for differential diagnosis of an EBT. We think that this case report is important because EBT associated with fibro-adenoma is a quiet rare condition.

Method: A 41-year-old female who has just given birth presented in bilateral axillary EBT with fibro-adenoma. In order to present the nursing management to our case during hospitalization, Orem's (2001) self-care deficit theory and North American Nursing Diagnosis Association (NANDA) classification system were used.

Results: Both axillary nodules were swelling and painful during lactation, measuring 6 cm × 3 cm and of 4 cm × 3 cm in left and right axilla respectively. There was no nipple or areola over the both axillary nodules. However, we encountered a nipple without areola under the right breast. An excisional biopsy was performed under local anesthesia for the nipple and it revealed EBT. An EBT with fibro-adenoma was detected in the cytopathology of fine needle biopsy performed in both axillary nodules. Mammograms of both breasts were normal, no carcinoma was found. Based on Orem's self-care theory, this problem which has occurred as acute, led to the patient experience discomfort, decrease in daily activities, aesthetic concern, self-care problem and anxiety related to breast health. A patient-specific nursing plan was applied using NANDA classification system and each process of self-care needs was evaluated with patient data. Our case was discharged on the 7th day without any complications. After one week, her sutures were removed when she came for control examination.

Conclusion: It was determined that our patient entered the normalization process, regained her self-confidence and self-care power.

Abbreviations

EBT: Ectopic Breast Tissue; NANDA: North American Nursing Diagnosis Association

Introduction

The presence of more than two breasts called polymastia or EBT is a developmental anomaly and is a rare condition (2%-4%). However, a high level of suspicion for carcinoma is necessary when confronted with a nodule in this region. EBT can be located in different regions between inguinal region and axilla (Figure 1) along milk line [1,2]. In the literature, EBT is most commonly seen in the axilla, it has also been reported in the neck, chest, hip, vulva, shoulder, thigh, perineum, upper extremities and middle back including the facial region. EBT may be affected by hormonal changes, like normal breast

tissue, and may exhibit similar proliferative changes. Its prevalence in the general population is 2-6% [2,3] and can be seen in both sexes, mostly in Asian societies, however, two-

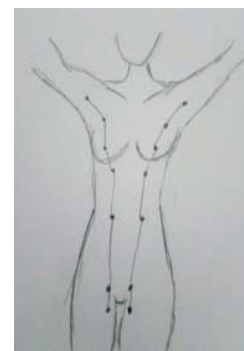

Figure 1: Breast Milk Line.

times more in females [4,5]. EBT can be sporadic or familial. In hereditary; X-linked autosomal dominant inheritance or X-linked recessive transition may occur through. In the pedigree studies related to polymastia; Although an X-linked dominant inheritance could not be ruled out, it was found to be consistent with the autosomal dominant gene in variable expression [6,7].

EBT usually occurs as an accessory breast without an areola and a nipple. It is generally asymptomatic and can be silent or manifest itself with menarche in adolescence or with symptoms during menstruation, pregnancy and lactation because the glandular epithelium shows positive reaction for estrogen and progesterone receptors [8]. Along with symptoms such as limitation of arm movements or pain, pathologies such as cosmetic problems, swelling, abscess, mastitis, breast fistula, cysts, fibro-adenoma, hematoma, phyllodes tumor, and rare carcinoma may also occur [9,10]. The diagnosis of EBT can be performed easily by USG and fine needle aspiration, and can be seen with pyloric stenosis, heart, ear, urinary tract anomalies, and kidney adenocancer [11]. However, still no specific protocols on EBT for diagnosis and treatment are available.

As the self-care power increased in the previous studies, it was found that the quality of life increased statistically highly significantly [12-14]. Therefore, it is recommended that EBT should be included during regular screening surveillance to avoid any delay in diagnosis and treatment. The purpose of this case presentation is to review the information on EBT with fibro-adenoma, then to determine the self-care needs according to the Orem's theory and to offer suggestions to the literature for clinical follow or health-care (Figure 1).

Method and Process

We determined the needs of our case according to Orem's (2001) self-care theory and we used the Nursing Care Plan-NANDA to help eliminate various problems in the hospitalization period [15,16]. In the self-care theory, for the nurse to help the patient, to teach the help methods and to provide the appropriate options seems important. In line with this theory, we aimed to evaluate the health of our patient, to organize the data, to analyze, to evaluate the attempts and to increase the self-efficacy towards solving the problems as outcome. Verbal consent was obtained from her and her family and from the unit where she was being treated for using the scientific data of the case. In this stage, let's examine how we address the case and the problems of our case with nursing approaches according to the self-care theory of our patient who was admitted to the obstetrics and obstetric surgery due to birth and treated with the diagnosis of axillary EBT with fibro-adenoma.

Kajava (1915) published a classification system for supernumerary EBT that still remains in use today [17]. This present case belonged to class-II (Table 1).

Case Report

The 41-year-old multiparous case had a height of 164 cm and weight 78 kg. She was a high school graduate, housewife,

Table 1: Kajava Classification System for EBT.

Class I	Complete breast with nipple, areola, and glandular tissue
Class II	Consists of nipple and glandular tissue but no areola
Class III	Consists of areola and glandular tissue but no nipple
Class IV	Consists of glandular tissue only
Class V	Consists of nipple and areola but no glandular tissue (pseudomamma)
Class VI	Consists of a nipple only (polythelia)
Class VII	Consists of an areola only (polythelia areolaris)
Class VIII	Consists of a patch of hair only (polythelia pilosa)

lives in nuclear family, and had social security and a moderate economic income. The cesarean section (C/S) was performed by spinal anesthesia to our case on 10/29/2015 and the patient was hospitalized to the service for postpartum care. The baby of our case was in the newborn unit and had no health problems. The contact of the mother and her baby was ensured during the breastfeeding process. At the end of the postpartum second day, the patient was taken to further examination with the complaint of acute pain and swelling in the both axilla. No co-morbid disease of our case. Family history of breast cancer was not found, her mother had also axillary EBT history during lactation. The patient's medical history; when she was 13 years old she admitted to the hospital with the changes such as in axillary region of the right breast with a hard swelling, and darkening of the skin pigment. The patient underwent excisional biopsy in the right axillary nodule. Histologically, an EBT-induced mass was diagnosed. When the patient was 19 years old, after severe pain and tenderness complaint, excisional surgery of axillary EBT was performed. Carcinoma was not found (Figure 2).

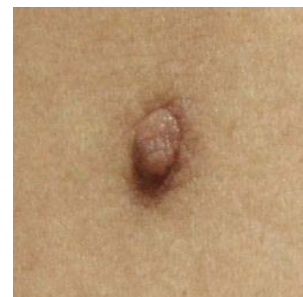

Figure 2: Clinical photograph of a nipple-like formation without areola under the right breast.

According to the current patient chart, the first and second births of our case were performed as normal vaginal delivery. The recurrence right axillary EBT was observed on 1st postpartum day during lactation. At the third birth (C/S) on 2nd postpartum day during lactation, right axillary EBT relapsed again. In this process, our patient stated that ordered 2x1 steroid painkillers were applied during the stay in the hospital. She had been breastfeeding her baby frequently due to engorgement on the advice of her doctor and nurse. The right axillary EBT had regressed gradually. Now, our case was the fourth birth (C/S) and on 2nd day postpartum during lactation a local recurrence

in the both axillary EBT with fibro-adenoma was detected. Because our patient could not comfortably breastfeed her baby due to the pain and pruritus on both axillary EBT and could not perform her daily activities. The nipple was also apparent under the right breast (Figure 2). Ultrasonography confirmed the presence of fibro-glandular tissue at the site of axillary. When the swellings were compressed, a small amount of colostrum-like fluid was expressed from the nipple and skin pores. The pillow support between the arms and the body, she was followed more closely. In ultrasound examination was also detected at the right axilla, approximately 4x3 cm EBT, at the left axilla 6x3 cm EBT separated from the breast tissue. Both breasts were normal.

In our case, an excisional biopsy, which is diagnosis and treatment intended. As our case was not volunteering for excision related to both axillary EBT at that time. The nipple was just removed under the right breast with the local anesthesia. The result of fine needle biopsy confirmed EBT. In addition, urogenital and renal ultrasound and echocardiographic examinations were performed in our case to investigate any anomalies and no anomalies were detected.

The patient was taken to analgesic and antibiotic treatment. No complication related to the operation was observed during the follow-up. The region where EBT is located on day 2 and 5 postpartum is given (Figures 3,4). She continued breastfeeding, pumping and nursing care plan for complaints. The swelling was slightly smaller (about half of initially observed) by the next days and from it no milk could be expressed through the skin. Finally, satisfactory breast-

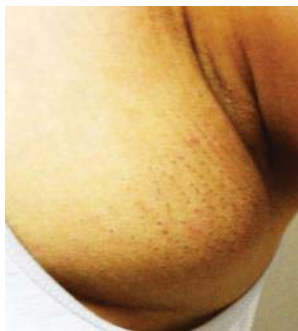

Figure 3: Clinical photograph of EBT in the left axilla on the 2nd postpartum day.

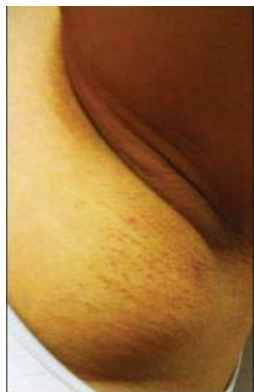

Figure 4: Clinical photograph of EBT in the left axilla on the 5th postpartum day.

feeding was soon established and the comfort of the patient was provided during hospitalization. The patient was advised regular follow-up by breast (examination and mammography), Our case was discharged on the postoperative 7th day and she was seen again after ten days, her complaints were much less as on the day of discharge (Figures 3,4).

Practices for theory of self-care

Self-care requisites: In this section, the above-mentioned individual properties, the self-care power of her and limitations.

Universal self-care requisites and developmental self-care requisites:

- Nutrition: It has been found that she does not pay much attention to her nutrition and she eats a lot of food especially under stress.
- Oral health: There is deformation in teeth, no regular brushing habits.
- Perineum hygiene: Patient explained that she does not have energy to make perineal hygiene needs for prevent infection.
- Activity: In our case, there was activity limitation, weakness, and partial dependence on the bed as a result of the pain and tissue integrity deterioration with a nipple excision and both axillary EBT.
- Body Mass Index (BMI): Weight gain (high BMI before and after pregnancy), mean daily fluid intake 1500 cc isotonic, physiological saline solution, ringer lactate solution etc.
- Sleep/rest: have trouble falling asleep.
- Cognitive detection: There is perceived pain.
- Physical evaluation; abdominal region: C/S related sutures present; vital signs are normal, no edema, redness, evisceration, and ulceration at the surgical site. Perineum: no vaginal bleeding, lochia is normal.
- Elimination: No properties. There is no problem with the daily follow-up of intake-output.
- Coping with stress; insufficient family support, loneliness, unwillingness to communicate

Health deviation self-care requisites

The self-care agent was our case in person. Our patient was doing partly take her self-care on. However, she needed health personnel and family caregivers as a dependent agent. Despite the both axillary EBT, which recurred in her previous birth, our patient did not complete the recommended routine controls and treatment process except for palliative measures. In terms of deviation from health, despite the complaints of our case, we saw that she experienced neglect and delay in receiving the health service. The solution to the problem was looked for on the increasing complaints in the early lactation

period. However, this experienced delay could lead to the observation of a number of pathological changes such as EBT lymphadenopathy or carcinoma. In this sense, it was seen that she did not have sufficient health awareness and orientation. Although our patient was motivated to adapt to pain-related interventions in her final hospitalization, it was noticed that she had difficulty in perceiving the general procedures communicated to her. It is also considered to be a deviation and impediment in the development of self-care requirements of all these conditions such as an unintended pregnancy, lack of knowledge about birth control, nutrition and weight control. The requirements of deviation from the health and the universal and developmental self-care requirements are possible with nursing diagnosis and evaluation, like a balance.

Nursing systems theory

According to Orem's (2001) theory, there are three nursing systems; 1) Wholly compensatory system, 2) Partly compensatory system, and 3) Supportive-educative system. This approach has an important place in terms of supporting and guiding. Due to its suitability to our case, it was decided to use supportive and educative nursing system in this study.

The nursing approach in this model; 1) Assessment to determine the problem, 2) Diagnosis of nursing care plan, 3) Nursing intervention and evaluation. According to this, the process followed, nursing procedures are as follows:

- Nursing Diagnosis Classification

Two separate interviews and assessments were held in the appropriate time and environment, which were determined as a result of the cooperation with the patient:

First interview and follow-up (the 1st day);

Prior to our first meeting, it was noteworthy that the patient was drowsy, avoiding eye contact, and unwillingness to talk. In order to recognize the patient and to raise her self-care awareness, she was helped to express herself by making her feel safe and secure. In this interview, our case has stated that the last pregnancy is not planned, that she consumes a lot of energy with the care of children and households, having both axillary EBT that has been recurring since childhood and causing both decreased self-confidence and aesthetic care, and that she has not received enough support from her spouse in general, that she experienced frustration, fatigue and unwillingness to communicate with people as a result of recurrence with her last birth. In the clinical examination; her vital signs were normal (blood pressure: 120/80 mmHg, pulse: 80/min, respiration: 20/min, no fever, saturation: 99%).

Second interview and follow-up (the 2nd day);

Our case has stated that she has gradually increased sensitivity at the C/S site and at the both axillary region (it was obvious by the body language of our patient such as filling of our patient's eyes with tears, teeth tightening, groaning, grimace), reduced comfort, stress, anxiety, sleep problem, fatigue, weakness, pain, restriction in arm movements, difficulty in

fulfilling self-care, engorgement, difficulty in breastfeeding, delay in maternal-infant attachment, and that she experienced guilt and anxiety because of inability to fulfill care of and being separated from children at home and her newborn baby. Our case had been breast-feeding with difficulty and seen that her breasts were beginning to become engorged, but there were no signs of mastitis. Because of the engorgement, mastalgia and acute pain in the axillary region, she also cannot move her arms and has difficulty in postural changes. In this process, our patient felt tired because she could not sleep sufficiently. The patient's questions were answered. All these experienced problems are the factors that affect the self-care needs.

In the light of all these information, the list of the problems of our case according to NANDA classification systems is given in Table 2.

Table 2: Classification of Nursing Diagnosis-NANDA.

First interview and follow-up	Second interview and follow-up
1. Risk of infection	11. Acute pain
2. Risk of hemorrhage	12. Engorgement, ineffective breastfeeding
3. Anxiety	13. Breastfeeding interrupted
4. Ineffective coping with stress	14. Disturbed of sleep pattern
5. Impaired verbal communication	15. Ineffective hygiene
6. Self-care deficit	16. Deficient knowledge on disease
7. Impaired of skin integrity	17. Impaired physical mobility
8. Ineffective social support	18. Alteration in feeding pattern
9. Low self-esteem	19. Caregiver role strain
10. Disturbed in the body image	20. Alteration in family processes

- Nursing Interventions Classification

- Our patient was welcomed with a smile and her orientation to clinic was provided with the necessary explanations regarding the hospital processes. Her questions were answered, and then she was communicated continuously and trust was provided. In order to improve family processes and motivation, the visit of her husband and family was provided and they were talked about the importance and results of the support to our patient. She was provided to spend time with her husband, mother and baby. Her husband also said that she should not worry that the children in the house are closely cared for by their relatives.
- In our case, the ice pack application for both axillary engorgement and pain reduction was performed 10-12 times a day for 10 min every two hours, except for rest and sleep hours. In the application, the ice pads defined as gel pads were softened to be compatible with the site before use. Wrapped in a cloth to avoid direct contact with the skin and placed on the both axillary region. The importance of the procedure and how it is done was taught to the patient, in addition to the planned periods with close follow-up, so as not to exceed 10 min, it was applied in person. Although our patient

reported irritation from cold application from time to time, compliance with the treatment was provided due to pain relief. Besides, to avoid engorgement, milking emptied the patient's breasts, and she was allowed to breastfeed her baby during the planned periods.

- The patient was given appropriate position in the breastfeeding and resting process, and was supported with 1x1 non-steroidal analgesics (paracetamol) in cases of extreme pain (Visual analogue scale for pain: 8-10). The daily vital signs were monitored every 4 hours after C/S and then every eight hours, and daily output fluid monitoring was performed.
- The dressings in the operation site were changed at regular intervals. *Aseptic conditions were noted.* There was no evidence of infection in the suture area and IV vascular access. Sutures of the nipple excision under the patient's right breast were removed on the 7th day.
- Our case was helped when she mobilized. With the coordination of activities, rest periods were also provided.
- She was encouraged and supported to continue breastfeeding. Arranging the environment that would facilitate the baby and her to be able to breastfeed and take positions ensured the mother-infant interaction.
- Self-care activities of our case were helped in the following, she was provided to carry out her self-care as much as possible. Patient's self-care capacities were evaluated such as controlling oral care, body bath, perineal hygiene, providing clean clothes, breastfeeding, mobilization etc.),
- Standard perineal pads were changed at frequent intervals (5-6 times) and weighed and recorded. On the 5th day the lochia color was light pink, yellow. The clot was not observed. The involution period was normal. The fundus was palpated hard. *It was 4 cm below the umbilicus on the second day and could not be palpated from the abdominal wall on the 7th day.*
- In order to develop self-care behaviors, both our patient and her family were informed that fibro-adenoma associated with EBT was generally benign, may be malignant, and that breast cancer could be encountered and therefore periodic controls should be performed. In addition, the patient was trained on family planning counseling, development of her baby, breastfeeding training, methods of coping with stress, exercise, nutrition and weight control, and she was discharged on the seventh day.

- Nursing Outcomes Classification

- At the first interview, it was observed that our patient had difficulty in perceiving the procedures communicated to her, she appeared unwilling, however, she expressed herself better by being by her side and empathic

approach, and increased attention, perception and ease of adaptation to the healing process was observed.

- In the evaluation, it was determined that the breast filling at the end of milking and ice application decreased very much from the 3rd day of lactation and healed in a shorter time. In addition our patient stated that her pain complaint was decreased substantially (pain scale: 2-3).
- As a result of decreasing engorgement and pain, it was observed that our patient had more comfortable activity, ease of breastfeeding, self-care could be more comfortable and rest periods increased.
- There was no infection in the operation site. Skin integrity was achieved.
- There was no vaginal bleeding or infection to suggest uterine atony as a result of follow-up and care. The involution process was as expected.
- Following the reduction of pain and tension, the activity restriction was greatly reduced. Our patient stated that she was able to make more comfortable arm movements and was mobilized.
- The patient stated that she felt more comfortable and focused more on her baby due to the lack of any problems related to her and her baby's health with the support of the family, the treatment regime applied and the proper nursing care.
- Our case indicated that with postpartum follow-up, care, and evaluation she had sufficient awareness about axillary EBT disease and postnatal period regarding her and her baby.
- She expressed that with the elimination of the physical disorder and the elimination of the loss of function, she had regained her self-confidence.
- Since our patient did not want to have a baby again, she stated that she was thinking about the intrauterine device as a method of family planning.
- The patient was discharged on the seventh postpartum day without any complications and one week later, her sutures were removed when she came for control examination. At this stage, the questions of our case were answered, necessary explanations were made and it was determined that our patient entered the normalization process according to her own statements, regained her self-confidence and self-care power.

Results

In this study, patient's self-care needs were identified under the guidance of "the self-care theory" and independency was improved by the compensatory care activities. Our evaluations also indicated that our patient was developed self-care behaviors and the positive impact of using this care model on her life quality.

In our case, as a result of nursing power, nursing systems, diagnosis and nursing interventions; it was determined that the pain and engorgement problems are solved, no signs of infection and bleeding are observed, self-care involvement status and self-confidence was increased, more effective breastfeeding was maintained, the correct methods of coping with stress and communication had begun to use, the sufficient information related to disease process and lifestyle owned to improve the health.

The components of the nursing power which are the ability of the nurse to obtain valid and reliable information, decision-making and application ability, the desire to give nursing care, eliminating the deficiency, increasing the patient's contribution with supportiveness and instructiveness, the continuity of performance, the ability to see different situations in the process of achieving the goal and integration competence were linked to the self-management competence of our case and increased the self-care power.

Discussion

In this section, other conducted studies on the subject and our findings were discussed. We maintained proper nursing interventions determined by the complete and partial compensation nursing diagnostic system, and the needs of our case were met following the supportive educational nursing approach. When we examine at the literature, the nursing care management according to the Orem's (2001) self-care theory, patient care, and theory based nursing care and various disease groups were examined. Renpenning et al. (2011) [18], have reported that self-care theory can be addressed together with the nursing diagnostic system and that the adaptation of this approach to the nursing curriculum may be appropriate. Kilic (2005) [19], has found that nursing care given in accordance with the self-care model was effective in preventing and reducing the possible side effects after C/S delivery. Kumar (2007) [20], in the study evaluating nursing care based on Orem's theory of a patient with Type II Diabetes, stated that theory based nursing care improves the person's ability to manage his/her disease in chronic diseases such as diabetes. The results of the study by Mohamed et al (2016) [21] substantiated the effect of their developed self-care program on the dependence level of hemodialysis patients. All of these studies are consistent with the results of the present research.

EBT is a rare condition in the literature. These anomalies are frequently seen first postnatal examination [22,23]. In our report EBT, a congenital condition, was localized in the both axilla. This problem has been identified with the first menarche in our patient. But, fibro-adenoma with EBT was detected at the last postpartum period. Histologically similar to fibro-adenoma of the breast, it is also a benign tumor of breast tissue. In some studies, it has been reported that patients with EBT have limited mobility, pain, sensitivity and sometimes shoulder-arm movement restriction [22,24-26]. In our case, axillary EBT, which was noticed by puberty and then differentiated with recurrence, has been detected to grow rapidly and cause pain and aesthetic problems since the first pregnancy. In other studies related to the subject, being seen

of the pathologies such as fibro-adenoma in EBT containing glandular parenchyma [27], being palpable of the particularly acute axillary EBT due to engorgement during lactation, the presence of complaints of swelling and pain accompanying the masses can cause anxiety in women by causing a malignant condition [5]. It was noted that our patient experienced this anxiety and emotional intensity in a similar way during her admission to the clinic. Although fibro-adenoma of EBT is generally benign, it should be kept in mind that almost all of them can face breast cancer. In this sense, in addition to psychological support, our patient was informed about the importance of regular annual controls taking into account the recurrence and clinical features.

In our case, cold application was planned to relieve acute pain and engorgement complaints. Because cold application can be effective in reducing pain and edema in two ways either indirectly or directly. The tissue stimuli made with cold pads reduce the pain and engorgement by creating an analgesic effect with the door control mechanism and other mechanisms that provide the release of endorphins. In addition, as the tissue is cooled, the rate of nerve conduction is decreased and pain transmission blockage is achieved [5]. In our case, how the cold application will be performed and its importance was taught and the pain and engorgement problems were eliminated by providing the ice packets application in person in a way not to exceed 10 minutes in addition to the planned periods.

Besides, the patient's information about breastfeeding techniques were updated for avoiding the engorgement, and her breasts were emptied at planned intervals by milking and encouraged to breastfeed, and thus her engorgement problem was solved. The results obtained from other studies also support this finding. In a study conducted in order to reduce breast engorgement during lactating period, 53 mothers who had delivered by C/S were given training on breastfeeding techniques for 10 days and it was revealed that training significantly reduced postpartum engorgement in postpartum period [28]. In another experimental study on 68 women, it was shown that frozen cabbage leaves and frozen gel pack were effective in inhibiting and reducing pain [29]. Two different studies in which cold and hot treatments were performed respectively, the cold compress was found to be more effective in reducing pain [23,30]. In the study of Goyal et al. (2014) excision of EBT was done for cosmetic, psychological and therapeutic reasons. Even liposuction has been tried with good results [31].

Conclusion

In conclusion, all these aforementioned positive development reflect the self-care power and self-care behaviors of our case. It is thought that our case will be reflected in management of health-care and thus literature will also be contributed. These interesting developmental anomalies should be taken into account by the health-care team due to the paucity of research in this area. Thus, it is suggested that this program be integrated into the multidisciplinary clinic plans of these patients. Further studies should be made an attempt to specify the effect of implementing the self-care program on healthy life-style in these patients.

Acknowledgment

Authors would like to acknowledge the entire staff of the Department of Gynecologic, a State Tertiary Hospital, Ankara-Turkey.

References

- Zucca-Matthes G, Urban C, Vallejo A (2016) Anatomy of the nipple and breast ducts. *Gland Surgery* 5: 32-36. [Link: http://bit.ly/2JzKNUi](http://bit.ly/2JzKNUi)
- DeFilippis EM, Arleo EK (2014) The ABCs of accessory breast tissue: basic information every radiologist should know. *AJR Am J Roentgenol* 2014; 202: 1157-1162. [Link: http://bit.ly/2LPuvuQ](http://bit.ly/2LPuvuQ)
- Mikhael S, Nilsson W, Patel K, Graf S (2017) Ectopic Breast Tissue of the Vulva in a Postmenopausal Woman. *Case reports in obstetrics and gynecology* 7581750. [Link: http://bit.ly/30E82SZ](http://bit.ly/30E82SZ)
- Ersilia MD, Elizabeth KA (2014) The ABCs of Accessory Breast Tissue: Basic Information Every Radiologist Should Know. *American Journal of Roentgenology* 202: 1157-1162. [Link: http://bit.ly/2NWahQ3](http://bit.ly/2NWahQ3)
- Arora BK, Arora R, Aora A (2016) Axillary accessory breast: presentation and treatment. *International Surgery Journal* 3: 2050-2053. [Link: http://bit.ly/2LoBRTU](http://bit.ly/2LoBRTU)
- Urbani C E, Betti R (1995) The significance of familial polythelia. *Journal of the American Academy of Dermatology* 32: 687-688. [Link: http://bit.ly/2JzLdtQ](http://bit.ly/2JzLdtQ)
- McKay M, Ryan C (2017) A brother and sister with breast cancer, BRCA2 mutations and bilateral supernumerary nipples. *Annals of translational medicine* 5: 106. [Link: http://bit.ly/2xRZWcY](http://bit.ly/2xRZWcY)
- Kim YS (2004) Correction of accessory axillary breast tissue without visible scar. *Aesthet Surg J* 24: 531-535. [Link: http://bit.ly/2xWwdzv](http://bit.ly/2xWwdzv)
- Tuhin S, Shruti S, Rekha S (2017) Bilateral accessory breast: a case report from Nepal. *J Head Neck Spine Surg* 1: 551-555. [Link: http://bit.ly/2GgCnN](http://bit.ly/2GgCnN)
- Singh S, Yadav H, Srivastava D, Sen R (2015) A rare finding of coexisting fibroadenoma and duct ectasia in axillary ectopic breast tissue. *J Interdiscipl Histopathol* 3: 110-112. [Link: http://bit.ly/2JBR41R](http://bit.ly/2JBR41R)
- Down S, Barr L, Baildam AD, Bundred N (2003) Management of accessory breast tissue in the axilla. *British Journal of Surgery* 90: 1213-1214. [Link: http://bit.ly/2XVHD1g](http://bit.ly/2XVHD1g)
- Kusnanto K, Sari N, PW P, Harmayetty H, Efendi F, et al. (2018) Self-care model application to improve self-care agency, self-care activities, and quality of life in patients with systemic lupus erythematosus. *J Taibah Univ Med Sci* 13: 472-478. [Link: http://bit.ly/2JBghJF](http://bit.ly/2JBghJF)
- Gao Y, Chen Y, Wenhui YI, Chen J (2017) Orem self-care nursing for patients with liver cirrhosis based on comprehensive evaluation software system of organ function. *Chin J Prim Med Pharm* 24: 1974-1977.
- Graven LJ, Grant JS (2014) Social support and self-care behaviors in individuals with heart failure: an integrative review. *Int J Nurs Stud* 51: 320-333. [Link: http://bit.ly/2YVOvgv](http://bit.ly/2YVOvgv)
- Orem DE (2001) *Self-care deficit theory of nursing: concepts and applications*. 7nd ed. USA: Dennis CM MosbyYear Book Inc 99-135.
- Carpenito-Moyet LJ () *Handbook of Nursing Diagnosis*. 13th edition. Lippincott Williams and Wilkins, Philadelphia, USA.
- Kajava Y (1995) The proportions of supernumerary nipples in the Finnish population. *Duodecim* 1: 143-170. [Link: http://bit.ly/2XVAP3s](http://bit.ly/2XVAP3s)
- Renpenning KM, SozWiss GB, Denyes MJ (2011) Explication of the nature and meaning of nursing diagnosis. *Nurs Sci Q* 24: 130-6. [Link: http://bit.ly/2NX3TII](http://bit.ly/2NX3TII)
- Kılıç A (2005) Dorothy Orem'in öz bakım modelinin sezeryan ile doğum yapan kadınların hemşirelik bakımına uyarlanması. *Yayınlanmamış Doktora Tezi, Ankara: Gülhane Askeri Tıp Akademisi Sağlık Bilimleri Enstitüsü* 72-73.
- Kumar CP (2007) Application of Orem's self-care deficit theory and standardized nursing languages in a case study of a woman with diabetes. *Int J Nurs Terminol Classif* 18: 103-10. [Link: http://bit.ly/2SkVfSp](http://bit.ly/2SkVfSp)
- Mohamed SK, El-Fouly Y, El-Deeb M (2016) Impact of a designed self-care program on selected outcomes among patients undergoing hemodialysis. *Int J Res* 4: 73-90. [Link: http://bit.ly/2Lo0vEk](http://bit.ly/2Lo0vEk)
- Amaranathan A, Balaguruswamy K, Bhat RV, Bora MK (2013) An ectopic breast tissue presenting with fibroadenoma in axilla. *Case Rep Surg* 947295. [Link: http://bit.ly/2JQqegX](http://bit.ly/2JQqegX)
- Arora S, Vatsa M, Dadhwal V (2008) A Comparison of Cabbage Leaves vs. Hot and Cold Compresses in the Treatment of Breast Engorgement. *Indian Journal of Community Medicine* 33: 160-162. [Link: http://bit.ly/2Z1tW2g](http://bit.ly/2Z1tW2g)
- Lakkawar NJ, Maran G, Srinivasan S, Rangaswamy T (2010) Accessory breast tissue in the axilla in a puerperal woman - Case study. *Acta Med Medianae* 49: 45-48. [Link: http://bit.ly/32yXXbU](http://bit.ly/32yXXbU)
- Echchaoui A, Daoud G (2016) Axillary Accessory Breast Tissue Mimicking Lipoma. *Galician Medical Journal* 23: 1-3. [Link: http://bit.ly/2SjleBM](http://bit.ly/2SjleBM)
- Gutermuth J, Audring H, Voit C, Haas N (2006) Primary carcinoma of ectopic axillary breast tissue. *J Eur Acad Dermatol Venereol* 20: 217-221. [Link: http://bit.ly/2xOcFgI](http://bit.ly/2xOcFgI)
- Cho J, Ahn S (2014) Development and evaluation of breastfeeding promotion program for mothers with breast engorgement following cesarean birth. *Journal of Korean Academy of Nursing* 44: 170-178. [Link: http://bit.ly/2GecwRA](http://bit.ly/2GecwRA)
- Manna M, Podder L, Devi S (2016) Effectiveness of hot fomentation versus cold compression on breast engorgement among postnatal mothers. *International Journal of Nursing Research and Practice* 3: 13-17. [Link: http://bit.ly/2xOgGlo](http://bit.ly/2xOgGlo)
- Roberts KL (1995) A Comparison of Chilled Cabbage Leaves and Chilled Gelpaks in Reducing Breast Engorgement. *J Hum Lact* 14: 231-236. [Link: http://bit.ly/32vnEtL](http://bit.ly/32vnEtL)
- Trisal M, Hassan MJ, Rana S, Mohroo RN, Jetley S (2018) Fibroadenoma arising in accessory breast tissue of the axilla: a rare case report. *Archives of Cytology and Histopathology Research* 3: 105-106. [Link: http://bit.ly/2Soji34](http://bit.ly/2Soji34)
- Goyal S, Bawa R, Sangwan S, Singh P (2014) Fibroadenoma of axillary ectopic breast tissue: A rare clinical entity. *Clin Cancer Invest J* s3: 242-244. [Link: http://bit.ly/2LUscKE](http://bit.ly/2LUscKE)