

Thanh Ma Ngoc^{1,2}, Dung Tran Trung^{1-3*}, Manh Nguyen Huu³, Khanh Trinh Le³, Quyet Tran⁴ and Ban Hoang Van³

¹Hanoi Medical University, Vietnam

²Hanoi Medical University Hospital, Vietnam

³Saint Paul University Hospital, Vietnam

⁴Phu Tho General Hospital, Vietnam

Dates: Received: 21 November, 2017; Accepted: 11 December, 2017; Published: 13 December, 2017

***Corresponding author:** Dung Tran Trung, Associate Professor, MD, PhD, Hanoi Medical University, No. 1, Ton That Tung Street, Hanoi, Vietnam, Tel.: +84-24-238523798; Fax: +86-24- 38523798; E-mail: dungbacsy@dungbacsy.com

Keywords: carpal tunnel syndrome, mini-open surgery

<https://www.peertechz.com>

Research Article

The Result of Mini-Open Surgery for Carpal Tunnel Syndrome

Abstract

Objective: evaluate the results of mini-open surgery for carpal tunnel syndrome (CTS)

Patients and method: Prospective study of 56 hands (43 patients) with carpal tunnel syndrome, who underwent mini-open carpal tunnel release surgery in Hanoi Medical University Hospital

Results: The ratio of women was 95.4%. The mean age was 50.3 years. There were 23 patients (53.4%) of right hand CTS and 13 patients (30.4%) of both hands CTS. According to Padua's classification, 11.6% of patients had extreme CTS. The improvement of clinical symptoms and electrorheological test can be seen at 2 weeks after surgery. There were no complications.

Conclusion: Mini-open surgery for carpal tunnel syndrome had good results.

Introduction

Carpal tunnel syndrome (CTS) is a medical condition due to compression of the median nerve as it travels through the wrist at the carpal tunnel. This is one of the most common syndromes of peripheral neuropathy pinched, women are more commonly affected than men and it is more happening in preferred hand [1]. In America, the incidence rate of carpal tunnel syndrome is 50/1000 people per year, up to 500/1000 people in high-risk group [2].

In recent years, there has increased the incidence rate of carpal tunnel syndrome, may be due to the awareness of people about this disease, the upward disease detection rate, the work is more and more meticulous and delicate required using wrist continuously [2,3].

70% of carpal tunnel syndrome patients are of unknown causes, the others are intrinsic and extrinsic factors. Intrinsic factors which exert pressure within the tunnel are pregnancy, hemodialysis, gout, diabetes and so on. Extrinsic factors which exert pressure outside the tunnel are lipomas, ganglion and vascular malformation which change the size of the carpal tunnel then increase the pressure [1,4].

Increasing pressure into median nerve results in pain, numbness, tingling or burning sensations in the thumb, index, middle and ring finger because they receive sensory and motor function from the median nerve or even worse maybe atrophy, decrease or lost hand function. Carpal tunnel syndrome can

cure completely if it is detected early and timely treatment, otherwise it can leave permanent sequelae affected the work and daily-activity, leading considerable damage to people and all society. According to American statistic, there are 16440 workers who have to quit the job because of carpal tunnel syndrome in 2005. The costs and damages per person are up to 30,000 dollars [1].

Conservative treatment and rehabilitation are methods to treat carpal tunnel syndrome in the early stage. However, we have to consider surgery with the patient in late-stage to release the median nerve, avoid too much pressure causing irreversible damage. The matter of concern of the doctor as well as the patient is a scar after surgery because the intervention location is near wrist and hands related hold-activity. From 2010 to 2014, we performed mini-open surgery for a group patient with carpal tunnel syndrome at Hanoi Medical University Hospital for the purpose:

Evaluate the resulting treatment of carpal tunnel syndrome by minimally invasive surgery at Hanoi Medical University Hospital.

Material and Method

- Subjects: 43 carpal tunnel syndrome patients were diagnosed and treated at Hanoi Medical University Hospital by minimally invasive surgery from 2010 to 2014.

Inclusion criteria

- Adequate 3 factors to diagnose carpal tunnel syndrome: signs, symptoms and abnormal electrophysiological testing.
- Surgical indication:
- Not improved more than 3 months internal medicine treatment. Clinical findings and ultrasonography reveal median nerve pinched obviously.
- In late-stage: muscle atrophy, severe sensory disorder (severity was moderate or more severe according to Padua classification [5]).

Exclusion criteria

- ◆ Cervical spine injury
- ◆ Not re-exam after surgery

Methods: A prospective, longitudinal study.

Surgical technique: All patients in research group were performed surgery to release transverse carpal ligament (TCL) by minimally invasive surgery. Skin incision was placed on thenar crease, it started at the point where the thenar eminence meets the hypothenar eminence and extended 2cm distally. After dissecting through the subcutaneous tissue, the transverse carpal ligament was released. Verification of complete resection of the TCL was done by passing a dissector to feel if there is any remnant of the TCL. The skin was closed with a nylon suture, and a compression bandaging was used. After the surgery, patients were immobilized with a hand splint for 2 weeks.

Research indicators

- **Clinical features:** Classified by Padua's classification with 5 grades of severity [10]:
 - **Extreme:** Absence of median motor and sensory responses.
 - **Severe:** Absence of sensory response, abnormal distal motor latency (DML).
 - **Moderate:** Abnormal sensory nerve conduction velocity (SNCV) and abnormal DML.
 - **Mild:** Abnormal SNCV, normal DML.
 - **Minimal:** Abnormal segmental/comparative test, normal standard tests.
- **Investigation:** Evaluate the level of change of potential time, amplitude and the velocity of motor and sensory transmissions.
- Other factors such as occupation, history and the onset of disease.
- Post-operative evaluation, compare indexes, evaluate the clinical and electrophysiological improvement.

- Evaluate the subjective results according to the subjective perception of the patients, the same with VAS scale. Patient self-evaluated the symptoms severity before and after surgery, therein pre-operative severity is considered 100%.

Statistical analysis was performed using SPSS Version 16.0.

Ethics approval

All patients were fully explained and they agreed to join this study. The study had fully criteria in ethical medical approval and we secure that their personal information will be kept confidential.

Results

This study included 56 hands (43 patients). The average age was 50.3±10.7 years. Women account for the majority of patients (95.4%). The number of patients who had CTS on right hand, left hand and both hands were 23 (53.4%), 7 (16.2%) and 13 (30.4%), respectively (Table 1).

The number of patients who had extreme, severe and moderate CTS were 5 (11.6%), 33 (76.8%) and 5 (11.6%), respectively. There were neither mild nor minimal CTS. Five patients (11.6%) were in the late-stage, who had muscle atrophy (Table 2).

The improvement of the symptoms after surgery

At 2 weeks after the surgery, according to subjective evaluation of patients, 28 hands (50%) had a more than 50% reduction in symptom severity (RSS), 15 hands (26.8%) and 13 hands (23.2%) had 30–50% and less than 30% reduction in symptom severity, respectively (Figure 1).

At 2 months after surgery, 30 hands (53.6%) had a more than 80% RSS, 21 hands (37.5%) had a 50–80% RSS and 5 hands (8.9%) had a less than 50% RSS (Figure 2).

The improvement of electrophysiological test

According to the improvement of 3 parameters: potential

Table 1: Characteristics of patients

Characteristics		N	%
Gender	Male	2	4.3%
	Female	41	95.4%
Injured Hand	Right	23	53.4%
	Left	7	16.2%
	Both hands	13	30.4%

Table 2: The severity of injury according to Padua's classification

Severity	N	%
Extreme	5	11.6%
Severe	33	76.8%
Moderate	5	11.6%
Mild	0	0%
Minimal	0	0%

time, amplitude and velocity, we divided 56 hands into 3 groups: not improved, 1 or 2 parameters improved, 3 parameters improved.

At 2 weeks after surgery, 39 hands (69.6%) had improved in 3 parameters, 13 hands (23.2%) had improved in 1 or 2 parameters and 4 hands (7.1%) had not improved (Figure 3).

At 2 months after surgery, 100% of patients show improvement in electrophysiological tests, of which 37 hands (66.1%) had improved in 3 parameters and 19 hands (33.9%) had improved in 1 or 2 parameters. There were no unimproved hands (Figure 4).

Complications: In our study, no complications were observed (Figure 5).

Discussion

In this study, there were 43 patients with 56 operated hands. The average age was 50.3 ± 10.7 years. Women accounted for 95.4% patients. The incidence of right hand was greater than left hand. And the rate of both side CTS was 30.4% (Table 1). This was similar to the results of other researchers [2,6].

According to Padua's classification, extreme and severe CTS occurred in 88.4% of patients, moderate CTS occurred in 11.6% of patients, who poorly responded to the conservative

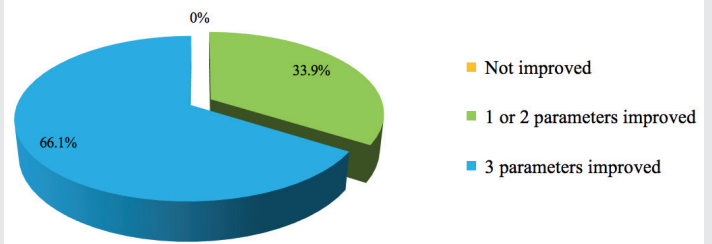


Figure 4: The improvement of electrophysiological test at 2 months after surgery.

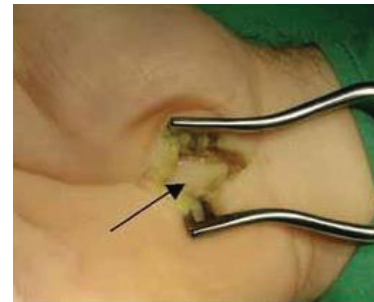


Figure 5: Median nerve was observed through a small incision.

treatment (Table 2). Five (11.6%) of operated patients suffered from muscle atrophy, they had an absolute indication for the surgery, nevertheless their clinical recovery was limited. At 2 months after surgery, only 5 operated hands had a less than 50% reduction in symptom severity (Figure 2). The rate of severe patients was similar to other authors [7-9].

When estimating the clinical results at 2 weeks after surgery following as subjective scale, we found that all patients obtained reduction in symptom severity, 50% of hands achieved more than 50% reduction in symptom severity compared to before surgery. At 2 months after surgery, the improvement of symptom was even greater with 53.6% of hands had a more than 80% RSS. However, there were 8.9% of hands reaching less than 50% RSS (Figure 2). These cases almost were severely damaged with atrophy, so the recovery degree was lower. The severity of the symptoms before surgery was an element that decrease the improvement after surgery following as lots of authors' reports [1,2,7,9].

The improvement of neuronal electrophysiology was firstly evaluated at 2 weeks after surgery. There were 7.1% of hands showing no improvement on neuronal electrophysiology (Figure 3). Nevertheless, at 2 months after surgery, all hands had improvement in electrophysiological test, of which 66.1% of hands had improvement in all 3 parameters: APD (Action potential duration), amplitude and nerve conduction velocity (Figure 4). Other authors also reported about the slow recovery capacity of the postoperative parameter of neuronal electrophysiology [6,10]. The main cause was the compression leading to the lack of blood supply of the nerve as well as other damages, which require time to recover.

Mini-open surgery allowed us to directly control the nerve with the naked eyes to reduce the risk of nerve damages, which was one of the complications of the endoscopic surgery as well as other minimally invasive surgery techniques [3,4].

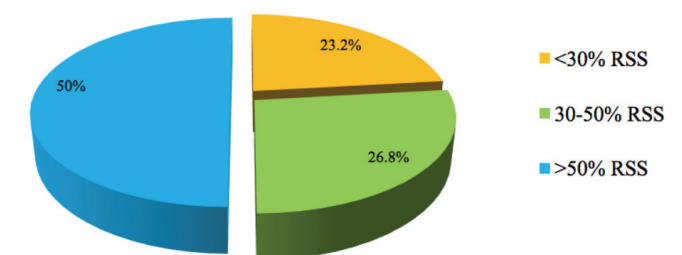


Figure 1: Reduction in symptom severity (RSS) at 2 weeks after surgery.

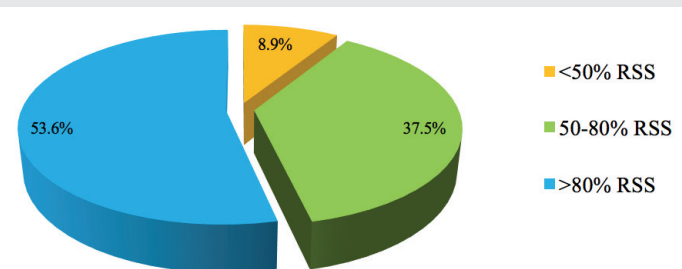


Figure 2: Reduction in symptom severity (RSS) at 2 months after surgery.

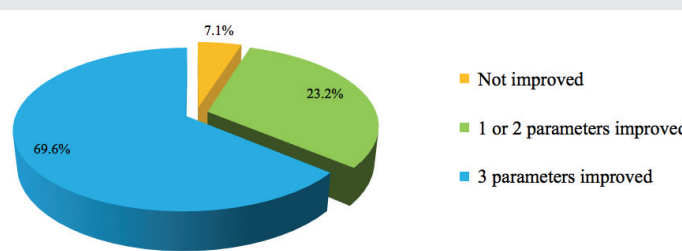


Figure 3: The improvement of electrophysiological test at 2 weeks after surgery.

Conclusion

After the study of 43 patients with 56 operated hands, we found that mini-open surgery has good results with the improvement of clinical symptoms as well as neuromuscular electrophysiology from the 2 weeks after surgery.

References

1. Wong KC, Hung LK, Ho PC, Wong JMW (2003) Carpal tunnel release - A prospective, randomized study of endoscopic versus limited-open methods. *J bone Joint Surg 85-B*: 863-868. [Link: https://goo.gl/RVs1uY](https://goo.gl/RVs1uY)
2. Jenkins PJ, Duckworth AD, Watts AC, McEachan JE (2012) The outcome of carpal tunnel decompression in patients with diabetes mellitus. *J Bone Joint Surg 94*: 811-814. [Link: https://goo.gl/Mnavd9](https://goo.gl/Mnavd9)
3. Palmer AK, Toivonen DA (1999) Complications of endoscopic and open carpal tunnel release. *J Hand Surg 24*: 561-565. [Link: https://goo.gl/5tP4Mn](https://goo.gl/5tP4Mn)
4. Kasdan ML (2000) Complications of endoscopic and open carpal tunnel release. *J Hand Surg 25*: 185.
5. Padua L, LoMonaco M, Gregori B, Valente EM, Padua R, et al. (1997) Neurophysiological classification and sensitivity in 500 carpal tunnel syndrome hands. *Acta Neurol Scand 96*: 211-217. [Link: https://goo.gl/BswfnS](https://goo.gl/BswfnS)
6. Kuschner SH, Lane CS (1997) Endoscopic versus open carpal tunnel release: Big deal or much ado about nothing? *Am J Orthop 26*: 591- 596. [Link: https://goo.gl/E9f3fe](https://goo.gl/E9f3fe)
7. Zicarelli CAM, Aguiar PHP, Sparapani FVC, Panagoupolos AT, Maldaun MVC, et al. (2008) Mini open carpal tunnel release. Clinical outcome and surgical technique in 48 cases. *J Bras Neurocirurg 19*: 21-22.
8. Katz JN, Simmons (2002) Carpal tunnel syndrome. *N Engl J Med 346*: 1087-1112.
9. Huang JH, Zager EL (2004) Mini-open carpal tunnel decompression. *Neurosurgery 54*: 394-400. [Link: https://goo.gl/y7MsjS](https://goo.gl/y7MsjS)
10. Ly-Pen D, Andreu J, de Blas G, Sánchez A, Millán I (2005) Surgical decompression versus local steroid injection in carpal tunnel syndrome - A one year, prospective, randomized, open, controlled clinical trial. *Arthritis Rheum 52*: 612-619. [Link: https://goo.gl/LvscfN](https://goo.gl/LvscfN)